

# Lung Ultrasound Predicts Interstitial Syndrome and Hemodynamic Profile in Parturients with Severe Preeclampsia

Laurent Zieleskiewicz, M.D., Claire Contargyris, M.D., Clément Brun, M.D., Maxime Touret, M.D., Armand Vellin, M.D., François Antonini, M.D., Laurent Muller, M.D., Ph.D., Florence Bretelle, M.D., Ph.D., Claude Martin, M.D., Marc Leone, M.D., Ph.D.

## ABSTRACT

**Background:** The role of lung ultrasound has never been evaluated in parturients with severe preeclampsia. The authors' first aim was to assess the ability of lung ultrasound to detect pulmonary edema in severe preeclampsia. The second aim was to highlight the relation between B-lines and increased left ventricular end-diastolic pressures.

**Methods:** This prospective cohort study was conducted in a level-3 maternity during a 12-month period. Twenty parturients with severe preeclampsia were consecutively enrolled. Both lung and cardiac ultrasound examinations were performed before ( $n = 20$ ) and after delivery ( $n = 20$ ). Each parturient with severe preeclampsia was compared with a control healthy parturient. Pulmonary edema was determined using two scores: the B-pattern and the Echo Comet Score. Left ventricular end-diastolic pressures were assessed by transthoracic echocardiography.

**Results:** Lung ultrasound detected interstitial edema in five parturients (25%) with severe preeclampsia. A B-pattern was associated to increased mitral valve early diastolic peak E (116 *vs.* 90 cm/s;  $P = 0.05$ ) and to increased E/E' ratio (9.9 *vs.* 6.6;  $P < 0.001$ ). An Echo Comet Score of greater than 25 predicted an increase in filling pressures (E/E' ratio  $>9.5$ ) with a sensitivity and specificity of 1.00 (95% CI, 0.69 to 1.00) and 0.82 (95% CI, 0.66 to 0.92), respectively.

**Conclusions:** In parturients with severe preeclampsia, lung ultrasound detects both pulmonary edema and increased left ventricular end-diastolic pressures. The finding of a B-pattern should restrict the use of fluid. However, these preliminary results are associations from a single sample. They need to be replicated in a larger, definitive study. (**ANESTHESIOLOGY 2014; 120:906-14**)

SEVERE preeclampsia (SP) is a multifocal syndrome usually recognized by new-onset hypertension and proteinuria in the second half of pregnancy, responsible each year for 60,000 maternal deaths worldwide.<sup>1</sup> The risk for serious complications such as pulmonary edema, cerebrovascular accidents, coagulopathy, and hemorrhage is 10- to 30-fold higher among parturients with SP.<sup>1</sup> Fluid resuscitation is a key determinant in the management of these parturients.<sup>2</sup> Hypovolemia exacerbates organ failure, whereas volume overload results in pulmonary edema.<sup>2</sup>

During pregnancy, cardiac output, heart rate, and stroke volume are increased, whereas vascular resistances are decreased.<sup>3</sup> The filling pressure remains unchanged.<sup>3</sup> Peripartum cardiomyopathy is defined as a dilated cardiomyopathy with altered systolic function.<sup>4</sup> It could explain pulmonary

### What We Already Know about This Topic

- Lung ultrasound has been used to detect pulmonary edema

### What This Article Tells Us That Is New

- Lung and cardiac ultrasound examinations were used to evaluate lung edema in parturients with severe preeclampsia and lung edema was found in 5 of 20 women
- The results from this preliminary study suggest hypotheses that need further investigation

edema during eclampsia. However, pulmonary edema may occur despite cardiomyopathy, especially after excessive fluid administration.<sup>5</sup> SP is associated to increased cardiac output

This article is featured in "This Month in Anesthesiology," page 1A. Supplemental Digital Content is available for this article. Direct URL citations appear in the printed text and are available in both the HTML and PDF versions of this article. Links to the digital files are provided in the HTML text of this article on the Journal's Web site ([www.anesthesiology.org](http://www.anesthesiology.org)). The first two authors contributed equally to this work.

Submitted for publication May 30, 2013. Accepted for publication November 8, 2013. From the Department of Anesthesiology and Critical Care Medicine, North Hospital, Aix Marseille University, Marseille, France (L.Z., C.C., C.B., M.T., A.V., F.A., C.M., and M.L.); Intensive Care Unit, Department of Anesthesiology and Critical Care Medicine, Nîmes University, Nîmes, France (L.M.); and North Hospital, Department of Obstetrics and Gynecology, Aix Marseille University, Marseille, France (F.B.).

Copyright © 2013, the American Society of Anesthesiologists, Inc. Lippincott Williams & Wilkins. Anesthesiology 2014; 120:906-14

and mild vasoconstriction.<sup>6</sup> The filling pressure is increased and the diastolic function is impaired.<sup>6</sup>

In this setting, the use of noninvasive hemodynamic monitoring is associated to reduced mortality.<sup>7</sup> National guidelines recommend the use of echocardiography to assess cardiac function in SP.<sup>8</sup> Lung ultrasound facilitates the detection of pulmonary edema<sup>9</sup> and the assessment of congestion in acute heart failure.<sup>10</sup> To our knowledge, except few cases,<sup>11,12</sup> its role in the parturients with SP has not been evaluated. Our first aim was to assess the ability of lung ultrasound to detect pulmonary edema in the parturients with SP. The second aim was to highlight the relation between B-lines and increased left ventricular end-diastolic pressures (LVEDPs) in parturients with SP.

## Materials and Methods

### Patient Population

A prospective cohort study was conducted in a single level-3 maternity center from December 2011 to December 2012. Due to the preliminary nature of the study, no attempts were made to adjust the associations for the large number of predictors, and to calculate the number of patients needed. As SP remains a rare disease, we decided to conduct the study during a 1-yr period. On the basis of a prior study,<sup>13</sup> we expected at least 15 patients with SP. After the study was approved by the Institutional Review Board of *Société de Réanimation de Langue Française* (CE SRLF 11–360, Paris, France) and an informed consent was obtained, 40 parturients including 20 with SP and 20 healthy parturients were consecutively enrolled during the study period.

The noninclusion criteria were as following: age below 18 yr, SP during the postpartum period, or refusal to participate to the study. In accordance with French guidelines,<sup>8</sup> SP was defined by one or more of the following clinical features: severe hypertension (systolic arterial pressure 160 mmHg and/or diastolic arterial pressure 110 mmHg on two measurements), renal dysfunction (oliguria <500 ml/day, serum creatinine >135  $\mu$ M, or proteinuria >5 g/day), acute pulmonary edema, epigastric pain, hemolysis, increased liver enzymes, low platelet count syndrome, visual disturbance, severe headache, polykinetic osteotendinous reflexes, eclampsia, platelet count less than 100 g/l, retroplacental hematoma, or fetal complications.

As soon as the parturient was admitted to delivery room, a certified operator performed both lung ultrasound and echocardiography.<sup>14</sup> This procedure was repeated after delivery. Hence, 40 ultrasonic examinations were performed in the 20 parturients with SP. In the cohort of 20 consecutive healthy parturients, lung ultrasound was performed before delivery according to our local guidelines.<sup>11</sup> Healthy parturients were defined as those of American Society of Anesthesiologists<sup>15</sup> physical status 1 to 2 without illness, vasoactive medication, multipare gestation, and uterine or placental abnormalities. This healthy cohort served as controls for the antepartum lung ultrasound of the parturients with SP.

At admission, we recorded the following clinical variables: age, gestational age, prior pregnancies, prior history of preeclampsia, body mass index, American Society of Anesthesiologists score, clinical signs of severity, maternal or fetal complications, type of delivery, and type of treatment. Baseline systolic arterial pressure and diastolic arterial pressure were obtained in supine position with a brachial cuff. Heart rate was recorded (Intellivue MP 70; Philips Medical System, Boeblingen, Germany). Pulmonary edema was a clinical diagnosis consisting on a worsening dyspnea and orthopnea along with signs of respiratory compromise (tachypnea, auditory crackles and rales, and hypoxemia). The following biological data were obtained: hemoglobin, platelets, plasma creatinine levels, urate, and urine protein level.

### Ultrasound Protocol

Ultrasound assessment was performed with parturient in the supine position using a FUJIFILM Sonosite M-turbo with a P21x 5-1 MHz cardiac transducer for echocardiography with two-dimensional, M-mode, color-flow, continuous, pulsed wave and tissue Doppler imaging. A C60x 5-2 MHz convex transducer was used for lung ultrasound (SonoSite, Bothell, WA). Parturients rested in supine position for at least 10 min before each measurement. Ultrasonography images were stored, converted to Digital Images and Communications in Medicine format, and analyzed off-line. The average values during three consecutive measures were considered for the analyses.

Alveolo-interstitial syndrome was assessed by the measurement of multiple B-lines or “comet tails.”<sup>16</sup> B-lines are defined as discrete laser-like vertical hyperechoic reverberation artifacts that arise from the pleural line extend to the bottom of the screen without fading, and move synchronously with lung sliding.<sup>17</sup> Multiple B-lines 7 mm apart are caused by thickened interlobular septa characterizing interstitial edema.<sup>17</sup> In contrast, B-lines 3 mm or less apart are caused by “ground-glass” areas characterizing alveolar edema.<sup>18</sup> Hyperechoic horizontal artifacts arising from pleural line are called A-lines.<sup>18</sup> Lung consolidation is defined as a subpleural echo-poor region or one with tissue-like echotexture. Pleural effusion is characterized as an anechoic space between parietal and visceral pleura and the presence of respiratory movement of the lung within the effusion (“sinusoid sign,” when using B-mode). Lung ultrasound examination was performed in less than 5 min and was conducted according to three specific methods: (1) the eight-region technique,<sup>18</sup> (2) the 28-rib interspace technique,<sup>19</sup> and (3) the 12-region technique.<sup>20</sup>

- The eight-region sonographic technique divided each hemithorax in four areas: two anterior areas and two lateral areas. The presence of three or more B-lines in a longitudinal plane between two ribs defined a positive region. Two or more positive regions per side suggested a B-pattern. A A-pattern was defined by less than two positive regions per side.
- The Echo Comet Score (ECS) was obtained by the 28-rib interspaces technique dividing the chest wall in

12 areas on the left side (from the second to the fourth intercostal space) and 16 (from the second to the fifth intercostal space) on the right anterior and lateral hemithorax. The sum of B-lines found on each scanning site (from 0 to 10) yields a semiquantifying score (over 280), denoting the extravascular fluid in the lung.

- The lung ultrasound score was obtained by scanning 12-rib interspaces with the probe longitudinally applied perpendicular to the wall. Each hemithorax was divided in six areas: two anterior areas, two lateral areas, and two posterior areas. The anterior chest wall (zone 1) was delineated from the parasternal to the anterior axillary line and was divided into upper and lower halves, from the clavicle to the third intercostal space and from the third to the diaphragm. The lateral area (zone 2) was delineated from the anterior to the posterior axillary line and was divided into upper and basal halves. The posterior area (zone 3) was considered as the zone beyond the posterior axillary line. The sum of B-lines found on each scanning site (0: absence; 1: B7 lines: multiple B-lines 7 mm apart; 2: B3 lines: multiple B 3 mm apart; 3: consolidation) yields a score from 0 to 36.

Left ventricular systolic function was visually estimated by “eyeball” ejection fraction of the left ventricular fractional area change from the apical four chambers view.<sup>21,22</sup> First, by using pulse wave Doppler, we recorded the early mitral flow peak velocity (E wave) and the late mitral flow peak velocity (A wave). Diastolic function was defined by the E/A ratio. Second, by using tissue Doppler imaging, we recorded the early diastolic mitral annulus displacement velocity (E' wave). Consequently, we calculated the “early mitral flow peak velocity to early diastolic mitral annulus displacement velocity” (E/E') ratio that correlates closely to LVEDP.<sup>10,23–27</sup> Preload dependency was defined as a variability of subaortic velocity–time integral blood flow ( $\Delta$ VTI) greater than 12% after passive leg raising test, whereas preload independency was defined by a  $\Delta$ VTI less than 12%, according to previous studies.<sup>13</sup>

### Statistical Analysis

All analyses were performed using R-Project 2.14 for GNU Linux Ubuntu, Canonical Group Limited (London, United Kingdom). For continuous and ordinal variables, data were expressed as median with interquartile range (25 to 75% quartile). For dichotomous variables, percentages were calculated. Comparisons were performed with the Mann–Whitney U test for continuous variables. Comparisons of percentages were performed with Fisher exact test. Discrimination of values was assessed with the receiver operating characteristic analysis. The correlation metric was tested using Pearson test.

The receiver operating characteristic curves and their area under curve were computed and displayed with the package pROC.<sup>28</sup> Sensitivity, specificity, positive predictive value, negative predictive value, positive likelihood ratio (LHR),

negative LHR, and rate of good classification were also computed.

Inter- and intraobserver variability was assessed on the ECS and the B-pattern score by two independent observers (C.C. and L.Z.) in 10 consecutive cases. Interobserver variability was calculated as the ratio of the difference between the values obtained by each observer (expressed as absolute value) divided by the average of the values. Intraobserver variability was calculated using two sets of measurement in one patient. Then, the ratio of the differences between the values obtained by the same observer (expressed as absolute value) divided by the average of the two values was calculated. Inter- and intraobserver reproducibility considered for E/E' ratio and baseline subaortic VTI was that calculated in a previous study.<sup>13</sup>

## Results

### Comparison of the Antepartum Pulmonary Pattern in Parturients with SP versus Healthy Parturients

Six of 20 parturients (30%) with SP had preterm births (<34 weeks). Three fetal deaths (15%) were reported. Eclampsia, hemorrhage, and acute pulmonary edema occurred in two (10%), two (10%), and four (20%) cases, respectively (table 1). The major independent risk factor identified for developing SP was the body mass index (29 *vs.* 22 kg/m<sup>2</sup>;  $P = 0.009$ ). As compared with healthy parturients, the parturients with SP had increased ECS (31 *vs.* 3;  $P = 0.02$ ), increased B-pattern (25 *vs.* 0%;  $P = 0.047$ ), increased lung ultrasound score (7 *vs.* 1;  $P < 0.001$ ), and increased rate of posterior basal lung consolidation (35 *vs.* 0%;  $P = 0.01$ ). With respect to diastolic function, the parturients with SP had increased E wave velocity (97 *vs.* 79 cm/s;  $P = 0.03$ ) and E/E' ratio (7.9 *vs.* 6.6;  $P = 0.04$ ). Four parturients (20%) with SP had E/E' ratio greater than 9.5, whereas no healthy parturient had this profile ( $P = 0.03$ ). Velocity–time index values were higher in the parturients with SP compared with the velocity–time index values in the healthy parturients (21 *vs.* 17 cm;  $P = 0.002$ ; table 2).

### Comparison between Lung Ultrasound Pattern and LVEDP

We conducted 40 ultrasound examinations during the study period in the 20 parturients with SP (20 antepartum and 20 postpartum). An A-pattern was found in 28 examinations (70%) and was associated to a E/E' ratio less than 9.5 in 27 cases (96%). The 12 examinations (30%) showing a B-pattern were associated to reduced lateral E' wave velocity (10.4 *vs.* 12.6 cm/s;  $P = 0.03$ ), higher E (116 *vs.* 90 cm/s;  $P = 0.05$ ), and higher E/E' ratio (9.9 *vs.* 6.6;  $P < 0.001$ ; table 3). We found a linear correlation between E/E' ratio and the number of B-lines quantified by the ECS ( $r = 0.66$ ;  $P < 0.001$ ). Similar relation was found between E and the ECS ( $r = 0.36$ ;  $P = 0.018$ ). Increased LVEDP (E/E' ratio >9.5) was associated to increased ECS (95 *vs.* 20;  $P < 0.001$ ; fig. 1).

**Table 1.** Features of Parturients with Severe Preeclampsia and Healthy Parturients

	Parturients with Preeclampsia (n = 20)	Healthy Parturients (n = 20)	P Value
<b>General epidemiology</b>			
Age, yr, median (IQR)	31 [26–38]	30 [26–34]	0.5
Nulliparous, n (%)	9 (45)	7 (35)	0.75
Previous history of SP, n (%)	1 (5)	1 (5)	0.47
Gestation, weeks, median (IQR)	34 [31–35]	37 [36–39]	0.001
BMI, kg/m <sup>2</sup> , median (IQR)	29 [24–34]	22 [21–25]	0.009
ASA 1, n (%)	13 (65)	17 (85)	0.27
<b>Clinical features, median (IQR)</b>			
Heart rate, beats/min	93 [85–106]	79 [71–85]	0.001
Systolic arterial pressure, mmHg	157 [146–167]	110 [100–120]	0.001
Diastolic arterial pressure, mmHg	92 [90–101]	70 [62–71]	0.001
SpO <sub>2</sub> , %	99 [97–100]	99 [98–100]	0.98
<b>Biology, median (IQR)</b>			
Plasma creatinine, μM	59 [53–75]	47 [47–49]	0.03
Total protein level, g/l	59 [54–61]	68 [61–76]	0.1
ALP, U/l	20 [18–29]	16 [13–26.8]	0.31
Platelet count, g/l	235 [199–304]	244 [222–299]	0.55
Hemoglobin, g/dl	12 [11–13]	12 [11–12]	0.98
Urate, mM	365 [345–423]	226 [169–269]	0.005
Urea, mM	4.3 [3.2–5.8]	2.8 [2.5–2.9]	0.006
<b>Maternal complications, n (%)</b>			
Maternal hemorrhage	2 (10)	0 (0)	0.47
Eclampsia	2 (10)	0 (0)	0.47
Clinical acute pulmonary congestion	4 (20)	0 (0)	0.001
<b>Fetal complications, n (%)</b>			
Fetal mortality	3 (15)	0 (0)	0.23
Medical abruption	2 (10)	0 (0)	0.47
Growth restriction	5 (25)	3 (15)	0.69
Nonreactive cardiotocogram	8 (40)	6 (30)	0.74
Preterm birth <34 weeks	6 (30)	1 (5)	0.09
<b>Type of delivery, n (%)</b>			
Cesarean section	13 (65)	7 (35)	0.11
General anesthesia	3 (15)	0 (0)	0.23

ALP = alkaline phosphatase; ASA 1 = American Society of Anesthesiologists physical status 1; BMI = body mass index; IQR = interquartile range; SP = severe preeclampsia; SpO<sub>2</sub> = oxygen saturation.

The prediction of E/E' ratio of greater than 9.5 by ECS had sensitivity of 1.00 (95% CI, 0.70 to 0.98) and specificity of 0.82 (95% CI, 0.66 to 0.92), respectively. The test showed an area under curve of 0.90 (95% CI, 0.81 to 0.99) (fig. 2A). We completed the analysis by representing positive and negative LHRs based on evaluation of inconclusive limits. Figure 2B shows inconclusive limits of lung ultrasound score, defined as sensitivity and specificity above 90%.<sup>29,30</sup> The best cutoff value of ECS was 25. This threshold was associated to a positive predictive value of 0.57 (95% CI, 0.28 to 0.82), negative predictive value of 1.00 (95% CI, 0.87 to 1.00), positive LHR of 5.33, negative LHR at 0.0, and Youden index at 0.81. Different threshold values were tested to assess the performance of ECS (see table, Supplemental Digital Content 1, <http://links.lww.com/ALN/B22>).

The ECS was correlated with  $\Delta$ VTI values ( $r = 0.54$ ;  $P = 0.001$ ). A B-pattern was associated to reduced  $\Delta$ VTI ratios during passive leg rising (2.3 vs. 11.4%;  $P = 0.005$ ) (table 3). The need for oxygen support was higher in the

B-pattern group compared with the need for oxygen support in the A-pattern group (67 vs. 18%;  $P = 0.002$ ).

### Intra- and Interobserver Variability

The intra- and interobserver variability was of 4 and 5% for the ECS, respectively, whereas the reproducibility for E/E' ratios was of 4.6% (2.6 to 4.9%) and 8.0% (6.7 to 15%).

### Discussion

The striking finding of this preliminary study was that lung ultrasound detected a B-pattern in 25% of parturients with SP. The incidence was higher than that of clinical edema reported in the literature.<sup>31,32</sup> No B-line was observed in healthy parturients, whereas a B-pattern was found in asymptomatic parturients with SP. Interstitial edema is a clinically silent step preceding alveolar edema.<sup>33</sup> As showed in a previous study,<sup>34</sup> ultrasound lung comets detect extravascular lung water accumulation early in the course of lung injury, whereas the ratio of arterial oxygen pressure to



**Table 2.** Lung Ultrasound and Echocardiography in Parturients with Severe Preeclampsia and Healthy Parturients

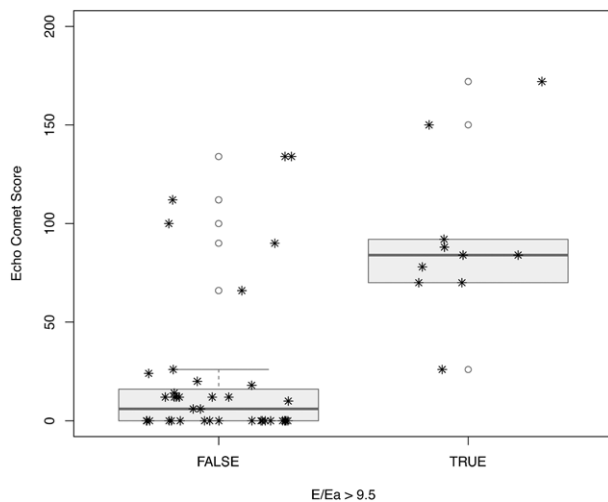
	Parturients with Preeclampsia (n = 20)	Healthy Parturients (n = 20)	P Value
<b>Lung ultrasound</b>			
Echo Comet Score, median (IQR)	31 [0–42]	3 [0–1.2]	0.02
B-Pattern, n (%)	5 (25)	0 (0)	0.047
Lung ultrasound score, median (IQR)	7 [1–10]	1 [0–1]	0.001
Condensations, n (%)	7 (35)	0 (0)	0.01
Pleural effusion, n (%)	3 (15)	0 (0)	0.23
<b>Echocardiography</b>			
<b>Systolic function</b>			
Eye-ball ejection fraction, %, median (IQR)	65 [60–65]	65 [65–65]	0.60
<b>Diastolic function</b>			
DT ms, median (IQR)	205 [182–214]	208 [194–210]	0.58
E velocity cm/s, median (IQR)	97 [80–110]	79 [70–85]	0.03
A velocity cm/s, median (IQR)	80 [65–92]	60 [47–71]	0.003
E/A ratio, median (IQR)	1.1 [1.0–1.5]	1.4 [1.2–1.6]	0.16
E/A ratio <1, n (%)	6 (30)	2 (10)	0.24
E' velocity, cm/s, median (IQR)	11 [10–15]	13 [11–15]	0.37
E' velocity <10 cm/s, n (%)	4 (20)	2 (10)	0.66
E/E' ratio	7.9 [5.9–8.9]	6.6 [5.8–7.0]	0.04
E/E' ratio >9.5, n (%)	4 (20)	0 (0)	0.03
<b>Preload dependency</b>			
VTI cm, median (IQR)	21 [19–23]	17 [16–19]	0.002
ΔVTI %, median (IQR)	9.9 [2.0–19]	8.0 [4.4–12]	0.58
Systolic exclusion, n (%)	3 (15)	0 (0)	0.23

A = late diastolic velocities recorded by pulse wave Doppler; DT = deceleration time; E = early diastolic velocities recorded by pulse wave Doppler; E' = early diastolic wave velocity recorded by tissue Doppler imaging; IQR = interquartile range; VTI = velocity–time integral; ΔVTI = variability of velocity–time integral after passive leg raising test.

**Table 3.** Association between Lung Ultrasound and Echocardiography Data

	B-Pattern (n = 12)	A-Pattern (n = 28)	P Value
<b>Clinical features</b>			
Heart rate, beats/min, median (IQR)	94 [85–104]	90 [82–107]	0.99
Systolic arterial pressure, mmHg, median (IQR)	146 [140–160]	150 [144–163]	0.57
Diastolic arterial pressure, mmHg, median (IQR)	87 [72–90]	91 [88–97]	0.68
Spo <sub>2</sub> , %, median (IQR)	97 [94–99]	98 [97–100]	0.02
Diuresis, ml/h, median (IQR)	95 [60–200]	70 [50–120]	0.07
Clinical acute pulmonary congestion, n (%)	10 (83)	0 (0)	<0.001
Oxygenotherapy, n (%)	8 (67)	5 (18)	0.002
Fluid loading, n (%)	7 (58)	17 (61)	0.88
Diuretics, n (%)	3 (25)	1 (3.6)	0.04
<b>Echocardiography</b>			
DT ms, median (IQR)	179 [144–217]	205 [180–215]	0.46
E velocity cm/s, median (IQR)	116 [90–129]	90 [74–102]	0.05
A velocity cm/s, median (IQR)	69 [59–89]	75 [64–96]	0.33
E/A ratio, median (IQR)	1.6 [1.1–2.0]	1.1 [0.9–1.4]	0.03
E' velocity cm/s, median (IQR)	10.4 [9.0–12.6]	12.6 [11.0–15.0]	0.03
E/E' ratio, median (IQR)	9.9 [8.3–12.4]	6.6 [5.5–8.0]	<0.001
E/E' >9.5, n (%)	7 (58)	0 (0)	<0.001
VTI cm, median (IQR)	23 [20–26]	19 [18–23]	0.02
ΔVTI %, median (IQR)	2.3 [0.0–7.5]	11 [5.3–19]	0.005
ΔVTI <12%, n (%)	10 (83)	18 (52)	0.07

A = late diastolic velocities recorded by pulse wave Doppler; DT = deceleration time; E = early diastolic velocities recorded by pulse wave Doppler; E' = early diastolic wave velocity recorded by tissue Doppler imaging; IQR = interquartile range; Spo<sub>2</sub> = oxygen saturation; VTI = velocity–time integral; ΔVTI = variability of velocity–time integral after passive leg raising test.



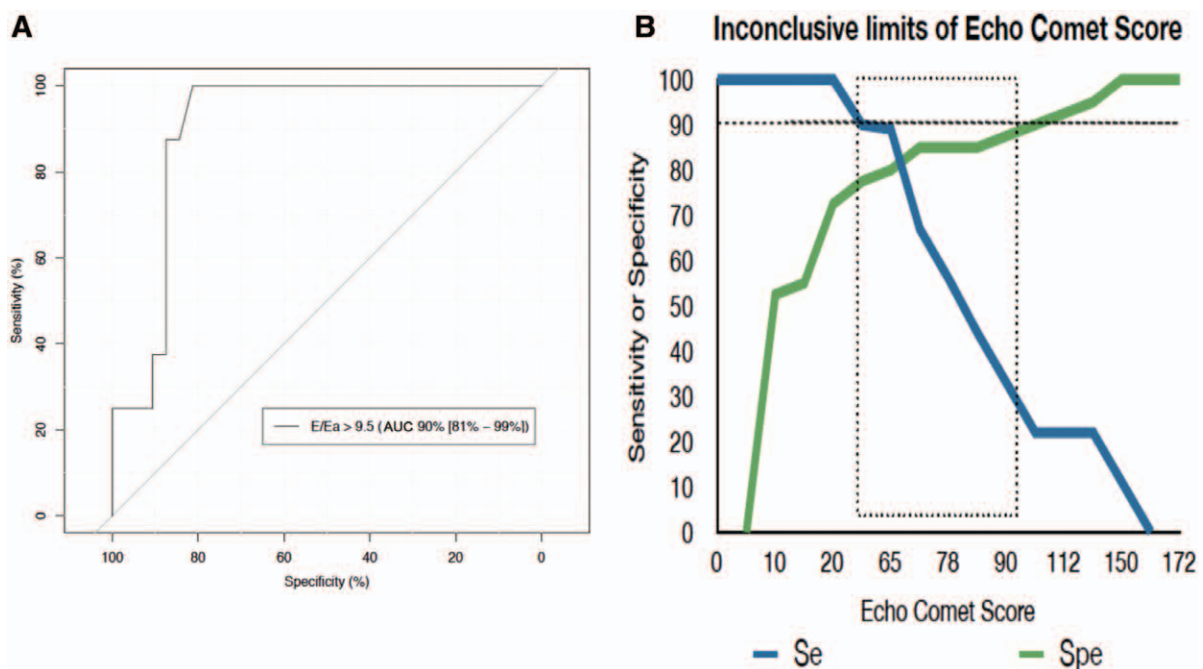
**Fig. 1.** Echo Comet Score (ECS) in parturients with severe preeclampsia and increased filling pressures ( $E/E'$  ratio  $>9.5$ ) compared with parturients with severe preeclampsia and low filling pressures ( $E/E'$  ratio  $<9.5$ ). ECS was increased (95 vs. 20;  $P < 0.001$ ) in the group with increased left ventricular end-diastolic pressure. There was a linear correlation between  $E/E'$  ratio values and the number of B-lines quantified by the ECS ( $r = 0.66$ ;  $P < 0.001$ ).  $E/E' =$  early mitral flow peak velocity to early diastolic mitral annulus displacement velocity ratio.

inspired oxygen fraction is not impaired. In our study, the detection of B-lines was associated to a slight deterioration of arterial oxygenation easily treated by exogenous oxygen.

Thus, lung ultrasound detects lung edema early before severe deterioration of arterial oxygenation.<sup>34</sup>

However, sonographic B-lines have been related to radiographic alveolar-interstitial syndrome,<sup>35,36</sup> lung water score on computed tomography scan,<sup>37</sup> extra vascular lung water,<sup>38</sup> and diastolic dysfunction.<sup>39</sup> In nonpregnant patients, the sensitivity and specificity of lung ultrasound to detect pulmonary edema are 98 and 88%, respectively.<sup>16</sup> Guidelines stated that “because of their low sensitivity and specificity, the chest X-ray should not form the primary basis for determining the specific cardiac abnormality responsible for the development of heart failure.”<sup>40</sup> The International Evidence-Based Recommendations for Point-of-Care lung ultrasound confirm that lung ultrasound is superior to chest radiograph for diagnosing interstitial syndrome.<sup>18</sup>

In our study, we noted lung consolidations in 35% of parturients with SP. Due to the strategy of radiation exposure limitation, chest radiographs and lung computed tomography were not available. Further studies using lung ultrasound could identify the prevalence, physiopathology, and prognostic of these consolidations in parturients with SP. Ultrasonographic signs such as lung pulse (absent lung sliding with the perception of heart activity at the pleural line), dynamic air bronchogram, or intraconsolidation shunt (persistent regional blood flow) can facilitate the discrimination between atelectasis (obstructive consolidation) and inflammatory consolidation.<sup>41–44</sup>



**Fig. 2.** Echo Comet Score (ECS). (A) Receiver operating characteristics curve. ECS  $>25$  predicted an increase in filling pressures ( $E/E'$  ratio  $>9.5$ ) with a sensitivity and specificity of 1.00 (95% CI, 0.69–0.98) and 0.82 (95% CI, 0.66–0.92), positive predictive value of 0.59 (95% CI, 0.33 to 0.82), negative predictive value of 1.00 (95% CI, 0.89 to 0.98), positive likelihood ratio of 5.57, negative likelihood ratio of 0.01, and rate of correct classification of 0.82. The area under the receiver operating characteristics analysis curve (AUC) for ECS = 0.90 (95% CI, 0.81 to 0.99) was used to evaluate the relationship between  $E/E'$  ratio and the number of B-lines. (B) Inconclusive limits of lung ultrasound score, defined as sensitivity and specificity above 90%.  $E/E' =$  early mitral flow peak velocity to early diastolic mitral annulus displacement velocity ratio.

With respect to our preliminary findings, an ECS greater than 90 and a B-pattern predicted E/E' ratios greater than 9.5, that is, increased LVEDP. We used lateral mitral annulus tissue Doppler index because this signal is less affected by loading conditions.<sup>45–47</sup> In addition, recent studies showed that lateral tissue Doppler signals had the best correlations with LVEDP in the patients with normal ejection fractions.<sup>23,48,49</sup> In our study, the E/E' ratio was lower than that commonly associated with increased LVEDP in adults with normal ejection fraction.<sup>23</sup> Nevertheless, previous studies suggested that, during pregnancy, the threshold values may be lower than 12.<sup>2,50,51</sup> In previous studies, the pulmonary A-pattern is associated to a low LVEDP. This was related to the accuracy of lung ultrasound to detect early every interstitial edema.<sup>33</sup> In critically ill patients, a B-pattern cannot differentiate hydrostatic edema and acute lung injury.<sup>33</sup> In the parturients with SP, a B-pattern is associated to hydrostatic edema (*i.e.*, increased LVEDP).

In presence of a B-pattern, we found an increased VTI. As VTI directly reflects stroke volume, our results suggest that B-pattern is associated to increased cardiac outputs. This can be due to an excess of fluid administration.<sup>52</sup> Thus, fluid should not be administered to the parturients with SP developing a B-pattern.<sup>53</sup> In addition, 83% of B-patterns are associated with a  $\Delta$ VTI less than 12% during passive leg rising, which predicts preload independency.<sup>13</sup> Due to the limited power of our study, further investigations should confirm the correlation between B-pattern and preload independency in parturients with SP. One can suggest that a B-pattern is related to peripartum cardiomyopathy. The 2008 ESC guidelines pointed out that peripartum cardiomyopathy is a dilated cardiomyopathy characterized by an unexplained left ventricular systolic dysfunction.<sup>4</sup> In our study, as LVEF was evaluated at 65%, a B-pattern during SP probably reflects an excess of fluid administration.

The intra- and interobserver variability is small, respectively, of 4 and 5% for the ECS,<sup>35,36</sup> whereas the reproducibility for E/E' ratios is of 4.6% (2.6 to 4.9%) and 8.0% (6.7 to 15 %), respectively.<sup>13</sup> The assessment of B-pattern is reproducible without any variability. Lung ultrasound does not require specific devices.<sup>54</sup> Of interest, during pregnancy, lung ultrasound reduces radiation exposure.<sup>55</sup> As compared with echocardiography, the determination of LVEDP is easier with lung ultrasound.<sup>56</sup> The learning curve for B-line assessment is shorter than 6 weeks.<sup>57</sup> For assessing an interstitial syndrome, lung ultrasound should probably be considered as a basic technique.<sup>58–60</sup>

We have to acknowledge several limitations. We included only 20 parturients with SP during the study period. Actually, SP is a rare disease, making it difficult the implementation of randomized clinical trials. The large number of unadjusted inferences is a weakness of our study. They are presented as exact *P* value without regard to type-I error. Within this limitation, our preliminary findings suggest that lung ultrasound is an interesting tool for real-time hemodynamic assessment. The feasibility of the procedure was of

100%. However, lung ultrasound has some intrinsic limitations. Physical features, such as obesity, can hamper the ultrasound examination.<sup>61</sup> Furthermore, potential adverse ultrasound biological effects have been recently described.<sup>62</sup> Despite this finding, ultrasound remain widely used during pregnancy. In addition, operators were not blinded although they were not involved in the management of parturients.

The choice of E/E' ratio to evaluate LVEDP is a matter of debate. In patients with normal systolic function, the use of E/E' ratio is recommended to evaluate LVEDP.<sup>23</sup> Adding pulmonary venous flow to E/E' ratio may facilitate LVEDP assessment. However, the assessment of pulmonary venous flow using a transthoracic approach is difficult.<sup>63,64</sup> The transesophageal view provides a fine evaluation of pulmonary venous flow,<sup>65,66</sup> but its use is limited in conscious parturient. In contrast, the E/E' ratio is easily performed using a transthoracic approach.<sup>67–70</sup>

In conclusion, in this single sample of parturients with SP, lung ultrasound is an easy tool to detect pulmonary edema and increased LVEDP. This implies that the use of intravenous fluids in parturients with SP developing a B-pattern should be discouraged. Due to the limitations of this preliminary study, further large investigations are needed to confirm the interest of implementation of this noninvasive monitoring technique in the management of parturients with SP.

## Acknowledgments

Support was provided solely from institutional and/or departmental sources.

## Competing Interests

The authors declare no competing interests.

## Correspondence

Address correspondence to Dr. Leone: Service d'anesthésie et réanimation, Hôpital Nord, Marseille, 13915 Marseille cedex 20, France. marc.leone@ap-hm.fr. This article may be accessed for personal use at no charge through the Journal Web site, [www.anesthesiology.org](http://www.anesthesiology.org).

## References

1. Hutcheon JA, Lisonkova S, Joseph KS: Epidemiology of pre-eclampsia and the other hypertensive disorders of pregnancy. *Best Pract Res Clin Obstet Gynaecol* 2011; 25:391–3
2. Dennis AT, Solnordal CB: Acute pulmonary oedema in pregnant women. *Anaesthesia* 2012; 67:646–59
3. Bamfo JE, Kametas NA, Nicolaides KH, Chambers JB: Maternal left ventricular diastolic and systolic long-axis function during normal pregnancy. *Eur J Echocardiogr* 2007; 8:360–8
4. Dickstein K, Cohen-Solal A, Filippatos G, McMurray JJ, Ponikowski P, Poole-Wilson PA, Strömberg A, van Veldhuisen DJ, Atar D, Hoes AW, Keren A, Mebazaa A, Nieminen M, Priori SG, Swedberg K; ESC Committee for Practice Guidelines (CPG): ESC guidelines for the diagnosis and treatment of acute and chronic heart failure 2008: The Task Force for the diagnosis and treatment of acute and chronic heart failure 2008 of the European Society of Cardiology. Developed in collaboration with the Heart Failure Association of the ESC

- (HFA) and endorsed by the European Society of Intensive Care Medicine (ESICM). *Eur J Heart Fail* 2008; 10:933–89
5. Sciscione AC, Ivester T, Largoza M, Manley J, Shlossman P, Colmorgen GH: Acute pulmonary edema in pregnancy. *Obstet Gynecol* 2003; 101:511–5
  6. Dennis AT, Castro J, Carr C, Simmons S, Permezel M, Royse C: Haemodynamics in women with untreated pre-eclampsia. *Anaesthesia* 2012; 67:1105–18
  7. Young P, Johanson R: Haemodynamic, invasive and echocardiographic monitoring in the hypertensive parturient. *Best Pract Res Clin Obstet Gynaecol* 2001; 15:605–22
  8. Société française d'anesthésie et de réanimation (Sfar); Collège national des gynécologues et obstétriciens français (CNGOF); Société française de médecine périnatale (SFMP); Société française de néonatalogie (SFNN): Multidisciplinary management of severe pre-eclampsia. Experts' guidelines 2008. *Ann Fr Anesth Reanim* 2009; 28:275–81
  9. Volpicelli G, Cardinale L, Mussa A, Valeria C: Diagnosis of cardiogenic pulmonary edema by sonography limited to the anterior lung. *Chest* 2009; 135:883–4
  10. Gheorghiadu M, Follath F, Ponikowski P, Barsuk JH, Blair JE, Cleland JG, Dickstein K, Drazner MH, Fonarow GC, Jaarsma T, Jondeau G, Sendon JL, Mebazaa A, Metra M, Nieminen M, Pang PS, Seferovic P, Stevenson LW, van Veldhuisen DJ, Zannad F, Anker SD, Rhodes A, McMurray JJ, Filippatos G; European Society of Cardiology; European Society of Intensive Care Medicine: Assessing and grading congestion in acute heart failure: A scientific statement from the acute heart failure committee of the heart failure association of the European Society of Cardiology and endorsed by the European Society of Intensive Care Medicine. *Eur J Heart Fail* 2010; 12:423–33
  11. Zieleskiewicz L, Lagier D, Contargyris C, Bourgoin A, Gavage L, Martin C, Leone M: Lung ultrasound-guided management of acute breathlessness during pregnancy. *Anaesthesia* 2013; 68:97–101
  12. Zieleskiewicz L, Pierrou C, Ragonnet B, Turret M, Chau C, Craighero F, Contargyris C, Martin C, Leone M: [Role of whole-body ultrasound in severe pre-eclampsia and post-partum hemorrhage]. *Can J Anaesth* 2013; 60:796–2
  13. Brun C, Zieleskiewicz L, Textoris J, Muller L, Bellefleur JP, Antonini F, Tourret M, Ortega D, Vellin A, Lefrant JY, Boubli L, Bretelle F, Martin C, Leone M: Prediction of fluid responsiveness in severe preeclamptic patients with oliguria. *Intensive Care Med* 2013; 39:593–600
  14. Mayo PH, Beaulieu Y, Doelken P, Feller-Kopman D, Harrod C, Kaplan A, Oropello J, Vieillard-Baron A, Axler O, Lichtenstein D, Maury E, Slama M, Vignon P: American College of Chest Physicians/La Société de Réanimation de Langue Française statement on competence in critical care ultrasonography. *Chest* 2009; 135:1050–60
  15. Dripps RD, Lamont A, Eckenhoof JE: The role of anesthesia in surgical mortality. *JAMA* 1961; 178:261–6
  16. Lichtenstein D, Mézière G, Biderman P, Gepner A, Barré O: The comet-tail artifact. An ultrasound sign of alveolar-interstitial syndrome. *Am J Respir Crit Care Med* 1997; 156:1640–6
  17. Lichtenstein D: Should lung ultrasonography be more widely used in the assessment of acute respiratory disease? *Expert Rev Respir Med* 2010; 4:533–8
  18. Volpicelli G, Elbarbary M, Blaivas M, Lichtenstein DA, Mathis G, Kirkpatrick AW, Melniker L, Gargani L, Noble VE, Via G, Dean A, Tsung JW, Soldati G, Copetti G, Bouhemad B, Reissig A, Agricola E, Rouby JJ, Arbelot C, Liteplo A, Sargsyan A, Silva F, Hoppmann R, Breikreutz R, Seibel A, Neri L, Storti E, Petrovic T; International Liaison Committee on Lung Ultrasound (ILC-LUS) for International Consensus Conference on Lung Ultrasound (ICC-LUS): International evidence-based recommendations for point-of-care lung ultrasound. *Intensive Care Med* 2012; 38:577–91
  19. Agricola E, Picano E, Oppizzi M, Pisani M, Meris A, Fragasso G, Margonato A: Assessment of stress-induced pulmonary interstitial edema by chest ultrasound during exercise echocardiography and its correlation with left ventricular function. *J Am Soc Echocardiogr* 2006; 19:457–63
  20. Bouhemad B, Zhang M, Lu Q, Rouby JJ: Clinical review: Bedside lung ultrasound in critical care practice. *Crit Care* 2007; 11:205
  21. Bergenzaun L, Gudmundsson P, Öhlin H, Düring J, Ersson A, Ihrman L, Willenheimer R, Chew MS: Assessing left ventricular systolic function in shock: Evaluation of echocardiographic parameters in intensive care. *Crit Care* 2011; 15:R200
  22. Vieillard-Baron A, Charron C, Chergui K, Peyrouset O, Jardin F: Bedside echocardiographic evaluation of hemodynamics in sepsis: Is a qualitative evaluation sufficient? *Intensive Care Med* 2006; 32:1547–52
  23. Nagueh SF, Appleton CP, Gillebert TC, Marino PN, Oh JK, Smiseth OA, Waggoner AD, Flachskampf FA, Pellikka PA, Evangelista A: Recommendations for the evaluation of left ventricular diastolic function by echocardiography. *Eur J Echocardiogr* 2009; 10:165–93
  24. Dokainish H, Nguyen J, Sengupta R, Pillai M, Alam M, Bobek J, Lakkis N: New, simple echocardiographic indexes for the estimation of filling pressure in patients with cardiac disease and preserved left ventricular ejection fraction. *Echocardiography* 2010; 27:946–53
  25. Vanoverschelde JL, Gerber BL, D'Hondt AM, De Kock M, Dion R, Wijns W, Melin JA: Preoperative selection of patients with severely impaired left ventricular function for coronary revascularization. Role of low-dose dobutamine echocardiography and exercise-redistribution-reinjection thallium SPECT. *Circulation* 1995; 92(9 suppl):II37–44
  26. Bouhemad B, Nicolas-Robin A, Benois A, Lemaire S, Goarin JP, Rouby JJ: Echocardiographic Doppler assessment of pulmonary capillary wedge pressure in surgical patients with postoperative circulatory shock and acute lung injury. *ANESTHESIOLOGY* 2003; 98:1091–100
  27. Combes A, Arnoult F, Trouillet JL: Tissue Doppler imaging estimation of pulmonary artery occlusion pressure in ICU patients. *Intensive Care Med* 2004; 30:75–81
  28. Robin X, Turck N, Hainard A, Tiberti N, Lisacek F, Sanchez JC, Müller M: pROC: An open-source package for R and S+ to analyze and compare ROC curves. *BMC Bioinformatics* 2011; 12:77
  29. Ray P, Le Manach Y, Riou B, Houle TT: Statistical evaluation of a biomarker. *ANESTHESIOLOGY* 2010; 112:1023–40
  30. Soummer A, Perbet S, Brisson H, Arbelot C, Constantin JM, Lu Q, Rouby JJ: Lung Ultrasound Study Group: Ultrasound assessment of lung aeration loss during a successful weaning trial predicts postextubation distress\*. *Crit Care Med* 2012; 40:2064–72
  31. Sibai BM, Mabie BC, Harvey CJ, Gonzalez AR: Pulmonary edema in severe preeclampsia-eclampsia: Analysis of thirty-seven consecutive cases. *Am J Obstet Gynecol* 1987; 156:1174–9
  32. Thornton CE, von Dadelszen P, Makris A, Tooher JM, Ogle RF, Hennessy A: Acute pulmonary oedema as a complication of hypertension during pregnancy. *Hypertens Pregnancy* 2011; 30:169–79
  33. Lichtenstein DA, Mézière GA, Lagoueyte JF, Biderman P, Goldstein I, Gepner A: A-lines and B-lines: Lung ultrasound as a bedside tool for predicting pulmonary artery occlusion pressure in the critically ill. *Chest* 2009; 136:1014–20
  34. Gargani L, Lionetti V, Di Cristofano C, Bevilacqua G, Recchia FA, Picano E: Early detection of acute lung injury uncoupled to hypoxemia in pigs using ultrasound lung comets. *Crit Care Med* 2007; 35:2769–74
  35. Lichtenstein D, Goldstein I, Mourgeon E, Cluzel P, Grenier P, Rouby JJ: Comparative diagnostic performances of auscultation, chest radiography, and lung ultrasonography in acute respiratory distress syndrome. *ANESTHESIOLOGY* 2004; 100:9–15



36. Jambrik Z, Monti S, Coppola V, Agricola E, Mottola G, Miniati M, Picano E: Usefulness of ultrasound lung comets as a non-radiologic sign of extravascular lung water. *Am J Cardiol* 2004; 93:1265–70
37. Baldi G, Gargani L, Abramo A, D'Errico L, Caramella D, Picano E, Giunta F, Forfori F: Lung water assessment by lung ultrasonography in intensive care: A pilot study. *Intensive Care Med* 2013; 39:74–84
38. Agricola E, Bove T, Oppizzi M, Marino G, Zangrillo A, Margonato A, Picano E: "Ultrasound comet-tail images": A marker of pulmonary edema: A comparative study with wedge pressure and extravascular lung water. *Chest* 2005; 127:1690–5
39. Frassi F, Gargani L, Gligorova S, Ciampi Q, Mottola G, Picano E: Clinical and echocardiographic determinants of ultrasound lung comets. *Eur J Echocardiogr* 2007; 8:474–9
40. Jessup M, Abraham WT, Casey DE, Feldman AM, Francis GS, Ganiats TG, Konstam MA, Mancini DM, Rahko PS, Silver MA, Stevenson LW, Yancy CW: 2009 focused update: ACCF/AHA Guidelines for the Diagnosis and Management of Heart Failure in Adults: A report of the American College of Cardiology Foundation/American Heart Association Task Force on Practice Guidelines: Developed in collaboration with the International Society for Heart and Lung Transplantation. *Circulation* 2009; 119:1977–16
41. Lichtenstein DA, Lascols N, Prin S, Mezière G: The "lung pulse": An early ultrasound sign of complete atelectasis. *Intensive Care Med* 2003; 29:2187–92
42. Lichtenstein D, Mezière G, Seitz J: The dynamic air bronchogram. A lung ultrasound sign of alveolar consolidation ruling out atelectasis. *Chest* 2009; 135:1421–5
43. Murayama S, Onitsuka H, Murakami J, Torii Y, Masuda K, Nishihara K: "CT angiogram sign" in obstructive pneumonitis and pneumonia. *J Comput Assist Tomogr* 1993; 17:609–12
44. Yuan A, Yang PC, Lee L, Wu HD, Kuo SH, Luh KT, Chen WJ, Lin FY: Reactive pulmonary artery vasoconstriction in pulmonary consolidation evaluated by color Doppler ultrasonography. *Ultrasound Med Biol* 2000; 26:49–56
45. Quintard H, Muller L, Philip I, Lena P, Ichai C: Influence of acute preload changes on mitral annulus velocity measured by tissue Doppler echocardiography in critically ill patients. *J Clin Ultrasound* 2012; 40:419–23
46. Batterham A, Shave R, Oxborough D, Whyte G, George K: Longitudinal plane colour tissue-Doppler myocardial velocities and their association with left ventricular length, volume, and mass in humans. *Eur J Echocardiogr* 2008; 9:542–6
47. Bamfo JE, Kametas NA, Nicolaides KH, Chambers JB: Reference ranges for tissue Doppler measures of maternal systolic and diastolic left ventricular function. *Ultrasound Obstet Gynecol* 2007; 29:414–20
48. Galderisi M, Henein MY, D'hooge J, Sicari R, Badano LP, Zamorano JL, Roelandt JR: European Association of Echocardiography: Recommendations of the European Association of Echocardiography: How to use echo-Doppler in clinical trials: Different modalities for different purposes. *Eur J Echocardiogr* 2011; 12:339–53
49. Kasner M, Westermann D, Steendijk P, Gaub R, Wilkenshoff U, Weitmann K, Hoffmann W, Poller W, Schultheiss HP, Pauschinger M, Tschöpe C: Utility of Doppler echocardiography and tissue Doppler imaging in the estimation of diastolic function in heart failure with normal ejection fraction: A comparative Doppler-conductance catheterization study. *Circulation* 2007; 116:637–47
50. Melchiorre K, Sutherland GR, Baltabaeva A, Liberati M, Thilaganathan B: Maternal cardiac dysfunction and remodeling in women with preeclampsia at term. *Hypertension* 2011; 57:85–93
51. Rafik Hamad R, Larsson A, Pernow J, Bremme K, Eriksson MJ: Assessment of left ventricular structure and function in preeclampsia by echocardiography and cardiovascular biomarkers. *J Hypertens* 2009; 27:2257–64
52. Thornton CE, von Dadelszen P, Makris A, Tooher JM, Ogle RF, Hennessy A: Acute pulmonary oedema as a complication of hypertension during pregnancy. *Hypertens Pregnancy* 2011; 30:169–79
53. Lichtenstein DA: Fluid administration limited by lung sonography: The place of lung ultrasound in assessment of acute circulatory failure (the FALLS-protocol). *Expert Rev Respir Med* 2012; 6:155–62
54. Arbelot C, Ferrari F, Bouhemad B, Rouby JJ: Lung ultrasound in acute respiratory distress syndrome and acute lung injury. *Curr Opin Crit Care* 2008; 14:70–4
55. Agricola E, Arbelot C, Blaivas M, Bouhemad B, Copetti R, Dean A, Dulchavsky S, Elbarbary M, Gargani L, Hoppmann R, Kirkpatrick AW, Lichtenstein D, Liteplo A, Mathis G, Melniker L, Neri L, Noble VE, Petrovic T, Reissig A, Rouby JJ, Seibel A, Soldati G, Storti E, Tsung JW, Via G, Volpicelli G: Ultrasound performs better than radiographs. *Thorax* 2011; 66:828–9; author reply 829
56. Lichtenstein D, Karakitsos D: Integrating lung ultrasound in the hemodynamic evaluation of acute circulatory failure (the fluid administration limited by lung sonography protocol). *J Crit Care* 2012; 27:533.e11–9
57. Noble VE, Lamhaut L, Capp R, Bosson N, Liteplo A, Marx JS, Carli P: Evaluation of a thoracic ultrasound training module for the detection of pneumothorax and pulmonary edema by prehospital physician care providers. *BMC Med Educ* 2009; 9:3
58. Lichtenstein DA, Mezière GA: Relevance of lung ultrasound in the diagnosis of acute respiratory failure: The BLUE protocol. *Chest* 2008; 134:117–25
59. Gargani L: Lung ultrasound: A new tool for the cardiologist. *Cardiovasc Ultrasound* 2011; 9:6
60. Copetti R, Soldati G, Copetti P: Chest sonography: A useful tool to differentiate acute cardiogenic pulmonary edema from acute respiratory distress syndrome. *Cardiovasc Ultrasound* 2008; 6:16
61. Mandeville JC, Colebourn CL: Can transthoracic echocardiography be used to predict fluid responsiveness in the critically ill patient? A systematic review. *Crit Care Res Pract* 2012; 2012:513480
62. Shankar H, Pagel PS: Potential adverse ultrasound-related biological effects: A critical review. *ANESTHESIOLOGY* 2011; 115:1109–24
63. Tabata T, Thomas JD, Klein AL: Pulmonary venous flow by Doppler echocardiography: Revisited 12 years later. *J Am Coll Cardiol* 2003; 41:1243–50
64. Keren G, Bier A, Sherez J, Miura D, Keefe D, LeJemtel T: Atrial contraction is an important determinant of pulmonary venous flow. *J Am Coll Cardiol* 1986; 7:693–5
65. Vignon P, AitHssain A, François B, Preux PM, Pichon N, Clavel M, Frat JP, Gastinne H: Echocardiographic assessment of pulmonary artery occlusion pressure in ventilated patients: A transoesophageal study. *Crit Care* 2008; 12:R18
66. Vignon P: Hemodynamic assessment of critically ill patients using echocardiography Doppler. *Curr Opin Crit Care* 2005; 11:227–34
67. Boussuges A, Blanc P, Molenat F, Burnet H, Habib G, Sainty JM: Evaluation of left ventricular filling pressure by transthoracic Doppler echocardiography in the intensive care unit. *Crit Care Med* 2002; 30:362–7
68. Lamia B, Maizel J, Ochagavia A, Chemla D, Osman D, Richard C, Teboul JL: Echocardiographic diagnosis of pulmonary artery occlusion pressure elevation during weaning from mechanical ventilation. *Crit Care Med* 2009; 37:1696–701
69. Dokainish H, Zoghbi WA, Lakkis NM, Al-Bakshy F, Dhir M, Quinones MA, Nagueh SF: Optimal noninvasive assessment of left ventricular filling pressures: A comparison of tissue Doppler echocardiography and B-type natriuretic peptide in patients with pulmonary artery catheters. *Circulation* 2004; 109:2432–9
70. Caille V, Amiel JB, Charron C, Belliard G, Vieillard-Baron A, Vignon P: Echocardiography: A help in the weaning process. *Crit Care* 2010; 14:R120