

ENDOBONCHIAL ANESTHESIA FOR INTRATHORACIC SURGERY * †

JOHN J. BONICA, M.D. ‡
Tacoma, Washington

AND

WILLIAM M. HALL, M.D. §
Vancouver, British Columbia, Canada

Received for publication January 3, 1950

THE disturbances of respiratory and cardiovascular physiologic processes which occur during intrathoracic operations have long been recognized and appreciated by surgeons and anesthesiologists, and many methods have been introduced and employed to obviate and minimize them. As early as 1896 Tuffier and Hallion (1) of France and Milton (2) of England advocated tracheal insufflation for the expansion of the lung in the presence of pneumothorax. Two years later Matas (3) of New Orleans used a modification of the Fell O'Dwyer (4) tube which he introduced into the larynx of a patient to correct the acute collapse which followed the opening of the pleura during one of the first thoracic operations performed in this country. The patient immediately improved and subsequently Matas advocated the use of intralaryngeal anesthesia for the prevention of surgical pneumothorax (5). Still later, through the efforts of Sauerbruch of Germany, Giertz of Sweden, Matas and Meyer of this country, and others (6), several other methods were developed and given clinical trial in order to obviate these physiologic alterations. Negative pressure chambers large enough to contain the patient and the entire surgical team were constructed, and rhythmically working respiratory pumps and small pressure cabinets to contain only the patient's head were also introduced. These, however, proved impractical and were abandoned with the advent of modern anesthetic appliances and the use of positive pressure applied with a tight fitting mask or endotracheal tube.

Many intrathoracic operations have been successfully performed by means of a mask alone and although most anesthesiologists believe

* Presented at the Annual Meeting of the American Society of Anesthesiologists, November 9, 1950.

† From the Departments of Anesthesia, Tacoma General Hospital, Tacoma, Washington, Shaughnessey Hospital, and Vancouver General Hospital, Vancouver, British Columbia, Canada.

‡ Director, Department of Anesthesia, Tacoma General Hospital, Tacoma, Washington.

§ Chief Anesthetist, Shaughnessey Hospital, Vancouver, British Columbia, Canada.

that an endotracheal catheter is necessary to obtain adequate operating conditions, several anesthesiologists claim equally good results with the simple mask technic (7).

The reintroduction of the closed endotracheal technic for the administration of inhalation anesthesia by Guedel and Waters in 1928 (8) and its subsequent universal adoption for intrathoracic surgery have perhaps been the greatest single factor in the great developments in this field during the past twenty years. This method of closed anesthesia which was originally described and used in experimental animals by Green (9) in 1906* and applied to man several years later by Janeway (10) and by Dorrance (11) has afforded almost ideal conditions for the thoracic surgeon with less disturbances to the patient than had been afforded by previous methods. Certainly, the results obtained in the many thousands of cases in which it has been used provide sufficient evidence as to its efficacy in operations involving surgical pneumothorax. In spite of such an excellent record, many thoracic surgeons and anesthesiologists believe that in certain circumstances, endotracheal anesthesia provides good but not optimal conditions for the surgeon, and it does not completely eliminate for the patient the danger of sudden drowning by excessive mucopurulent secretions or blood, or contamination of the healthy lung. This is particularly true in patients who have a bronchopleural fistula, lung abscess or cyst, or severe bronchiectasis with large amounts of secretions. Several authors (12-23) have proposed that in such cases intrathoracic surgical procedures could be best and most safely accomplished with the endobronchial technic in which the anesthesia and ventilation are maintained through one lung by passing a long endotracheal tube into its bronchus, thus completely sealing off the diseased side so that its secretions cannot spill over and impair the function of the normal lung (fig. 1).

The method of one-lung anesthesia by the endobronchial technic was first described by Gale and Waters (12, 13) in 1932 after some experimental work with animals and clinical experience in a number of cases. They employed a semirigid catheter with an inflatable cuff which was passed into the trachea by the usual direct orotracheal route with the aid of a laryngoscope and thence to the desired bronchus by the "blind" technic. They thought that this method completely eliminated hypoxia, carbon dioxide excess, mediastinal shift and paradoxical respiration and, in addition, afforded the surgeon excellent exposure and a quiet surgical field by complete collapse of the diseased lung.

* To avoid a controversy it may be pointed out that Green was the first to use the closed endotracheal technic for intrathoracic operations (on animals) by introducing a wide-bored tube fitted with an inflatable cuff. The general use of endotracheal anesthesia, however, was described long before by John Snow (1858), Trendelenburg (1871), Macewen (1880), and many others. Trendelenburg (1871) was the first to describe the inflatable cuff which was later adopted by Eisenmenger (1893) and others (see Gillespie, Noel: Endotracheal Anesthesia. The University of Wisconsin Press, 1948, Madison, Wisconsin).

They were of the opinion that this was "the most practical method to employ in intrathoracic operations in which a pleural cavity must be opened." Four years later (1936, Magill 14, 15) of England described two methods of achieving one-lung anesthesia, both of which were somewhat different from that of Gale and Waters. One of the methods

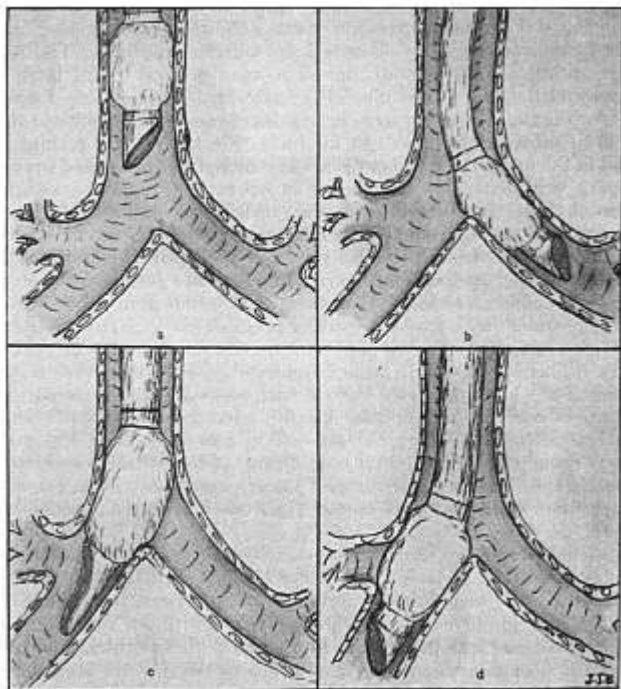


FIG. 1 (a) Endotracheal tube (with inflatable cuff) in place. (b) Left endobronchial tube in proper place, sealing off the right bronchus. (c) Right endobronchial tube with long lipped bevel and special one seam cuff properly placed. (d) Right endobronchial tube with conventional short bevel and two seam cuff improperly placed occluding the eparterial bronchus.

entailed the use of a rubber covered spiral metal tube provided with an inflatable cuff which was introduced into the desired bronchus under direct vision with the aid of a modified bronchoscope fitted inside the tube (fig. 2a). The second technic was accomplished by plugging off the diseased lung or lobe by introducing a fine suction catheter

which was equipped with a small inflatable cuff, and which was introduced into the bronchus under direct vision, inflating the cuff so as to seal the diseased part and then conducting anesthesia by means of the endotracheal technic (fig. 2b). In the same year Rovenstine (16) pub-

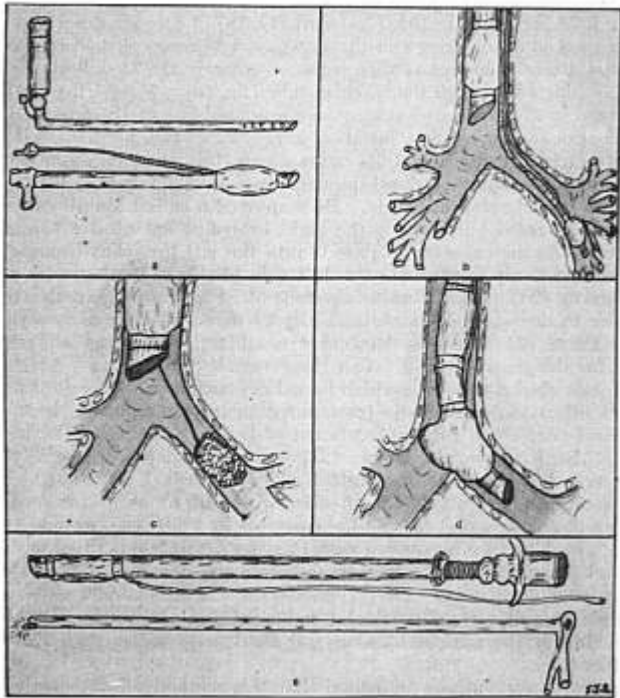


FIG. 2 (a) Magill endobronchial tube composed of rubber covered spiral tube (fitted with cuff) and a modified bronchoscope. (b) Magill's technic of plugging diseased bronchus with fine suction catheter equipped with small cuff. (c) Crafoord's technic of one-lung anesthesia by plugging bronchus with gauze tampon. (d) Rovenstine double cuffed tube for endobronchial anesthesia. (e) Ruth-Bailey endobronchial tube. Part of rubber tubing covering it has been rolled back to show spiral wire.

lished a paper on anesthesia for intrathoracic surgery in which he discussed endobronchial anesthesia, pointing out the advantages that it offers in selected cases. He employed a semirigid catheter which was fitted with two inflatable cuffs, one placed within an inch of the open

end of the tube and the second separated from the first by about 2 inches. The catheter was introduced blindly into the desired bronchus and the distal cuff was inflated, sealing off the opposite side. Whenever bilateral ventilation was indicated, the distal cuff was deflated and the proximal inflated, affording closed endotracheal anesthesia (fig. 2d).

In 1938 and again in 1940 Crafoord (17, 18) of Sweden described another method of one-lung anesthesia which was accomplished by blocking the diseased bronchus with a gauze tampon, the anesthesia being then conducted through the tracheal tube (fig. 2c). Nosworthy (19) of England in 1941 wrote what may be considered one of the outstanding publications on anesthesia for chest surgery in which he discussed the endobronchial technic and its advantages for pneumonectomy, for transthoracic repair of diaphragmatic hernia and for surgical treatment of bronchopleural fistula. He employed a cuffed Magill catheter which he passed blindly into the right bronchus but used a bronchoscope inside the catheter to pass it into the left bronchus because he found it difficult to intubate the left side blindly. In the same year McCuskey (20) used a Woodbridge tube fitted with a semicircular light carrier to introduce it endobronchially by direct vision and two years later Caine (21) used the McCuskey modification of the Woodbridge tube for the same purpose. Van Hoogstraten (22) of South Africa in 1941 published a report in which he indicated that endobronchial anesthesia offered advantages in intrathoracic surgery, particularly in operations performed for the treatment of hydatid disease of the lungs. In 1947 Ruth, Grove, and Keown (23) presented a paper in Los Angeles in which they described the Ruth-Bailey endobronchial tube which is a noncollapsible airway made of coiled wire with an obturator containing an auxiliary canal for the light carrier as well as an oxygen tract (fig. 2e). The tube is covered with Penrose drain and is fitted with an inflatable cuff, thus affording the advantages of a bronchoscope and noncollapsible airway. They reported its use in over 50 cases and thought that it was of particular value in eliminating the danger of drowning of the patient by excessive fluid and contamination of the healthy lung.

All of these authors indicated that this method offers certain advantages and is ideal in certain conditions but also emphasized the technical difficulties encountered with the endobronchial technic in (a) blindly intubating the left bronchus, (b) obstruction of the eparterial bronchus during right bronchial intubation (fig. 1d), and (c) keeping the tube in place after intubation, and with the bronchus plugging method, the danger of the plug slipping out and occluding the sound bronchus causing respiratory obstruction. These technical difficulties have undoubtedly discouraged most anesthesiologists from employing the endobronchial technic.

In 1945 one of the authors (W. M. H.) and, a year later, the other,

independently began to use one-lung anesthesia for pneumonectomy. It soon became evident to them that this method afforded better conditions for the surgeon, less physiologic disturbances to the patient, and consequently more "comfort" to the anesthesiologist than had been obtained with endotracheal anesthesia. The chest surgeons became so impressed with the ideal working conditions which were produced by the motionless operating field that one-lung anesthesia was requested for almost all of the intrathoracic cases. During this period the authors and their associates have employed the method for over 200 operations. It is the purpose of this paper to present the technics used with particular emphasis on the simple method of blind endobronchial intubation which could be easily accomplished by anyone who has had experience with the direct endotracheal method. We also hope to emphasize the advantages that this technic offers in selected cases.

METHOD OF ANESTHESIA

The following is a brief description of the method of anesthesia which has been employed by the present authors and their associates in intrathoracic surgical procedures. Although working independently in two different cities, the authors have employed similar technics of endobronchial anesthesia with only minor differences which will be mentioned. The blind endobronchial technic to be discussed was evolved by Hall at Shaughnessey Hospital, Vancouver, B. C., and was later adopted by Bonica who had previously employed the direct vision technic with the Ruth-Bailey tube.

Preoperative Preparation.—In addition to the usual preoperative evaluation and preparation, a study of the chest roentgenograms is made and any deviation of the trachea is noted. This is of particular importance in patients having a preoperative pneumothorax or atelectasis which may cause marked deviation of the trachea and make endobronchial intubation difficult (fig. 3). Whenever indicated, the vital capacity is ascertained. Patients who have bronchiectasis or history of productive cough are placed on postural drainage for one to two hours before operations. Premedication usually consists of small doses (0.1 Gm.) of barbiturate given two hours before anesthesia and morphine or demerol with a relatively large dose (0.6 mg.) of atropine given one hour before induction. Immediately before the induction one of the authors (J. J. B.) topically anesthetizes the larynx, trachea and bronchi, and administers paravertebral block on the affected side. These two procedures have been done in 47 patients with the belief that they obviate annoying and sometimes alarming vagovagal and periosteal reflexes. Topical anesthesia is effected with 3 cc. of 5 per cent cocaine or 2 per cent pontocaine, usually applied by the transtracheal route, a technic which was originally described by Canuyt (24) and recently introduced by Bonica (25) and others (26). It is believed that

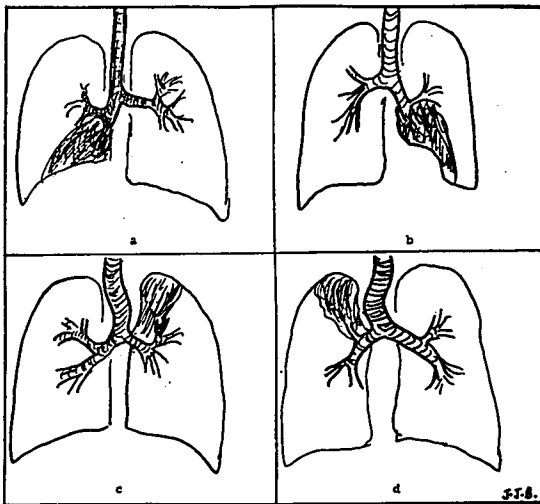


FIG 3. Deviation of the trachea and bronchi due to atelectasis of (a) right lower lobe, (b) left lower lobe, (c) left upper lobe and (d) right upper lobe. Note the distortion of the angles at the bifurcation of the trachea.

this affords better and more complete topical anesthesia of the respiratory tree than any other method available. If endobronchial intubation is contemplated, the transtracheal injection is done with the patient in the sitting position, leaning to the side to be intubated (supported by someone). Three cubic centimeters of solution is sufficient to anesthetize the larynx, trachea and bronchi completely, and in most instances endobronchial intubation in light planes of anesthesia does not provoke bronchospasm or any other respiratory derangement.

Paravertebral block of four segments, two on either side of the rib to be removed, is performed either immediately before or soon after induction (if sufficient personnel is available), using 10 cc. of 0.15 per cent pontocaine without epinephrine for each segment. The epinephrine is omitted in most cases because cyclopropane is usually employed and, although its omission shortens the duration considerably, it has been found that pontocaine in this concentration without vasoconstrictors affords a three hour block.

Induction of Anesthesia.—The induction is usually carried out with 2.5 per cent pentothal and d-tubocurarine, although cyclopropane and nitrous oxide-ether have also been employed. Sufficient amounts of these agents are given to bring the patient into midsurgical anesthesia.

Controlled respiration is then instituted by hyperventilation with cyclopropane-oxygen. When the patient reaches the third plane of surgical anesthesia, the endobronchial tube is inserted.

ENDOBONCHIAL INTUBATION

In order to secure successful endobronchial intubation, certain anatomical points must be recognized and appreciated. The trachea is a cartilaginous and membranous tube extending from the cricoid cartilage of the larynx at the level of the sixth cervical vertebra to the upper border of the fifth thoracic vertebra where it divides into the bronchi (fig. 4a). It is nearly, but not quite cylindrical, being flattened posteriorly (fig. 4b) and having an anteroposterior diameter of 12 mm. and a transverse diameter of 12.5 to 15 mm. Its average length in the

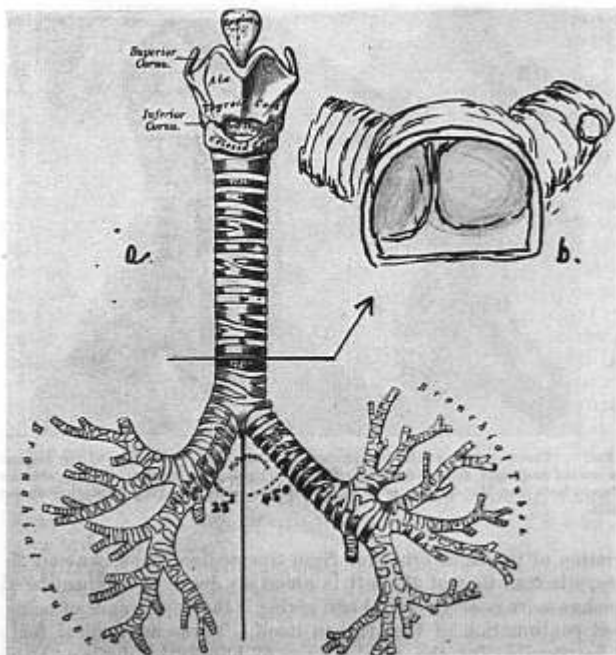


FIG. 4. (a) Front view of tracheobronchial tree. (b) Top view near its bifurcation showing the opening of the two main bronchi. Note that opening of the right bronchus takes up about two-thirds of the entire area.

adult is 10 to 12 cm. and therefore the distance from the dental margin to the bifurcation is approximately 25 cm. The trachea adheres to the median plane, except toward its termination where the aortic arch deflects it very slightly to the right. The carina or septum of the trachea occupies a position left of the midtracheal line so that the opening of the right bronchus occupies two-thirds of the total transverse space of the distal end of the trachea (fig. 4b). In addition, the normal angle of

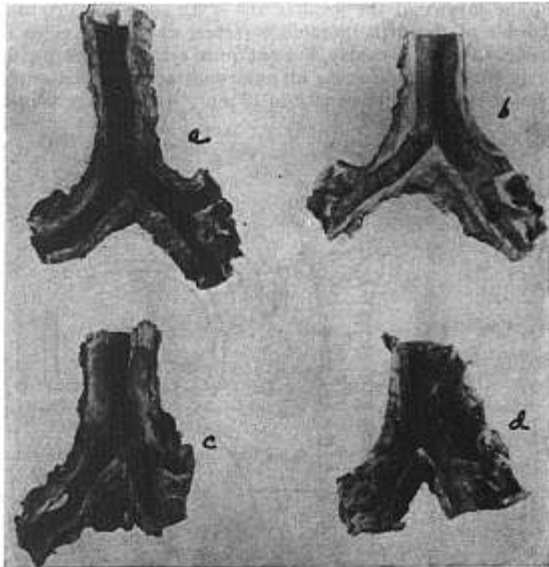


FIG. 5. Posterior view of the tracheobronchial tree to show variation of the distance between carina and right upper lobe bronchus. (a) Showing the longest, and (c) the shortest distance. Note that the opening of C is opposite the carina, making intubation almost impossible.

deviation of the right bronchus from the median plane is about 25 degrees, whereas that of the left is about 45 degrees, making the right bronchus more nearly vertical and giving it the appearance of being the direct continuation of the trachea itself. These anatomical features are responsible for the greater ease of blindly intubating the right bronchus. The length of the right bronchus is often given as 2.5 cm. and that of the left as 5.0 cm., but examination of many actual speci-

mens* revealed that the length of the right bronchus widely varied from 0.3 cm. to 2.5 cm. and in some instances the right upper lobe actually arose opposite the carina (fig. 5). In such cases endobronchial intubation of the right side with the usual Magill tube would be very difficult to do without occluding the eparterial bronchus. The right bronchus is also wider than the left.

Blind Endobronchial Intubation

With the technic to be described we are now able to intubate either lung blindly and we believe that, with appreciation of the anatomical features and the use of this method, even the novice will be able to intubate successfully either bronchus. Although left blind bronchial intubation presents more technical difficulties than right intubation and one is not always able to insert the tube correctly on the first attempt, repeated attempts will usually prove successful. The equipment necessary for this technic is that usually employed for endotracheal intubation. A number 9 or 10 (34-37 F) rubber Magill catheter is used, fitted with a Waters-Guedel cuff which is placed as far distal as possible without encroaching on the bevel. These catheters, as supplied by the manufacturer, are 36 to 42 cm. long and have a bevel on the left side which is adequate for left-sided intubation, but not for insertion into the right bronchus. For right bronchial intubation the original tube is cut so that there is a new long-lipped (3 cm.) bevel facing toward the right (fig. 6a). This allows the long tip of the bevel to be inserted well into the right bronchus and thus gives anchorage to the endobronchial tube without occluding the upper bronchus. The tube is also fitted with a cuff which has only one seam (fig. 6b). The usual Waters-Guedel cuff has two seams and the presence of the distal seam makes it almost impossible to place the inflatable portion of the cuff close enough to the bevel so that one may be sure that the cuff is inflated within the bronchus to occlude the left bronchus, but not the right eparterial bronchus (fig. 6c). Using a cuff with a single proximal seam (made by folding a single length of latex tubing upon itself) makes possible the inflation of some portion of the cuff within the right bronchus, thus effectively sealing off the left side (fig. 6b). Since blind intubation of each bronchus presents certain technical difficulties which are peculiar to that side, the procedure for the two sides will be described separately.

Blind Left Endobronchial Intubation.—When proper depth of surgical anesthesia is reached, the tube with the conventional left-sided bevel is well lubricated with an anesthetic ointment and inserted into the upper trachea by the oral route with the aid of a laryngoscope. The laryngoscope is then removed, the catheter is rotated 90 degrees in

* Examinations were done in the Anatomy Laboratory of the University of Washington Medical School under the direction of Dr. Robert Johnson, Associate Professor of Anatomy.

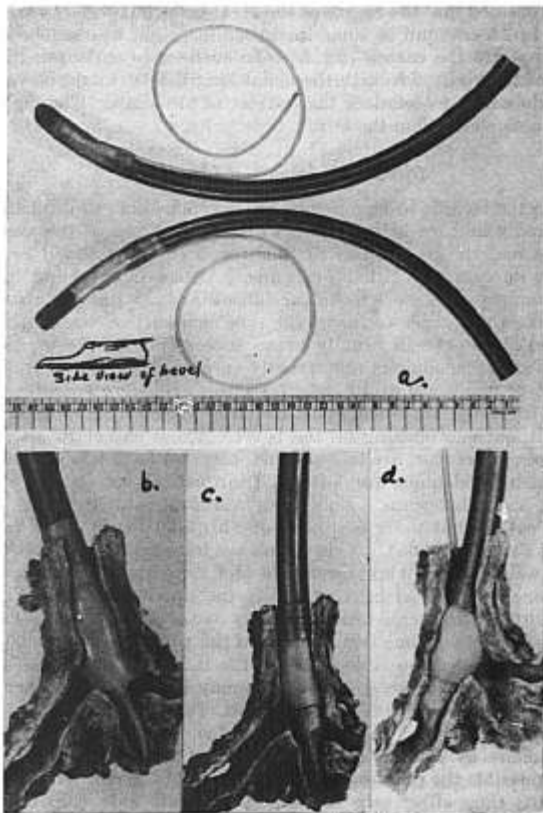


FIG. 6. (a) Long endotracheal tubes modified for endobronchial intubation. Note the long lipped lower tube with one seam cuff used to intubate right bronchus. (b) Shows tube with one seam properly placed. (c) Shows tube with the conventional two seam cuff making impossible the occlusion of the left bronchus without occluding the right upper lobe bronchus. (d) Properly placed left endobronchial tube.

a counter-clockwise direction so that its long curve has the concavity to the left and then advanced gently. This counter-clockwise rotation causes the tip of the catheter to slide down the left wall of the trachea and enter the left bronchus (fig. 7). If the catheter is not rotated, but advanced in the median plane, the more divergent angle at which the left bronchus leaves the trachea will cause the catheter to enter the

right bronchus. This is the most important step for successful blind intubation of the left bronchus. After the catheter has entered the bronchus, it is further gently advanced until resistance is encountered, indicating that its tip has become jammed in the narrowing left main bronchus or has entered the left lower lobe bronchus. It is then carefully withdrawn slightly and simultaneously rotated 90 degrees in a clockwise direction so that the concavity of the catheter is again facing anteriorly and its bevel facing laterally. The endobronchial tube is connected to the anesthetic machine and controlled respiration is resumed. If the catheter has been properly placed, compression of the bag causes the left (but not the right) chest to expand freely. Correct position of the catheter is further confirmed by auscultation with a stethoscope which should reveal clear breath sounds both in the left upper and lower lobes. Absent or rough breath sounds in the left upper lobe indicate obstruction of the bronchus which must be correlated by careful withdrawal of the tube until sounds are perfectly clear. The cuff is then inflated and the chest reexamined. Presence of breath sounds on the right indicate that the catheter has been withdrawn too far and is in the trachea and therefore must be reinserted into the bronchus.

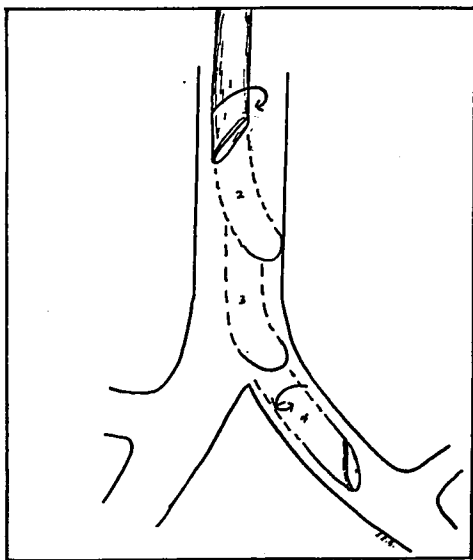


FIG. 7. Method of intubating left bronchus by the "blind technic." Steps 1-4 show descent of tube. Note rotation of tube in steps 1 and 4.

Blind Right Endobronchial Intubation.—The technical difficulty which has been encountered and emphasized by previous authors in performing right bronchial intubation is not in placing the catheter but in avoiding obstruction of the eparterial bronchus and still maintaining the catheter in the right main bronchus throughout the operation. We have solved this problem by using the right long-lipped tube with a single seam cuff as previously described. The tube is well lubricated with an anesthetic ointment and introduced into the trachea with the aid of a laryngoscope, then the laryngoscope is removed and the tube advanced until resistance is encountered, which denotes that the tube has entered the right bronchus. Because of the aforementioned anatomical features of the lower trachea it is not necessary to rotate the tube. It is then connected to the machine, controlled respiration resumed and the chest examined with a stethoscope. Auscultation usually reveals that the tube is too far down, partially or totally occluding the eparterial bronchus and necessitating slight withdrawal. This is done slowly and carefully while an assistant listens to the breath sounds, particularly those of the right upper lobe. When the sounds are clear in this lobe, the cuff is inflated and the chest reexamined. A properly placed tube should completely occlude the left side and eliminate its breath sounds. Very rarely, owing to a deviation of the trachea as a result of atelectasis or pneumothorax (fig. 3), the tube enters the left instead of the right bronchus. In such instances it becomes necessary to withdraw the tube into the trachea and rotate it to the right before it is advanced.

When the anesthesiologist is quite satisfied that the tube is in the correct position, it is strapped in place with adhesive, a mouth prop is inserted between the teeth, and the patient placed in position for operation, usually in the lateral position. Great care must be taken to prevent displacement of the catheter from the bronchus during the positioning of the patient. In turning the patient it is absolutely necessary to keep the head of the patient in the same relationship to the chest that it was in the supine position. If this relationship is not maintained and the head is allowed to extend or flex, there is consequent change in the distance between the teeth and the bronchi, causing displacement of the tube. As soon as the patient is secured in the operative position, the chest is again examined with a stethoscope and proper ventilation is ascertained. In the event that the tube has become displaced and there is respiratory obstruction or bilateral ventilation, it is essential to replace the tube properly even if it is necessary to return the patient to the supine position.

Endobronchial Intubation Under Direct Vision

One-lung anesthesia may also be obtained by intubating the bronchus under direct vision, employing the special Ruth-Bailey or Magill endobronchial tube or by inserting a small bronchoscope within a large

endotracheal tube of proper length. Direct intubation was used in 36 of the cases done by Bonica. The tube is inserted in the same manner as an ordinary bronchoscope is introduced and needs no further comment. After it is in place the same precautions are taken in placing the patient in position in order to avoid displacement of the tube. This method, of course, offers the advantages of direct vision intubation. In 3 patients, one-lung anesthesia was obtained by inserting a gauze tampon into the affected bronchus with the aid of a bronchoscope and then using the endotracheal tube as described by Crafoord (17, 18). The possibility of the gauze being displaced caused us to abandon it in favor of the present technic.

CONDUCT OF ANESTHESIA

The conduct of anesthesia following the proper placement of the tube and position of the patient is the same as with the endotracheal technic. Two intravenous infusions are started with a 15 gauge needle and administration of blood is initiated as soon as the operation is started. Blood loss is accurately measured by means of the gravimetric method and an attempt is made to replace it as it is being lost. This is of particular value in patients undergoing excisional operations on the lung, because overreplacement or underreplacement is avoided.

Controlled respiration with the carbon dioxide absorption technic is a *sine qua non* during endobronchial anesthesia. Control is obtained before the tube is inserted and maintained throughout the operation until the pleura is closed. This control is usually achieved by (a) raising the respiratory threshold with the anesthetic and other depressants, keeping the patient in the second plane of anesthesia, (b) decreasing the stimulus below the respiratory threshold level by hyperventilating the patient and thus lowering the carbon dioxide in the blood,* (c) by paralyzing the respiratory muscles with curare or similar preparation, or (d) by a combination of these. The occurrence of small diaphragmatic contractions during the operation heralds the return of active respiration, in which case the anesthesia is deepened or the minute volume of respiration increased, or both. In the event that this is inadequate for complete control, a small dose of morphine or 2 or 3 cc. of curare is given intravenously, depending on the stage of the operation. In the early stages morphine, because of its prolonged action on the center, is preferred, whereas in the later stages curare is given. Efficient carbon dioxide absorption is, of course, absolutely essential. We employ both the circle and to-and-fro absorption technic.

For maintenance, cyclopropane is the primary agent used in most cases. When this agent is not suitable because the patient has irregular cardiac rhythm or is otherwise contraindicated, ether is employed. Pentothal sodium complemented with nitrous oxide-oxygen can

* Some authors (27) believe that the chief cause for such apnea is the rhythmic pulmonary distention resulting in inhibition of the Hering-Brewer reflex.

also be used when the surgeon wants to employ the cautery during intrathoracic procedures or for any other reason for which it may be particularly indicated. Although we prefer the evanescence and flexibility of cyclopropane, we are firmly convinced that the agent *per se* is not of primary importance, but rather the administration of the agent is the most important factor for optimal results.

Following endobronchial intubation the occluded lung becomes atelectatic owing to the rapid absorption of oxygen and anesthetic gases and vapors from the alveoli. In the event that the lung is still expanded when the pleura is opened, collapse is accelerated by the surgical pneumothorax created by opening the pleura and by the manipulation of the surgeon. The lung then remains collapsed for the entire operation, obviating traumatic retractions and affording the surgeon a completely motionless operative field.

In our series of cases several other procedures have been carried out whenever they were indicated. Secretions in the intubated lung were immediately removed by means of a suction catheter. An attempt was made to prevent disturbing reflexes by (a) the intravenous administration of relatively large doses (0.6 mg.) of atropine about five minutes before the surgeon manipulated the thoracic viscera, (b) infiltration of a local drug around the hilar region by the surgeon, (c) the intravenous infusion of procaine solutions and (d) vagus nerve block. We believe that of these procedures, intravenous atropine is the most efficacious and the most practical. The infiltration of local anesthetic around the hilar region has been questioned on the ground that reflexes may be elicited by manipulation during injection. Intravenous procaine has been administered in single doses of 100 to 150 mg. as advocated by Burstein (28) or by a continuous infusion of 0.2 to 1.0 per cent solutions as advocated by Bittrich (29) and others. In several instances procaine did not prevent arrhythmias which were eventually corrected by intravenous atropine and a pause in the surgical manipulations. In one case cardiac arrest occurred while the vagus nerve was being manipulated during resection of the esophagus in spite of the fact that procaine was being administered continuously. Fortunately, it was immediately diagnosed and cardiac massage and artificial respiration with 100 per cent oxygen for twelve minutes effected complete and uneventful recovery. In order for anesthesia to be effective, the vagus nerve must be blocked bilaterally at the base of the skull, a procedure which is difficult to do while the patient is in the lateral position and which often causes tachycardia and other undesirable effects. The prophylactic use of quinidine, as advocated by Leif (30) and Collins (33), may be of value in preventing many of these alarming disturbances of cardiac rhythm.

Cardiac dysfunction caused by pressure on the heart with retractors not uncommonly occurs during intrathoracic operations. We have treated this by removing all the retractors and packs and allowing

the heart to resume normal action. In one case the dramatic dilatation of the heart, apparently due to interference of the contractions, was successfully treated by interruption of the procedure, administration of ouabain and artificial respiration through the endobronchial tube. Two other cases of cardiac decompensation which occurred on the operating table were treated with intravenous administration of ouabain.

At the end of the operation respirations are allowed to return but are compensated until the tube is removed. As soon as the surgeon is finished and before dressings are applied, one of us (J. J. B.) routinely performs a paravertebral block with pontocaine-epinephrine solution. This block, which is repeated daily for the first three or four

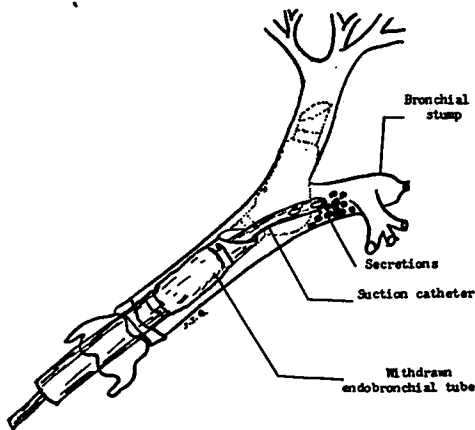


FIG. 8. Endobronchial extubation with patient in Trendelenburg position allowing the secretions to gravitate cephalad into the trachea to be aspirated.

postoperative days, affords six to eight hours of excellent analgesia, allowing the patient adequately to cough up any secretions and to move around. As soon as the block is completed and the dressings applied, the patient is turned on his back and placed in moderately steep Trendelenburg. The suction catheter is then passed through the lumen of the endobronchial tube into the bronchus, the cuff is allowed to deflate and the endobronchial catheter is withdrawn into the trachea. This procedure prevents the dammed back secretions from entering the normal lung, but allows them to gravitate cephalad and to be caught with the suction (fig. 8). The tube is then completely removed and the mouth and pharynx cleaned by suction. Bronchoscopy is performed if it is indicated.

No attempt will be made to present a detailed analysis of the data accrued in these cases. It may be stated, however, that this technic has been used for a variety of intrathoracic operations (table 1) performed on patients of all ages, ranging from 13 to 79 years, and all types of physical risks.

DISCUSSION

Rovenstine (16) has given three reasons to explain the lack of popularity of the endobronchial technic. The first is the technical difficulties encountered in the proper placement of the tube, the second is that it eliminates one lung from the respiratory tract and requires continuous artificial respiration, and the third is that the indications for its use are very limited.

We believe that the technic and equipment herein described will eliminate the difficulties in properly placing the endobronchial tube. Bronchial intubation may be practiced on patients who require endotracheal anesthesia after the operation is completed, and also by using

TABLE I
ENDOBONCHIAL ANESTHESIA FOR THORACIC SURGERY
Report of 216 Operations

Operation			
a. Pneumonectomy			94
Carcinoma	72		
Bronchiectasis	9		
Tuberculosis	8		
Lung abscess	4		
Arteriovenous aneurysm	1		
b. Lobectomy or segmental resection			87
Bronchiectasis	70		
Tuberculosis	9		
Foreign body	2		
Fistula	3		
Lung abscess	3		
c. Exploratory thoracotomy			16
Carcinoma of the lung	11		
Carcinoma of the esophagus	2		
Mediastinal tumor	3		
d. Miscellaneous			19
Drainage of lung abscess	3		
Drainage of mediastinal abscess	1		
Excision of foreign body	1		
Closure of bronchopleural fistula	4		
Transthoracic resection of esophagus	7		
Transthoracic repair of diaphragmatic hernia	3		
Total			216
Number of patients			194
160 had one operation			
22 had two operations			
Technic of intubation		Side intubated	
Blind	177	Right	99
Direct vision	36	Left	114
Crafoord technic	3	Crafoord technic	3

a model or specimen of the tracheobronchial tree. Our residents have been able to master the technic after a little practice. Direct vision intubation, by inserting a small bronchoscope inside these modified tubes, can also be employed to eliminate these difficulties. For right bronchial intubation a tube made of coiled wire impregnated in latex rubber and having a long lip as herein described may further aid this problem. We firmly believe that the technical difficulties encountered are no greater than those of endotracheal anesthesia or bronchoscopy and can easily be mastered by the average anesthesiologist.

The objections raised in regard to the elimination of one lung and the use of continuous controlled respiration during endobronchial anesthesia are based on the assumption that these interfere with the physiologic processes of respiration and circulation. As a matter of fact, this technic was originally conceived with the idea that it would aid rather than disturb these functions, and such is the general consensus among those clinicians who have had experience with it. In order to obtain proper ventilation and to prevent or counteract the effects of paradoxical respiration, mediastinal shift and flutter which may cause harmful respiratory and circulatory reflexes and disturbances of the cardiovascular hemodynamics—all of which are consequences of the surgical invasion of the intrapleural space—compensated or controlled respiration is necessary in most intrathoracic operations. If automatic respiration is not aided the respiratory dynamics deteriorate rapidly and pulmonary decompensation ensues. The use of compensated respiration as described by Burstein and Alexander (31) is excellent when properly performed. We believe that controlled respiration also offers optimum conditions because of its efficiency in the ventilation of the patient and the better operating conditions which it affords the surgeon and, in addition, it spares the patient the strain and labor which is inherent during respiration in the lateral position in which the function of the normal lower lung is hampered and much of the weight of the body must be lifted with each inspiration. The theoretical objection that the reversal of the respiratory and circulatory dynamics enhances rather than prevents respiratory and circulatory decompensation has not been observed clinically. On the contrary, patients who manifest signs of decomposition immediately improve after controlled respiration is instituted, a procedure which is often employed even by those who dispute its value. We agree with Nosworthy (19) that the patient's breathing often is not as efficient as controlled respiration.

The one legitimate objection to controlled respiration is that the inflation of the lung often causes it to bellow out into the operative field, but this can be completely eliminated by employing endobronchial anesthesia. This latter procedure allows full expansion of the contralateral lung, thus affording efficient ventilation of the patient without disturbing the surgeon. The fact that one lung is eliminated does not

reduce total oxygenation, because the quantity of unaerated blood flowing through a completely collapsed lung is minimal.

The fact that endobronchial anesthesia is of value only in certain operations should not preclude its use in these cases. In addition to its value for pneumonectomy, we believe that the problems of the surgical treatment of lung abscess, cyst and bronchopleural fistula are best met with this form of anesthesia. When any method other than the endobronchial technic is employed, the pus, blood or fluid which may be accidentally liberated during manipulation of an abscess or cyst may not be removed rapidly enough by suction and the patient may drown. Even if the suction is efficient there is interruption of the closed system with consequent escape of the anesthetic agent which, in addition to that removed by the suction, may be sufficient to upset the smoothness of the anesthesia. Furthermore, opening of the cyst or abscess may create a bronchopleural fistula with further loss of the anesthetic and a means of inflating the lung. A bronchopleural fistula present before operation, of course, presents the same problem. With endobronchial anesthesia these problems are eliminated because the unaffected lung is protected from contamination, a clear airway is always maintained, interruption of the anesthetic is not necessary, and thus a smoother and more even anesthetic and better oxygenation of the patient are possible. Many clinicians believe that this technic should not be considered unless pneumonectomy is contemplated because the blocked lung or lobe may not be completely reexpanded at the end of the operation following such long periods of collapse. Until recently we held the same view and it was only upon the insistence of the surgeons that we, with some trepidation, employed it for lobectomies, for trans-thoracic repair of diaphragmatic hernias, and other intrathoracic procedures. Originally it was planned that if it became necessary, the tube would be withdrawn and the anesthetic carried by the endotracheal method. In all our cases we have obtained what has been considered optimal conditions and in no instance did it become necessary to withdraw the tube. Hall, upon the specific request of the surgeon, has employed endobronchial anesthesia for 44 operations of bilateral lower lobectomy in 22 patients. In one of these patients the vital capacity of the functioning lobe was 800 cc. on which the patient was carried for four and one-half hours.

We have found the repeated reexpansion of the noninvolved lobes of the operative side is not necessary and that even after being collapsed for three to four hours these lobes could be easily and completely reexpanded at the end of the operation, if this is desired. In some patients who had lobectomies, the tube was withdrawn into the trachea and the remaining lobe or lobes were inflated and expanded before the pleura was closed. In many cases, however, the remaining lobe of the blocked side was not reinflated, but was allowed to reexpand postoperatively as the negative intrapleural pressure increased. Post-

operative roentgenograms revealed that in no instance did the remaining lobe fail to expand. In cases in which segmental resection is desired and identification of the segment is necessary, Webb (32) has suggested that instead of abandoning the endobronchial technic, the surgeon can inflate the involved segment by using a 50 cc. syringe and a needle inserted into the isolated bronchus.

It must be reemphasized at this point that we do not propose to substitute this technic for endotracheal anesthesia for all intrathoracic operations, but rather wish to indicate that in selected cases where it offers certain advantages, it may be used with minimal undesirable effects. We are in full accord with many others that many operations can be performed with endotracheal anesthesia. However, to dismiss the use of endobronchial anesthesia by stating that the endotracheal technic is "good enough" is manifest of an unprogressive attitude. Those surgeons who have had the experience of working with endobronchial anesthesia become such enthusiasts that they usually request it for most intrathoracic procedures. All of our thoracic surgeons have indicated that for pneumonectomy, bronchopleural fistula, lung abscesses and some cases of bronchiectasis they prefer endobronchial intubation to any other method of anesthesia.

SUMMARY AND CONCLUSIONS

Whenever intrathoracic procedures create an open pneumothorax, a technic must be employed which affords optimal pulmonary control of tracheobronchial secretions and the movements of the intrathoracic viscera, diaphragm and chest wall, adequate analgesia, and as little disturbance of physiologic function as possible. In the large majority of cases endotracheal anesthesia is adequate and suffices. In certain conditions, however, particularly for pneumonectomy, bronchopleural fistula and lung abscess, endobronchial anesthesia, if properly done, offers the following advantages:

1. The occlusion of the diseased lung prevents sudden flooding of the trachea and the normal lung, even when a large abscess or cyst is ruptured, and thus protects the patient against drowning in his own secretions, and also protects the unaffected lung against contamination.

2. It affords a completely closed system, even in the presence of a bronchopleural fistula, with no loss of anesthetic, which is impossible to attain with any other method.

3. It decreases the number of aspirations during the surgical procedure as the normal lung does not become "wet," thus permitting smoother anesthesia.

4. The completely collapsed lung does not bellow out and encroach upon the surgical field. This decreases the operating time and obviates prolonged and vigorous retractions, which often produce reflex derangements of the cardiovascular and respiratory systems.

5. The surgeon can aspirate the open bronchus before closure so that secretions, blood, or any other foreign material may be removed. He also can close the bronchus without clamping, a procedure which may reduce the incidence of bronchopleural fistulas.

Endobronchial intubation may be performed under direct vision or "blindly." The technical difficulties which have been met by previous authors with the blind technic have been overcome by modifying the tubes and the technic of intubation. This method of intubation is simple and can be easily acquired with a little practice.

One-lung anesthesia has been employed in 216 intrathoracic procedures performed in three large hospitals by 13 different anesthesiologists with gratifying results and at present our surgeons are so convinced of its advantages that they hesitate to operate under any other form of anesthesia.

It should be reemphasized that we are not advocating this technic for all intrathoracic procedures, but merely wish to indicate that in selected cases it may be employed without technical difficulties.

REFERENCES

1. Tuffier, M., and Hallion, C. R.: *Soc. de Biol.* 1896, Vol. 28, pp. 951. Quoted by Gillespie, Noel A.: *Endotracheal Anesthesia*, ed. 2, Madison, The Univ. of Wisconsin Press, 1948, pp. 14.
2. Milton, H.: *Lancet*, 1897, Vol. 1, pp. 872. Quoted by Gillespie, Noel A.: *Endotracheal Anesthesia*, ed. 2, Madison, The Univ. of Wisconsin Press, 1948, pp. 14.
3. Parham, F. W.: *Tr. Southern Surg. & Gyn. A.* 2: 2233, 1898.
4. Fell, G. E.: *Buffalo Med. & Surg. J.* 28: 145, 1887. Quoted by Gillespie, Noel A.: *Endotracheal Anesthesia*, ed. 2, Madison, The Univ. of Wisconsin Press, 1948, p. 14.
5. Matas, R.: *Intra-laryngeal Insufflation*, *J. A. M. A.* 34: 1371, 1468, 1900.
6. Crafoord, C.: *Pulmonary Ventilation and Anesthesia in Major Chest Surgery*, *J. Thoracic Surg.* 9: 237-253 (Feb.) 1940.
7. Light, G. A.; Livingstone, H. M., and Adams, W. E.: *Resume of Anesthetic Experiences in 1050 Intrathoracic Operations*, *Current Research in Anesth. & Analg.* In press.
8. Guedel, A. and Waters, R. M.: *A New Intratracheal Catheter*, *Anesth. & Analg.* 7: 239 (July-Aug.) 1928.
9. Green, N. W.: *The Positive Pressure Method of Artificial Respiration*, *Surg., Gynec. & Obst.* 2: 512, 1906.
10. Janeway, H. H.: *Intratracheal Anesthesia*, *Ann. Surg.* 58: 927 (June 18) 1913.
11. Dorrance, G. M.: *On the Treatment of Traumatic Injuries of the Lungs and Pleura*, *Surg., Gynec. & Obst.* 11: 160 (Aug.) 1910.
12. Gale, J. W., and Waters, R. M.: *Closed Endobronchial Anesthesia in Thoracic Surgery: Preliminary Report*, *Anesth. & Analg.* 11: 283-287 (Nov.-Dec.) 1932.
13. Gale, J. W., and Waters, R. M.: *Closed Endobronchial Anesthesia in Thoracic Surgery: Preliminary Report*, *J. Thoracic Surg.* 1: 432-437 (April) 1932.
14. Magill, I. W.: *Anesthetics in Thoracic Surgery with Special Reference to Lobectomy*, *Brit. J. Anaesth.* 13: 92-109 (April) 1936.
15. Magill, I. W.: *Anesthetics in Thoracic Surgery with Special Reference to Lobectomy*, *Proc. Roy. Soc. Med.* 29: 643-653 (April) 1936.
16. Rovenstine, E. A.: *Anesthesia for Intrathoracic Surgery: Endotracheal and Endobronchial Techniques*, *Surg., Gynec. & Obst.* 63: 325-330 (Sept.) 1936.
17. Crafoord, C.: *On Technique of Pneumonectomy in Man; Critical Survey of Experimental and Clinical Development and Report of Author's Material and Technique*, *Acta. Chir. Scandinav.* (Supp. 54) 81: 1-142, 1938.
18. Crafoord, C.: *Pulmonary Ventilation and Anesthesia in Major Chest Surgery*, *J. Thoracic Surg.* 9: 237-253 (Feb.) 1940.

19. Nosworthy, M. D.: Anesthesia in Chest Surgery with Special Reference to Controlled Respiration and Cyclopropane, *Proc. Roy. Soc. Med.* 34: 479-506 (June) 1941.
20. McCuskey, C. E.: Personal communication to the author.
21. Caine, A.: (Quoted by) Ruth, H. S., Grove, D. D., and Keown, K. K.: Endobronchial Anesthesia by Means of an Improved Endobronchial Airway, *Anesthesiology* 9: 422-429 (July) 1948.
22. Van Hoogstraten, E. G.: Anesthesia In Thoracic Surgery, *South African M. J.* 15: 49-53 (Feb. 8) 1941.
23. Ruth, H. S.; Grove, D. D., and Keown, K. K.: Endobronchial Anesthesia by Means of an Improved Endobronchial Airway, *Anesthesiology* 9: 422-429 (July) 1948.
24. Canuyt, Georges: (Quoted by Labat, G.) *Regional Anesthesia, Its Technic and Clinical Application*, ed. 2, Philadelphia and London, W. B. Saunders, 1930.
25. Bonica, J. J., *Transtacheal Anesthesia for Endotracheal Intubation*, *Anesthesiology* 10: 736-738 (Nov.) 1949.
26. Harken, D. E., and Salsberg, A. M.: *Transtacheal Anesthesia for Bronchoscopy*, *New England J. Med.* 339: 383 (Sept.) 1948.
27. Burstein, C. L.: *Fundamental Considerations in Anesthesia*, ed. 1, New York, The Macmillan Company, 1949, pp. 15-16.
28. Burstein, C. L.: *Treatment of Acute Arrhythmias During Anesthesia by Intravenous Procaine*, *Anesthesiology* 7: 113-121 (March) 1946.
29. Bittrich, N. M., and Powers, W. F.: *Intravenous Procaine in Thoracic Surgery*, *Anesth. & Analg.* 27: 181 (July-Aug.) 1948.
30. Lelf, R. A.: *The Prophylactic Use of Quinine in Thoracic Surgery*, *Anesth. & Analg.* In press.
31. Burstein, C. L., and Alexander, F. A. D.: *Anesthesia for Thoracic Surgery; Management in Army General Hospital Overseas*, *Anesthesiology* 8: 36-52 (Jan.) 1947.
32. Webb, E.: Personal communication to the authors.
33. Collins, V.: Personal communication to the authors.

ANNOUNCEMENTS: AMERICAN COLLEGE OF ANESTHESIOLOGISTS

The American College of Anesthesiologists will hold a written examination on October 20, 1951. Applications and letters of recommendation for this examination must be received by the College no later than July 20, 1951. Such letters should be addressed to The American College of Anesthesiologists, 137 W. 11th Street, New York 11, New York.

As of June 1, 1951, Diplomates of The American Board of Anesthesiology applying for Fellowship in The American College of Anesthesiologists will be required to pay a fee of \$15.00.

As of June 1, 1951, Anesthetists certified by the Royal College of Physicians and Surgeons of Canada applying for Fellowship in The American College of Anesthesiologists will be required to pay a fee of \$15.00.