

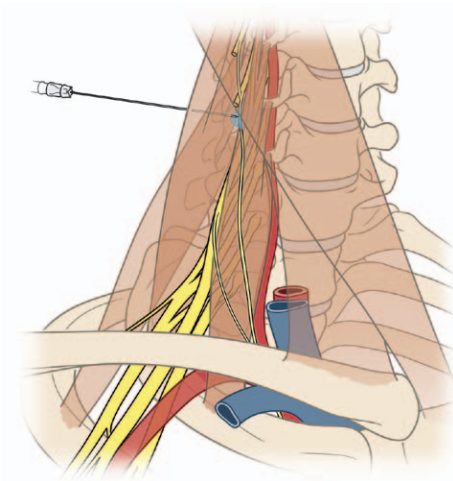
Phrenic Nerve Function after Interscalene Block Revisited

Now, the Long View

ANESTHESIOLOGISTS are very good at immediate observation and intervention. For instance, hemodynamic disorders or inadequate ventilation are apparent to us in real time with customary vigilance and modern monitoring. Less evident are the delayed consequences of our actions. Only relatively recently we have become suspicious that volatile anesthetics might alter immunological function or neurological development months after administration. Similarly, in the realm of plexus and peripheral nerve blocks, we have long understood the immediate risks of injecting local anesthetic into the systemic circulation, which included vessel damage leading to bleeding, neural trauma, and anesthetization of unintended targets. Our focus of care is to avoid these immediate dangers. In contrast, delayed harm after blocks is less subject to our scrutiny. A case series reported in the current issue of *ANESTHESIOLOGY*¹ suggests that our attention should also extend into the long-term time frame regarding phrenic nerve function after interscalene blockade (ISB).

Acute loss of diaphragmatic activity after block of the phrenic nerve during ISB has been recognized as a predictable hazard since the landmark study by Urmey *et al.*² in 1991. Now, Kaufman *et al.*¹ report a series of 14 patients referred to them for treatment of chronic diaphragmatic paralysis that was clearly due to phrenic nerve damage after ISB. Few conclusions can be made from a case series with certainty, but their observations support several preliminary hypotheses.

First, inflammation plays a prominent role in the genesis of persistent phrenic dysfunction after ISB. The authors



“The anatomy of the phrenic nerve may particularly predispose it to damage from the inflammatory consequences of myotoxicity [from injected local anesthetic] ...”

highlight the surgical findings of adhesions, fascial thickening, and vascular changes secondary to inflammation surrounding the nerve. I suspect these extraneural elements are the result of the intense myotoxicity that is predictably induced by local anesthetics after application within muscles or even outside their fascia.³ The anatomy of the phrenic nerve may particularly predispose it to damage from the inflammatory consequences of myotoxicity because it is small and has a lengthy subfascial course on the surface of the anterior scalene muscle. The timing of the onset of phrenic nerve dysfunction is not clear in each case in this series, but at least someone had abnormal function continuously after the block. Because adhesions and scar would take a number of days to form, perhaps direct neural toxicity accounts for early dysfunction while late scar formation and neural entrapment produce the sustained phase of phrenic injury. A high risk of toxicity for neural structures after ISB has been demonstrated in prospective studies that identified brachial plexus damage (*i.e.*, sensory dysfunction a week or more after ISB that is not attributable to other causes) in 4.4–14% of block subjects.^{4–6} Permanent sensory dysfunction is much more rare because of neuronal regrowth and the plentiful redundancy and plasticity of peripheral and central sensory systems, which compensate for damage and provide apparent recovery. As the postgraft results show in the current article, phrenic nerve regeneration is also possible, and there is an evidence of central nervous system plasticity in the phrenic motor system.⁷ These considerations suggest that local anesthetic neurotoxicity alone is insufficient to explain prolonged phrenic dysfunction.

Illustration: Adapted with permission from Neal JM, Rathmell JP: Complications in Regional Anesthesia and Pain Medicine. Philadelphia, Lippincott Williams & Wilkins, 2011, p. 178.

Accepted for publication May 8, 2013. The author is not supported by, nor maintains any financial interest in, any commercial activity that may be associated with the topic of this article.

Copyright © 2013, the American Society of Anesthesiologists, Inc. Lippincott Williams & Wilkins. *Anesthesiology* 2013; 119:250-2

◆ This Editorial View accompanies the following article: Kaufman MR, Elkwood AI, Rose MI, Patel T, Ashinoff R, Fields R, Brown D: Surgical treatment for permanent diaphragm paralysis after interscalene nerve block for shoulder surgery. *ANESTHESIOLOGY* 2013; 119:484–7.

A second hypothesis supported by the data from Kaufman *et al.*¹ is that persistent post-ISB phrenic nerve damage is treatable. Surgical decompression with or without nerve grafting improved patients' condition in 69% of cases. This fact adds importance to optimize discovery of patients with ISB-related injury.

Finally, we can hypothesize that phrenic damage from ISB is not rare. Although an incidence cannot be estimated due to the referral nature of series reported by Kaufman *et al.*,¹ the number of cases indicates that these are not exceptional events. A very recent publication by Pakala *et al.*⁸ reports a series of nine cases, and because these were all derived from one hospital's service, an incidence of approximately 1 per 2,000 ISBs could be calculated. It is important to bear in mind, however, that subjects in both of these studies were only identified if they developed sufficiently severe symptoms to seek help (note that unilateral paralysis is asymptomatic in 55% of subjects),⁹ if they obtained an adequate workup and the correct diagnosis, and if they were successfully logged in to the quality assurance system (Pakala *et al.*⁸) or referred for surgical care (Kaufman *et al.*¹). Therefore, the actual incidence of post-ISB dysfunction is certainly much higher than 1 per 2,000.

Pursuing these speculations will require prospective examination of phrenic nerve performance in subjects with and without ISBs after comparable surgical operations. However, while awaiting this knowledge, it is not premature to consider what measures might be taken to limit the occurrence of this injury. These two published reports do not provide any useful insights into technical features of ISB that may predispose to phrenic damage, since prolonged paresis followed both single shot blocks as well as those with catheters, and various local anesthetics and needle types were used. Numerous technical modifications have been proposed to limit acute phrenic nerve block during ISB, including avoiding catheter infusions, using smaller doses or lower concentrations of local anesthetic, ultrasound guidance, and blocking the plexus at a more distal site where the phrenic nerve diverges away from the brachial plexus.¹⁰ Nonetheless, these technical variations do not eliminate the administration of anesthetic to the phrenic nerve. Furthermore, as noted above, it is not clear that anesthetic action on the phrenic nerve is the source of permanent dysfunction, so limiting the anesthetic that reaches the phrenic nerve may have little effect on development of the adhesions and fascial thickening that may eventually entrap it.

Especially when ISB is used as an analgesic supplement, phrenic damage even at a rate as low as 1 per 1,000 requires us to ask whether the increment of improved analgesia provided by ISB, and its relatively brief duration, justifies this level of risk. One certain way to eliminate anesthetic-induced phrenic damage is to avoid injecting into the neck at all. This has the added appeal of eliminating the opportunity for other catastrophic events, including puncturing

the pleura, injecting into the carotid or vertebral arteries, or injecting into the spinal nerves or dorsal root ganglia with extension into the spinal cord. As a model, the extensive studies on knee surgery by Kehlet *et al.*¹¹ have shown that distal (operative site) infiltration of local anesthetic, wed to multimodal systemic analgesia without opioids plus general approaches to enhance recovery, provides analgesia suitable for early ambulation and discharge. There are initial indications that suprascapular nerve and axillary nerve blocks^{12,13} may similarly serve as components of an integrated approach for shoulder surgery. If so, such peripheral application of local anesthetic would substitute a more innocuous hunting ground to achieve our injection goals, and spare patients from our incursions into the anatomic tiger country of their neck.

Quinn H. Hogan, M.D., Department of Anesthesiology, Medical College of Wisconsin, Milwaukee, Wisconsin. qhogan@mcw.edu

References

1. Kaufman MR, Elkwood AI, Rose MI, Patel T, Ashinoff R, Fields R, Brown D: Surgical treatment of permanent diaphragm paralysis after interscalene nerve block for shoulder surgery. *ANESTHESIOLOGY* 2013; 119:484–7
2. Urmey WF, Talts KH, Sharrock NE: One hundred percent incidence of hemidiaphragmatic paresis associated with interscalene brachial plexus anesthesia as diagnosed by ultrasonography. *Anesth Analg* 1991; 72:498–3
3. Hogan Q: Myotoxicity, Complications in Regional Anesthesia and Pain Medicine, 2nd edition. Edited by Neal J, Rathmell J. Philadelphia, Lippincott Williams & Wilkins, 2013, pp 170–6
4. Candido KD, Sukhani R, Doty R Jr, Nader A, Kendall MC, Yaghmour E, Kataria TC, McCarthy R: Neurologic sequelae after interscalene brachial plexus block for shoulder/upper arm surgery: The association of patient, anesthetic, and surgical factors to the incidence and clinical course. *Anesth Analg* 2005; 100:1489–95
5. Borgeat A, Ekatothramis G, Kalberer F, Benz C: Acute and nonacute complications associated with interscalene block and shoulder surgery: A prospective study. *ANESTHESIOLOGY* 2001; 95:875–80
6. Borgeat A, Dullenkopf A, Ekatothramis G, Nagy I: Evaluation of the lateral modified approach for continuous interscalene block after shoulder surgery. *ANESTHESIOLOGY* 2003; 99:436–42
7. Beisteiner R, Höllinger I, Rath J, Wurnig M, Hilbert M, Klinger N, Geissler A, Fischmeister F, Wöber C, Klösch G, Milesi H, Grisold W, Auff E, Schmidhammer R: New type of cortical neuroplasticity after nerve repair in brachial plexus lesions. *Arch Neurol* 2011; 68:1467–70
8. Pakala SR, Beckman JD, Lyman S, Zayas VM: Cervical spine disease is a risk factor for persistent phrenic nerve paresis following interscalene nerve block. *Reg Anesth Pain Med* 2013; 38:239–42
9. Piehler JM, Pairolo PC, Gracey DR, Bernatz PE: Unexplained diaphragmatic paralysis: A harbinger of malignant disease? *J Thorac Cardiovasc Surg* 1982; 84:861–4
10. Verelst P, van Zundert A: Respiratory impact of analgesic strategies for shoulder surgery. *Reg Anesth Pain Med* 2013; 38:50–3
11. Kehlet H, Andersen LØ: Local infiltration analgesia in joint replacement: The evidence and recommendations for clinical practice. *Acta Anaesthesiol Scand* 2011; 55:778–84
12. Checcucci G, Allegra A, Bigazzi P, Gianesello L, Ceruso M, Gritti G: A new technique for regional anesthesia for

arthroscopic shoulder surgery based on a suprascapular nerve block and an axillary nerve block: An evaluation of the first results. *Arthroscopy* 2008; 24:689–96

13. Price DJ: The shoulder block: A new alternative to interscalene brachial plexus blockade for the control of postoperative shoulder pain. *Anaesth Intensive Care* 2007; 35:575–81

ANESTHESIOLOGY REFLECTIONS FROM THE WOOD LIBRARY-MUSEUM

Opening Medallion from Portugal's Museu de Anestesiologia



As part of its opening festivities, Portugal's Museum of Anesthesiology issued this attractive medallion. Depicting a Morton Ether Inhaler, the obverse (*left*) reads: "MUSEU DE ANESTESIOLOGIA/PORTUGAL." Note the opening artistically designed into the inhaler for peering through the "broken globe" at the ether-laden sponge inside. The medallion's reverse (*right*) reads: "INAUGURADO EM/19 OUTUBRO 1996/GALAMARES/SINTRA" (Portuguese for: "Inaugurated on 19 October 1996, Galamares, Sintra"). *ANESTHESIOLOGY* readers who are touring Lisbon are certainly encouraged to visit Portugal's Museum of Anesthesiology. (Copyright © the American Society of Anesthesiologists, Inc.)

George S. Bause, M.D., M.P.H., Honorary Curator, ASA's Wood Library-Museum of Anesthesiology, Park Ridge, Illinois, and Clinical Associate Professor, Case Western Reserve University, Cleveland, Ohio. UJYC@aol.com.