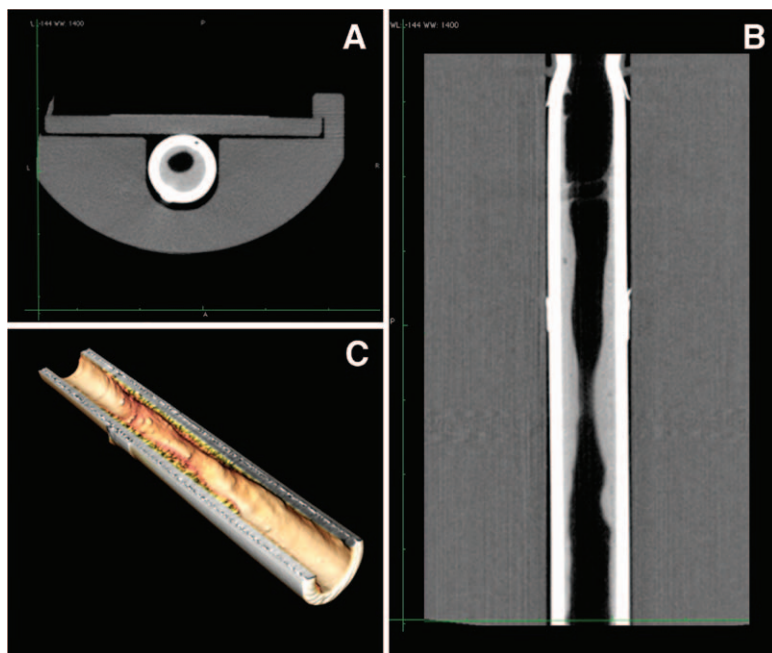


Hugh C. Hemmings, Jr., M.D., Ph.D., Editor
 Alan Jay Schwartz, M.D., M.S. Ed., Associate Editor

Use of High-definition Computed Tomography to Assess Endotracheal Tube Luminal Narrowing after Mechanical Ventilation

Riccardo Pincioli, M.D., Cristina Mietto, M.D., Lorenzo Berra, M.D.*

* Department of Anesthesia, Critical Care and Pain Medicine, Massachusetts General Hospital, Harvard Medical School, Boston, Massachusetts. lberra@partners.org



PRODUCTION and clearance of mucus are key mechanisms in the physiology of the respiratory system. Their regulation is often impaired in intubated patients who show superabundant production and inefficient clearance. As a result, a variably thick layer of mucus ultimately adheres to the inner surface of the endotracheal tube (ETT), reducing its original cross-sectional area. This luminal narrowing significantly impacts airflow resistance that varies inversely to the fourth power of the conduit's radius according to the Poiseuille's equation ($\Delta P = 8 \mu L Q (\pi r^4)^{-1}$). Patient's work of breathing may consequently increase.¹ However, the importance of ETT progressive luminal narrowing during mechanical ventilation is still widely unrecognized, and currently used suctioning systems are unable to maintain the ETT function.²

To study the magnitude of this adverse event, we developed an innovative approach to visualize the accretion of mucus in extubated ETTs

with high-definition computed tomography. The ETT is collected on extubation and sealed. Scanning is performed on a positron emission tomography-computed tomography scanner (Siemens, Malvern, PA), with resolution down to 15 μm . Multiplanar images of the ETT, particularly its lung end (terminal 10 cm), show the reduced inner diameter on coronal (fig. A) and transverse (fig. B) sections. 3D-volume rendering reconstructions of the lumen can also be obtained (fig. C). This technique precisely visualizes the morphology of the lumen and quantifies the existing amount of mucus. Measurements such as volume of secretions/air or minimum cross-sectional area can be collected, all of which may have exerted significant effects *in vivo*. High-definition computed tomography may also be useful to study the efficacy of devices for the maintenance of the ETT function.³

References

1. Shah C, Kollef MH: Endotracheal tube intraluminal volume loss among mechanically ventilated patients. *Crit Care Med* 2004; 32:120–5
2. Boqué MC, Gualis B, Sandiumenge A, Rello J: Endotracheal tube intraluminal diameter narrowing after mechanical ventilation: Use of acoustic reflectometry. *Intensive Care Med* 2004; 30:2204–9
3. Berra L, Coppadoro A, Bittner EA, Kolobow T, Laquerriere P, Pohlmann JR, Bramati S, Moss J, Pesenti A: A clinical assessment of the Mucus Shaver: A device to keep the endotracheal tube free from secretions. *Crit Care Med* 2012; 40:119–24

Financial support: endOclear, LLC. (Petoskey, MI) covered the costs of high-definition computed tomography and provided study supplies. Copyright © 2013, the American Society of Anesthesiologists, Inc. Lippincott Williams & Wilkins. *Anesthesiology* 2013; 119:202