

Effective Volume of Ropivacaine 0.75% through a Catheter Required for Interscalene Brachial Plexus Blockade

Catherine Vandepitte, M.D.,* Philippe Gautier, M. D.,† Daquan Xu, M. D.,‡ Emine A. Salviz, M. D.,§ Admir Hadzic, M. D., Ph. D.¶

ABSTRACT

Background: Ultrasound guidance during peripheral nerve blocks has allowed for reduction in dose and volume of local anesthetic required to accomplish successful blockade using multiple injections through a needle. The authors undertook this study to determine the minimal effective volume required to accomplish successful interscalene brachial plexus block (ISB) through the catheter.

Methods: After obtaining institutional ethics committee approval and written informed consent, patients aged 18–75 yr and scheduled for arthroscopic shoulder surgery under ISB were enrolled. All patients using a step-up/step-down method and the starting dose of 15 ml of 0.75% ropivacaine received an ultrasound-guided ISB catheter. The injection volume was increased or decreased by 1 ml in case of block failure or block success, respectively.

Results: The authors found that the proportion of patients with successful blockade increased sharply from approximately 57% at 6 ml to 100% by 7 ml, indicating that a small increase in volume of ropivacaine 0.75% markedly affects the success rate. A total of 12 ISB with injection volume less than 7 ml resulted in successful anesthesia within 30 min, yielding an ED₉₅ of 7 ml (95% CI 6.8–7.2) ropivacaine 0.75%. For the group as a whole, the median (min–max) sensory block onset time was 5 (5–20) min, the median (min–max) motor blocks for the biceps and the deltoid muscles were 7.5

What We Already Know about This Topic

- Ultrasound guidance for peripheral nerve blocks reduces the volume necessary for anesthesia from injection through the needle, but whether a similar effect occurs from injection through a catheter inserted under ultrasound guidance is not known

What This Article Tells Us That Is New

- In a study of 29 patients undergoing interscalene brachial plexus block with ultrasound guidance, the ED₉₅ for adequate anesthesia from the initial injection was 7 ml

(5–15) min and 10 (5–15) min, respectively. The median (min–max) block duration was 8.9 (3–15) h.

Conclusions: An injection of a minimum of 7 ml of ropivacaine 0.75% through the catheter is required for success rate and timely onset of surgical anesthesia with ISB.

ULTRASOUND guidance during peripheral nerve blocks has allowed for reduction in dose and volume of local anesthetic (LA) required to accomplish successful blockade.^{1–4} For instance, as little as 5 ml of ropivacaine 0.75%, or 1.7 ml for each of three trunks of the brachial plexus (superior, middle, and inferior), may be sufficient to accomplish successful ultrasound-guided interscalene brachial plexus block (ISB) through three separate injections.¹ However, no data are available on the volume of LA required to accomplish successful ISB anesthesia with an injection through the catheter. This is important because catheters are flexible, cannot be repositioned for multiple injections, and may result in a different spread of LA because of resistance to injection caused by their greater length and smaller diameter compared with commonly used nerve block needles. We undertook this study to determine the minimal effective volume required to accomplish successful ISB through the catheter.

Materials and Methods

After obtaining institutional ethics committee approval (Brussels, Belgium) and written informed consent, 29 American Society of Anesthesiologists physical status I–III patients, aged between 18 and 75 yr and scheduled for arthroscopic shoulder surgery under ISB, were prospectively

* Anesthesiologist, Department of Anesthesiology, Catholic University of Leuven, Leuven, Belgium. † Anesthesiologist, Department of Anesthesiology, Clinique Ste Anne-St Remi, Brussels, Belgium. ‡ Research Associate, § Research Associate, Anesthesiologist, ¶ Professor, Anesthesiologist, Department of Anesthesiology, St. Luke's-Roosevelt Hospital Center, Columbia University College of Physicians and Surgeons, New York, New York.

Received from the Clinique Ste Anne-St Rémi, Brussels, Belgium. Submitted for publication April 3, 2012. Accepted for publication December 17, 2012. Support was provided solely from institutional and/or departmental sources.

Address correspondence to Dr. Gautier: Department of Anesthesiology, Clinique Ste Anne-St Remi, Boulevard J. Graindor 66, 1070-Brussels, Belgium. p.gautier@skynet.be. Information on purchasing reprints may be found at www.anesthesiology.org or on the masthead page at the beginning of this issue. ANESTHESIOLOGY's articles are made freely accessible to all readers, for personal use only, 6 months from the cover date of the issue.

Copyright © 2013, the American Society of Anesthesiologists, Inc. Lippincott Williams & Wilkins. Anesthesiology 2013; 118:863–7

enrolled. Patients who presented with contraindications to interscalene block and/or were pregnant were excluded. The starting dose of 15 ml of 0.75% ropivacaine was chosen based on our previously published data.¹ Using a previously validated step-up/step-down method, the injection volume used for consecutive patients was determined by the outcome of the preceding block. In the case of block failure, the injection volume was increased by 1 ml; conversely, for block success, the volume was decreased by 1 ml.^{1,5}

Intravenous access was established in the nonoperative upper limb, and standard monitoring such as noninvasive blood pressure, electrocardiography, and pulse oximetry were applied. Patients were premedicated with 2 mg intravenous midazolam. After patient positioning and aseptic preparation of the skin, all blocks were performed preoperatively by two anesthesiologists with significant experience in ultrasound-guided peripheral nerve blocks (Dr. Gautier and Dr. Vandepitte).

Needle placement and injection of LA were guided by both ultrasound (Aplio XG, Toshiba, Inc., Tokyo, Japan; with a 38-mm 12 MHz linear array transducer) and nerve stimulator (HNS 12, B. Braun Melsungen AG, Melsungen, Germany). The nerve stimulator was set at 0.5 mA (0.1 ms) and used as an additional monitor for the needle placement. After the brachial plexus was identified on the ultrasound image, an 18-gauge Tuohy style needle (Contiplex[®], B. Braun Medical, Germany) was inserted at approximately 45 degrees using an out-of-plane technique and advanced to enter the interscalene space between the superior and middle trunks of the ISB. Once between the anterior and middle scalene muscles, the needle was advanced approximately 2–3 cm into the interscalene groove at the level between C5 and C6. The catheter was inserted 1 cm beyond the needle tip (approximately 4–6 cm from the skin). The goal was to insert the catheter deep enough so as to prevent its inadvertent dislodgement.

Motor response was not deliberately sought during needle insertion; however, when obtained, the current was decreased until the motor response was not seen or palpable; when this occurred below 0.2 mA (0.1 ms), the needle was repositioned to avoid intraneural catheter placement. A flexible catheter (Contiplex[®], B. Braun Medical) was inserted 1 cm beyond the tip of the needle. Proper position of the catheter was confirmed by an injection of 1 ml of 0.75% ropivacaine. Catheter placement was considered successful when the spread of LA occurred within the perineural interscalene space. After successful catheter placement, the needle was withdrawn and the catheter was secured to the skin with the Lock-it Plus securing system (Smiths Medical ASD, Inc., Keene, NH). When the distribution of LA was deemed inadequate, the catheter was replaced using the identical procedure. Intraoperative sedation consisted of intravenous infusion of propofol (40–50 µg/kg/min) titrated to mild sleep; opioids were not used intraoperatively.

Block start time (LA injection), duration of surgical procedure, and time to first analgesic requirement (block duration) *via* patient-controlled analgesia pump through the catheter (Visual Analogue Score > 3) were recorded.

Block Assessment

An examiner blinded to the volume of injectate evaluated the presence of motor and sensory blockade in the territory of C5 and C6. Block assessment was performed at 5-min intervals up to 30 min after completion of the last injection. Simultaneous sensory and motor functions in the limb were used for comparison purposes. The deltoid area was chosen for testing the sensory block because the axillary nerve territory was considered the most relevant to the surgical model used. Sensory function was assessed by the pinprick (paper clip) and scored as present or absent.

Similarly, motor function was assessed by testing abduction of the arm (axillary nerve) and flexion of the forearm (musculocutaneous nerve). A modified Bromage scale was used:⁶

Score of 4: Full power

Score of 3: Reduced power but able to lift the arm against resistance

Score of 2: Moves relevant muscle group against gravity but unable to lift the arm against resistance

Score of 1: Perceptible muscle contraction but unable to lift the arm purposely

Score of 0: No movement in relevant muscle group

For a block to be successful, a sensory block (pinprick test) in the C5 to C7 region and motor block (motor score ≤ 2) of biceps (arm flexion at the elbow) and deltoid (arm abduction) had to be present within 30 min after injection. In case of block failure within 30 min, additional boluses of 10 ml of ropivacaine 0.75% were administered through the catheter. All patients were then taken to the operating room for their planned surgery. Before the surgery, infiltration was used with 1% lidocaine for sites for trochars insertion; thereafter, LAs were not used. Patients who had inadequate anesthesia on surgical incision were to receive general anesthesia for completion of surgery. Duration of sensory blockade was defined as time to first analgesic request for pain bolus of LA *via* catheter.

Perioperative Period

Surgery was conducted under ISB as a sole technique. Propofol infusion was titrated to light sleep equivalent to the Ramsey scale of five patients exhibiting a sluggish response to light glabellar tap or loud auditory stimulus.⁷

In case of failed block after the observation period, the block was supplemented up to 15 ml with ropivacaine 0.25%. All patients received 1 g of intravenous paracetamol and 75 mg of diclofenac sodium at the end of surgery. Tramadol 50 mg was prescribed as rescue analgesia after block regression. Postoperative analgesia consisted of 1 g of oral

paracetamol every 6 h and 75 mg of intravenous diclofenac sodium twice daily for 48 h after surgery.

Study-stopping Rules and Sample Size

Successful block at 30 min in at least 80% of patients was considered when estimating the sample size needed to assess the volume of ropivacaine 0.75% required for a predictable success rate for ISB. On the basis of previous nonprobability sequential dosing used by studies with similar binary outcomes,^{1,5} we estimated that a minimum of 10 independent negative–positive up-and-down deflections were required for this study. It was agreed by consensus that reducing the dose below 4 ml was not of clinical importance. Our intention was to stop the study on accomplishing five successful consecutive blocks with the minimal volume of LA that would result in ISB anesthesia.

Statistics

Continuous variables are presented as mean \pm SD; categorical and nominal variables as n%. Database management and analyses were performed using the Statistical Package for the Social Sciences (IBM SPSS Statistics 20.0, Chicago, IL, 2011). Effective volume of ropivacaine 0.75% through a catheter for ISB was determined using the up-and-down method previously used by dosing studies with similar binary outcomes^{1,5} and further evaluated with consideration of the modified continual reassessment method.⁸

Results

Demographic characteristics of the patients are presented in table 1. As seen in figure 1, the proportion of patients with successful blockade increased sharply from approximately 57% at 6 ml to 100% by 7 ml, indicating that a small increase in volume of ropivacaine 0.75% markedly affects the success rate. A total of 12 ISB with injection volume less than 7 ml resulted in successful anesthesia within 30 min, yielding an ED₉₅ of 7.0 ml (95% CI 6.8–7.2) ropivacaine 0.75%. Moreover, with an additional “top-up” bolus of ropivacaine of 10 ml, all blocks were ultimately successful as sole surgical anesthetic for arthroscopic shoulder surgeries such as rotator cuff, bankart, acromioplasty, biceps rupture, and fractures.

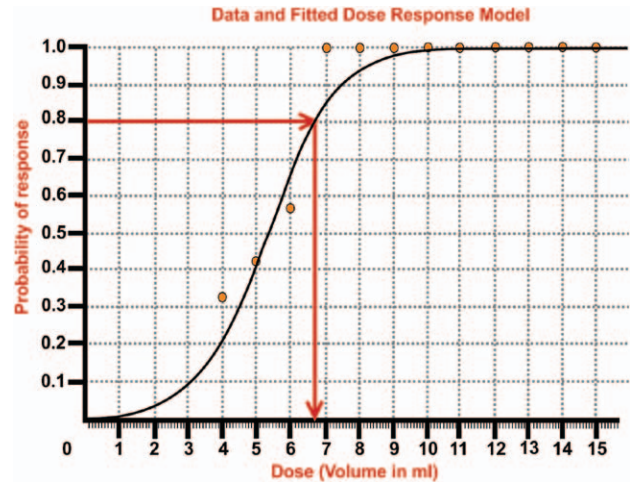


Fig. 1. Ropivacaine 0.75% dose (volume in milliliters) and interscalene brachial plexus block success correlation. (The red lines represent that 6.75 ml of ropivacaine 0.75% administered in an ultrasound-guided interscalene brachial plexus block through the catheter results in successful blockade in 80% of patients.)

For our dose-finding study, the “right-hand portion” of the dose–response curve increased sharply from 57% to 100% between 6 and 7 ml of ropivacaine 0.75% and remained at 100% for the remaining dose volumes (fig. 1). Thus, the best solution (informed estimate) for the right-hand portion of the dose–response model was to estimate sufficient coverage of patients between 6 and 7 ml. That coverage was deemed to be at least 80% of patients for the sample size estimate, and its calculated value (6.75 ml) was based on the log-likelihood function for binomial outcomes for k doses with r_i responses out of n_i patients at each dose (fig. 1). However, because target optimal doses can be underestimated due to patient variability, sequential protocol, and discreteness of the data set, we concluded that a minimum of 7 ml of ropivacaine 0.75% is required through the catheter for predictable success rate for interscalene brachial plexus blockade.

For the group as a whole, the median (min–max) sensory block onset time was 5 (5–20) min and the median (min–max) motor block for the biceps and the deltoid muscles were 7.5 (5–15) min and 10 (5–15) min, respectively (table 1).

Table 1. Patient Demographics, Operative Data and Efficiency Measures (n = 29)

Age, yr (mean \pm SD)	61 \pm 12
Gender, n (female/male)	13/16
Weight, kg (mean \pm SD)	76 \pm 13
Height, cm (mean \pm SD)	165 \pm 9
American Society of Anesthesiologists physical status:I/II/III	12/10/7
Duration of surgery, minutes (mean \pm SD)	64 \pm 28
Sensory block onset time, minutes:median (min–max)	5 (5–20)
Motor block for the biceps muscle, minutes:median (min–max)	7.5 (5–15)
Motor block for the deltoid muscle, minutes:median (min–max)	10 (5–15)
Block duration (time to first analgesic request), hours: median (min–max)	8.9 (3–15)

The median (min–max) block duration was 8.9 (3–15) h (table 1). Volume for successful block at 30 min did not correlate with duration of analgesia (Pearson $r = 0.345$, $P = 0.126$).

Discussion

Several investigators have reported the minimal volume of LA required to anesthetize the brachial plexus with injection of multiple aliquots of LA through a block needle.^{1–5,9} However, no study to date has evaluated the minimal volume of LA required for ISB when injected through the catheter. This is important because catheter placement as opposed to needle cannot be readjusted after initial placement and injection. In addition, resistance to injection of LA and, therefore, the ability of the LA to spread in the tissues may vary from that of the needle because needles are shorter, more rigid than catheters, and are typically repositioned several times during an injection of LA to accomplish adequate spread as monitored by ultrasound. Hence, the information on volume of LA required to anesthetize the brachial plexus through the needle may not be applicable to the anesthesia accomplished through the catheter. Although with an indwelling catheter the drug can be titrated to the effect, not knowing the minimally effective volume may result in delays until surgical anesthesia is eventually reached with incremental dosing. In addition, ISB is typically combined with general anesthesia or sedation intraoperatively; therefore, patient feedback is not available while titrating the drug to the full analgesic effect.

We found that 6.75 ml of ropivacaine 0.75% administered in an ultrasound-guided ISB through the catheter results in successful blockade. Furthermore, it is interesting to note that the proportion of patients with successful blockade increases sharply from approximately 57% at 6 ml to 100% by 7 ml. This suggests that volume of LA plays an important role in ensuring adequate spread of the injectate

required for successful block. Although somewhat smaller volumes of LA have been reported to be adequate when using multiple injections through needles,^{1,3} our study suggests that boluses of less than 7 ml through the catheter may not result in timely onset of complete brachial plexus anesthesia.

Our study has several possible limitations. First, a different technique or position of catheter placement may have yielded different volume requirements or spread of LA for successful block. However, it is reasonable to assume that placement of the catheters in this study was adequate given that after a top-up, all patients had successful surgical anesthesia with ISB as sole anesthetic; regardless, our findings may apply only to an ideally placed interscalene catheter and may not be generalizable. Second, the logistics of the operating room flow prevented evaluation of block success beyond 30 min. Some of the blocks that were deemed as failures could have met the criteria for successful blocks, if we continued evaluations. However, the cutoff point of 30 min that we used in our study is commonly used as a methodological criterion in the literature.^{1,10} Third, as shown in figure 2, successful blocks were obtained in the first 10 patients who received volumes of 7 ml or greater. Thereafter, we were not able to meet the protocol requirement of five successful blocks in up to 29 patients enrolled. Although successful blocks in the first 10 patients were obtained at volumes as low as 5 ml, the volume at which the blocks were uniformly successful was 7 ml or greater (Fisher exact $P = 0.003$). Moreover, because it did not appear that the up-and-down trend would stabilize even with continuous enrollment of patients (fig. 2), the study was stopped to avoid unnecessary risk for failed blocks in additional patients enrolled. Instead, we deduced from the cross-tabulation data that the minimum volume for successful ISB is likely to be in the vicinity of 7 ml (fig. 1). Finally, our results may not be misinterpreted to imply the recommendations for the minimum volumes required for postoperative analgesia.

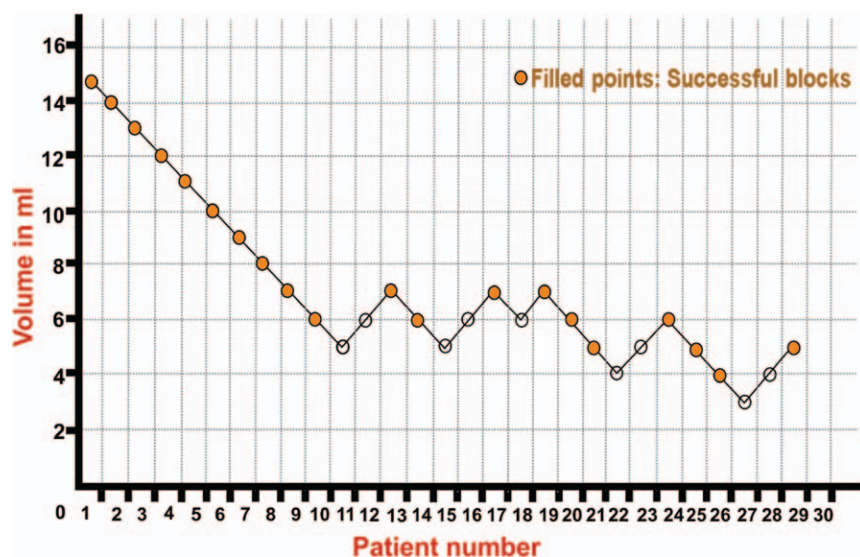


Fig. 2. Step-up/step-down sequence with dotted line indicating interscalene brachial plexus block success with different ropivacaine 0.75% doses (volumes in milliliters).


In conclusion, under conditions of our study, an injection of a minimum of 7 ml of ropivacaine 0.75% through the catheter is required for success rate and timely onset of surgical anesthesia with ISB.

References

1. Gautier P, Vandepitte C, Ramquet C, DeCoopman M, Xu D, Hadzic A: The minimum effective anesthetic volume of 0.75% ropivacaine in ultrasound-guided interscalene brachial plexus block. *Anesth Analg* 2011; 113:951–5
2. McNaught A, Shastri U, Carmichael N, Awad IT, Columb M, Cheung J, Holtby RM, McCartney CJ: Ultrasound reduces the minimum effective local anaesthetic volume compared with peripheral nerve stimulation for interscalene block. *Br J Anaesth* 2011; 106:124–30
3. Riazi S, Carmichael N, Awad I, Holtby RM, McCartney CJ: Effect of local anaesthetic volume (20 vs 5 ml) on the efficacy and respiratory consequences of ultrasound-guided interscalene brachial plexus block. *Br J Anaesth* 2008; 101:549–56
4. Sinha SK, Abrams JH, Barnett JT, Muller JG, Lahiri B, Bernstein BA, Weller RS: Decreasing the local anesthetic volume from 20 to 10 mL for ultrasound-guided interscalene block at the cricoid level does not reduce the incidence of hemidiaphragmatic paresis. *Reg Anesth Pain Med* 2011; 36:17–20
5. O'Donnell BD, Iohom G: An estimation of the minimum effective anesthetic volume of 2% lidocaine in ultrasound-guided axillary brachial plexus block. *Anesthesiology* 2009; 111:25–9
6. O'Donnell BD, Ryan H, O'Sullivan O, Iohom G: Ultrasound-guided axillary brachial plexus block with 20 milliliters local anesthetic mixture *versus* general anesthesia for upper limb trauma surgery: An observer-blinded, prospective, randomized, controlled trial. *Anesth Analg* 2009; 109:279–83
7. Ramsay MA, Savege TM, Simpson BR, Goodwin R: Controlled sedation with alphaxalone-alphadolone. *Br Med J* 1974; 2:656–9
8. Piantadosi S, Fisher JD, Grossman S: Practical implementation of a modified continual reassessment method for dose-finding trials. *Cancer Chemother Pharmacol* 1998; 41:429–36
9. Tran de QH, Dugani S, Dyachenko A, Correa JA, Finlayson RJ: Minimum effective volume of lidocaine for ultrasound-guided infraclavicular block. *Reg Anesth Pain Med* 2011; 36:190–4
10. Chan VW, Perlas A, McCartney CJ, Brull R, Xu D, Abbas S: Ultrasound guidance improves success rate of axillary brachial plexus block. *Can J Anaesth* 2007; 54:176–82

ANESTHESIOLOGY REFLECTIONS FROM THE WOOD LIBRARY-MUSEUM

The Poetical Works of Oliver Wendell Holmes with Illustrations



A lovely cover (left) graces the Riverside Press' 1890 printing from Cambridge, Massachusetts, of *The Poetical Works of Oliver Wendell Holmes with Illustrations*. The senior O. W. Holmes (right) was a celebrated author and physician. Not surprisingly, "Old Ironsides" is the first of three poems featured on page 1. Originally published in the *Boston Daily Advertiser*, that poem is credited with rescuing a "veteran frigate of the War of 1812," the USS *Constitution* from the scrapyard. Still commissioned to this day, the *Constitution* is berthed in the Charlestown Navy Yard of Boston National Historical Park. (Copyright © the American Society of Anesthesiologists, Inc.)

George S. Bause, M.D., M.P.H., Honorary Curator, ASA's Wood Library-Museum of Anesthesiology, Park Ridge, Illinois, and Clinical Associate Professor, Case Western Reserve University, Cleveland, Ohio. UJYC@aol.com.