



### Situation Awareness in Anesthesia: Concept and Research (Review Article)

729

Situation awareness is important for accurate decision making and optimal performance, especially in complex and dynamic environments like the operating room. Its hierarchical levels are perception, comprehension, and projection.

### Efficiency, Efficacy, and Safety of EZ-Blocker Compared to Left-sided Double-lumen Tube for One-lung Ventilation

550

In a randomized, single blinded study of 100 patients, a new bronchial blocker caused less injury and sore throat than a left-sided double-lumen tube when used for one-lung ventilation. See the accompanying Editorial View on page 490

### Inspiratory Stridor after Tracheal Intubation with a Microcuff® Tracheal Tube in Three Young Infants (Case Report)

748

Three cases of postextubation airway swelling in young infants are reported. The cuffs of the tracheal tubes used were designed to seal the pediatric upper airway at reduced pressures. See the accompanying Editorial View on page 500

### Perioperative Therapeutic Plasmapheresis (Clinical Concepts and Commentary)

722

Challenges for the anesthesiologist posed by perioperative plasmapheresis are reviewed, including changes in intravascular volume, serum electrolytes, the coagulation cascade, and the pharmacokinetics of drugs administered perioperatively.

### Pain-associated Respiratory Failure in Chest Trauma (Case Scenario)

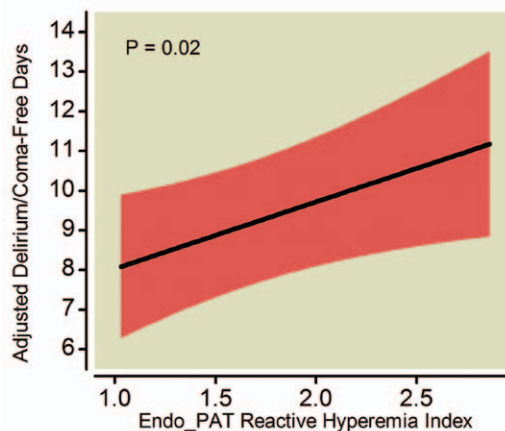
701

A case of a patient on antiplatelet medications with chest trauma-induced severe respiratory distress is presented. The risks and benefits of neuraxial analgesia in patients presenting with rib fracture pain-related respiratory failure are reviewed.

### Association between Endothelial Dysfunction and Acute Brain Dysfunction during Critical Illness

631

Endothelial function is impaired in critically ill patients. Because endothelial dysfunction contributes to altered cerebral blood flow and blood brain barrier permeability, it could lead to acute brain dysfunction during critical illness. One hundred forty-seven medical and surgical intensive care unit patients participated in this prospective cohort study. Endothelial function was assessed at enrollment using peripheral artery tonometry to determine reactive hyperemia index.



After correcting for confounding variables, lower reactive hyperemia index, which reflected worse systemic endothelial function, was independently associated with fewer delirium/coma-free days. This suggests endothelial dysfunction may play a role in the pathogenesis of acute brain dysfunction during critical illness. See the accompanying Editorial View on page 494

### Epidural versus Continuous Preperitoneal Analgesia during Fast-track Open Colorectal Surgery: A Randomized Controlled Trial

622

Effective postoperative analgesia allowing early mobilization is necessary for Enhanced Recovery After Surgery programs. Although thoracic epidural analgesia is considered an important component of these programs for patients undergoing open abdominal surgery, continuous wound infiltration with local anesthetics has been proposed as an alternative. This prospective, randomized, double-blind controlled trial compared 48 h of continuous wound infiltration and thoracic epidural analgesia in 50 patients after undergoing open colorectal surgery and managed postoperatively with a multimodal enhanced rehabilitation program. The median postoperative dynamic pain scores in the epidural analgesia group were lower than those in the continuous wound infiltration group until they were discharged from the hospital. Patients in the epidural analgesia group also had quicker functional recovery and shorter hospital stays.

### Role of Meningeal Mast Cells in Intrathecal Morphine-evoked Granuloma Formation

664

Intrathecal infusion of equianalgesic concentrations of morphine, hydromorphone, or methadone, but not fentanyl, results in intrathecal granuloma formation in dogs. This aseptic collection of inflammatory cells arising from the dura-arachnoid layer of the meninges adjacent to the infusion catheter tip might develop by a local drug effect on a meningeal target. Cromolyn, which prevents mast cell degranulation, prevented or reduced morphine-induced canine dural histamine release *in vitro*, abdominal wheal/flare formation after subcutaneous injection in dogs, and intrathecal granuloma formation after intrathecal administration in dogs, but naloxone (*in vitro*) and naltrexone (*in vivo*) did not. The pharmacology of cutaneous/dural mast cell degranulation and intrathecal granulomas is similar, suggesting intrathecal morphine-evoked granuloma formation is not a simple opioid receptor-mediated effect.