

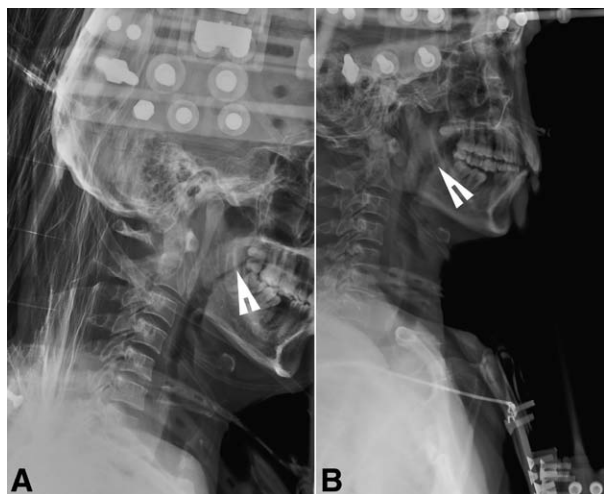
Hugh C. Hemmings, Jr., M.D., Ph.D., Editor
Alan Jay Schwartz, M.D., M.S. Ed., Associate Editor

Excessive Occipital-C1 Flexion via Halo Vest Immobilization

Oropharyngeal Space Reduction Leading to Difficult Airway Establishment

Kenneth N. Hiller, M.D.

Department of Anesthesiology, The University of Texas Medical School at Houston, Houston, Texas.
 kenneth.n.hiller@uth.tmc.edu



THIS image demonstrates a complex C1 fracture reduced *via* excessive occipital-C1 flexion *via* halo vest immobilization (fig. A). Note arrow indicating slit-like oropharyngeal space originating below the soft palate. Halo vest immobilization occurred 30 min before emergent surgery for treatment of open femur fractures after a 15-foot fall. Shortly thereafter, the patient became tachypneic, dyspneic, and required supplemental oxygen to maintain oxygen saturations in the mid 90% range. Heart rate, blood pressure, skin examination, and A-a gradient were normal.

General anesthesia with laryngeal mask-assisted endotracheal tube placement was planned. Upon insertion, the laryngeal mask developed an extremely flexed position, producing clear bilateral breath sounds but minimal chest excursion with consistently increased end-tidal carbon dioxide. Routine measures to alleviate upper airway obstruction were ineffective. Fiberoptic examination revealed proximal laryngeal mask

angulation that encumbered bronchoscope advancement and revealed only soft tissue. Oxygen saturations remained 100% throughout. Given the brief predicted surgical time and otherwise normal vital signs, the laryngeal mask was left *in situ* for surgical duration. Postoperative halo vest immobilization realignment (fig. B) resulted in rapid dyspnea resolution with normal respiratory mechanics and ventilation. Note arrow indicating the expanded oropharyngeal space below the soft palate.

Intraoperative surgical fusion or halo vest immobilization has resulted in upper airway obstruction and difficulty in airway reestablishment.^{1,2} This case, however, illustrates the importance of preoperative halo vest immobilization and oropharyngeal space assessment before definitive airway management. Anesthetic management considerations may include preoperative halo vest repositioning, awake fiberoptic intubation, and postoperative intubation for 2–3 days.³

The author thanks Carin A. Hagberg, M.D. (Joseph C. Gabel Professor and Chair of the Department of Anesthesiology, The University of Texas Medical School at Houston, Houston, Texas), for graciously reviewing the submission.

References

1. Szabo MD, Crosby G: Excessive atlanto-occipital flexion as a cause of complete airway obstruction following anterior cervical spine fusion. *J Clin Anesth* 1992; 4:328–30
2. Yoshida M, Neo M, Fujibayashi S, Nakamura T: Upper-airway obstruction after short posterior occipitocervical fusion in a flexed position. *Spine* 2007; 32:E267–70
3. Lee YH, Hsieh PF, Huang HH, Chan KC: Upper airway obstruction after cervical spine fusion surgery: Role of cervical fixation angle. *Acta Anaesthesiol Taiwan* 2008; 46:134–7