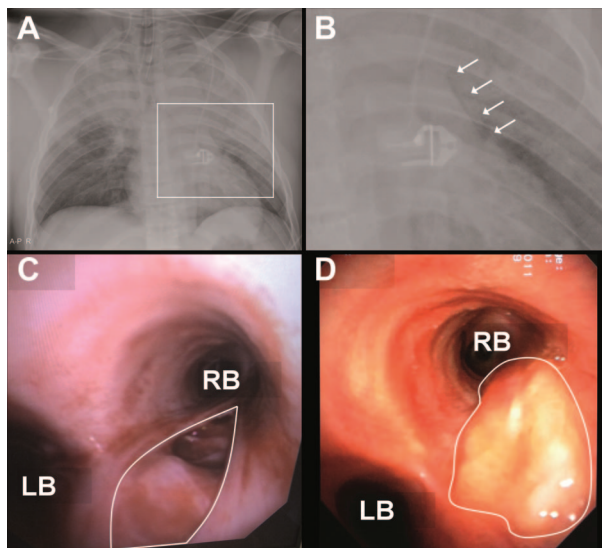


## A 28-year-old Man with Air in the Mediastinal Space after a Car Accident

Martijn Brakman, M.D., K. Tim Buddingh, M.D., Marije Smit, M.D.,  
Michel M. R. F. Struys, M.D., Ph.D., Jan G. Zijlstra, M.D., Ph.D., Matijs van Meurs, M.D., Ph.D.\*

\* Department of Critical Care and Department of Pathology & Medical Biology, Medical Biology Section, Laboratory for Endothelial Biomedicine & Vascular Drug Targeting Research, University of Groningen, University Medical Center Groningen, Groningen, The Netherlands.  
m.van.meurs@umcg.nl



**A** 28-YR-OLD man was admitted to our level I trauma center because of blunt high-energy chest trauma. The chest radiograph ray showed a radiolucent line left of the heart, suggestive of pneumomediastinum (fig. A: radiograph on admission; fig. B: magnification of the white rectangle in fig. A; white arrows mark the radiolucent line. In figs. A and B, an electrocardiogram cable is visible). Chest and pericardial drains were inserted, after which hemodynamic function improved.

Bronchoscopy revealed a 2-cm full-thickness longitudinal airway tear. The lesion began at the carina and continued into the right main bronchus (RB) (fig. C: a bronchoscopic picture of the right main bronchus; the outlined area shows the bronchial lesion [LB = left bronchus]).

Tracheobronchial injuries are life threatening and often are not recognized in the acute setting.<sup>1</sup> The right main bronchus is most frequently affected.<sup>1</sup> Commonly observed radiologic findings are pneumothorax, pneumomediastinum, subcutaneous emphysema, clavicle fracture, rib fractures, pulmonary contusion, widened mediastinum, and hemothorax.<sup>2</sup> Clinical

features include sternal tenderness, dyspnea, hemoptysis and Hamman sign (a crunching, rasping sound heard over the precordium, synchronous with the heartbeat, produced by the heart beating against air-filled tissues in the mediastinum). Bronchoscopy is the gold standard for diagnosis.<sup>3</sup>

Whether tracheobronchial injuries should undergo emergency surgical repair depends in part on whether there are difficulties with mechanical ventilation or the presence of an uncontrolled air leak. The patient's respiratory status was stable, and a wait-and-see approach was chosen. On day 12, the tracheobronchial rupture was fully covered by granulation tissue (fig. D: outlined area shows the healed bronchial lesion). No new pulmonary complications occurred.

### References

1. Beiderlinden M, Adamzik M, Peters J: Conservative treatment of tracheal injuries. *Anesth Analg* 2005; 100:210-4
2. Rossbach MM, Johnson SB, Gomez MA, Sako EY, Miller OL, Calhoun JH: Management of major tracheobronchial injuries: A 28-year experience. *Ann Thorac Surg* 1998; 65:182-6
3. Baumgartner F, Sheppard B, de Virgilio C, Esrig B, Harrier D, Nelson RJ, Robertson JM: Tracheal and main bronchial disruptions after blunt chest trauma: Presentation and management. *Ann Thorac Surg* 1990; 50:569-74