

Case Scenario: Perioperative Administration of Tocotrienols and Green Tea Extract in a Child with Familial Dysautonomia

Scott D. Cook-Sather, M.D.,* Luigi Viola, M.D.,† Karen B. Zur, M.D.,‡ Berish Y. Rubin, Ph.D.§

FAMILIAL dysautonomia (FD, also known as Riley-Day syndrome) is a rare (1:3,700 live births) autosomal recessive disorder, largely afflicting those of Ashkenazi Jewish descent.¹ One of five hereditary sensory and autonomic neuropathies (HSAN, type III) influencing the development and survival of varied sensory, sympathetic, and parasympathetic neurons, FD is characterized by profound autonomic dysfunction resulting in sudden hypertension, orthostatic hypotension, vomiting, and/or abnormal sweating.¹⁻³ Autonomic instability may result in significant morbidity and mortality in the perioperative period.^{3,4}

Recent discoveries in disease genetics and pathophysiology have led to improved treatments for FD patients, greatly reducing the incidence of dysautonomic crises and diminishing symptoms overall.^{2,5-8} Mutations in the gene for inhibitor of κ light polypeptide gene enhancer in B-cells, kinase complex-associated protein (IKBKAP), causing reductions in the cellular protein IKAP, have been linked to

FD.² In addition, tissue concentrations of monoamine oxidase A, an enzyme involved in the metabolic transformation of norepinephrine and dopamine, are low in FD. Both tocotrienols (vitamin E family) and epigallocatechin-3-gallate (a flavonoid found in green tea) increase its cellular concentration (fig. 1).⁵⁻⁹ Oral tocotrienols also increase monoamine oxidase A levels in FD patients.^{5,8}

We describe the management of a child with FD scheduled for adenoidectomy and the impact of maintaining her long-term treatment with tocotrienols and green tea extract (GTE) on her perioperative course.

Clinical Case

This 5-yr-old female presented to the Children's Hospital of Philadelphia Anesthesia Resource Center 2 weeks in advance of adenoidectomy. Prior examination in Otolaryngology Clinic had shown enlarged adenoids but normal-sized tonsils. Polysomnography revealed severe obstructive sleep apnea, hypoventilation, and sleep fragmentation with an obstructive apnea hypopnea index of 13.8 events per hour and a SpO₂ nadir of 72%. Her end-tidal carbon dioxide was 50 or more torr during 50% of total sleep time. When awake, she experienced episodes of upper airway obstruction associated with arterial oxyhemoglobin desaturations to 89 or 90%. When asleep, she demonstrated no significant desaturations with 1 l/min O₂ per nasal cannula, but desaturations occurred frequently during nonrapid eye movement sleep with 0.5 l/min O₂. She had been maintained on 1 l/min O₂ at night and scheduled for nonurgent adenoidectomy. Because continuous positive airway pressure masks are typically not well tolerated by pediatric patients with significant adenoidal hypertrophy, the consulting pulmonologist recommended adenoidectomy before a continuous positive airway pressure trial given that the severity of obstruction did not mandate ventilatory support in advance of an urgent procedure.

Genetic testing at age 9 months confirmed FD, showing her to be homozygous for the major mutation c.2204 + 6T → C. Throughout infancy she had suffered unstable arterial blood pressures, persistent failure to thrive, and gastroparesis, at first attributed to congenital cardiac disease. Char-

* Associate Professor of Anesthesiology, Department of Anesthesiology and Critical Care Medicine, ‡ Assistant Professor, Department of Otolaryngology Head and Neck Surgery, Perelman School of Medicine at the University of Pennsylvania, The Children's Hospital of Philadelphia, Philadelphia, Pennsylvania. † Assistant Professor of Clinical Anesthesia and Pediatrics, Department of Anesthesia, Cincinnati Children's Hospital, Cincinnati, Ohio. § Professor, Laboratory for Familial Dysautonomia Research, Department of Biological Sciences, Fordham University, Bronx, New York.

Received from the Department of Anesthesiology and Critical Care Medicine, Children's Hospital of Philadelphia and the Perelman School of Medicine at the University of Pennsylvania, Philadelphia, Pennsylvania. Submitted for publication September 27, 2011. Accepted for publication June 4, 2012. Support was provided solely from institutional and/or departmental sources. The figure was redrawn by Annemarie B. Johnson, C.M.I., Medical Illustrator, Wake Forest University School of Medicine Creative Communications, Wake Forest University Medical Center, Winston-Salem, North Carolina.

Address correspondence to Dr. Cook-Sather: Department of Anesthesiology and Critical Care Medicine, The Children's Hospital of Philadelphia, 34th Street and Civic Center Boulevard, Philadelphia, Pennsylvania 19104-4399. sather@email.chop.edu. This article may be accessed for personal use at no charge through the Journal Web site, www.anesthesiology.org.

Copyright © 2012, the American Society of Anesthesiologists, Inc. Lippincott Williams & Wilkins. Anesthesiology 2012; 117:639-45

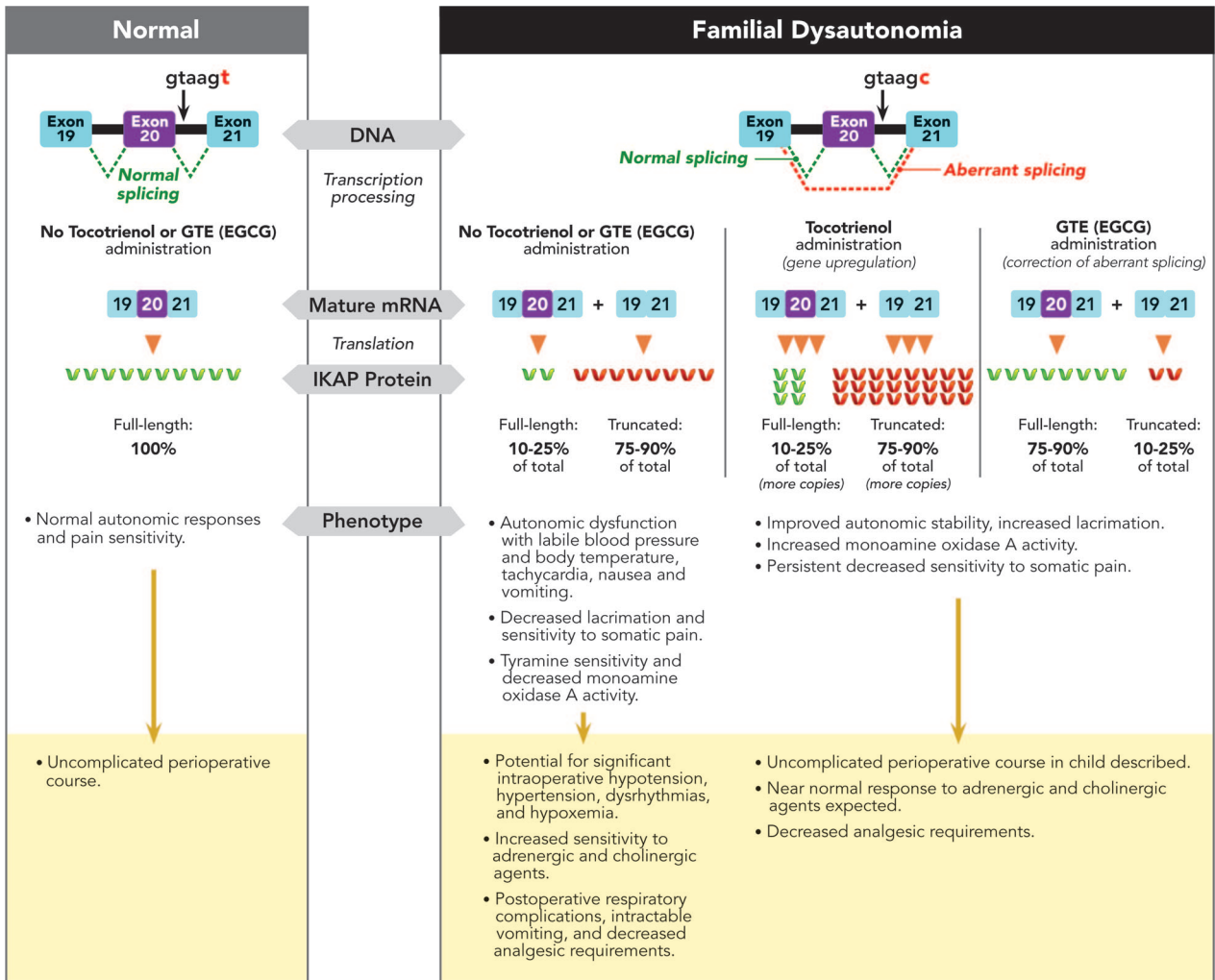


Fig. 1. Tocotrienol and epigallocatechin-3-gallate therapy in familial dysautonomia, and phenotypic implications of altered transcription and translation. Normal IKAP is indicated by green ~, truncated (nonfunctional) protein by red ~. Full-length, functional IKAP in familial dysautonomia patients varies between 10% and 25% of total IKBKAP-derived protein in untreated disease and those on tocotrienols, though because transcription of the IKBKAP gene is up-regulated by tocotrienol, there is a 3- or 4-fold increase in the number of copies of full-length IKAP. The full-length protein may increase to represent 75–90% of total IKBKAP-derived protein in FD patients on green tea extract with concentrated EGCG. Figure courtesy of Sylvia Anderson, Ph.D., Director, Laboratory for Familial Dysautonomia Research, Fordham University, Bronx, New York. EGCG = epigallocatechin-3-gallate; GTE = green tea extract; IKAP = inhibitor of kappa light polypeptide gene enhancer in B-cells, kinase complex-associated protein; IKBKAP = human gene for IKAP; mRNA = messenger RNA.

acteristic symptoms of limited tearing and reduced sensitivity to pain and temperature extremes were also noted. In the months following diagnosis she received escalating doses of tocotrienols and GTE. Although she continued to exhibit decreased responses to pain and temperature changes, lacrimation returned to normal and she experienced no further dysautonomic crises. She also carried the FD-associated diagnoses of gastroesophageal reflux and a 22-degree T6-L1 scoliosis. There was, however, no history of QT prolongation and, on therapy, serial electrocardiograms showed QT and corrected QT (QTc) intervals at 326–348 ms and 366–411 ms, respectively. Other medical history included reactive airway disease and mild developmental delay. Procedural and surgical history included a transcatheter Amplatzer device

occlusion of a left atriopulmonary artery fistula at age 5 months and gastrostomy tube placement at 1 yr, both conducted at outside hospitals. Records of these admissions were not immediately available, but the mother emphatically stated that her child had been unstable following prior surgeries, with episodes of apnea, hypotension, and severe postoperative vomiting consistent with undiagnosed and later undertreated FD. Annual cardiology evaluations included echocardiograms demonstrating normal ventricular function and no recurrent fistula. Significantly in this child with obstructive sleep apnea presenting for adenoidectomy, there was no evidence of pulmonary hypertension or right ventricular hypertrophy. In consultation with her primary care team and surgeon, we elected to continue her tocotrienol and

green tea regimen through the morning of anesthesia and surgery.

On admission the child was without pain and calm in the presence of her parents. Her allergies were confirmed to include red dye and ipratropium. As per our recommendations, she had had nothing to eat since midnight, but she had been given 10 oz of CeraLyte (Cera Products, Inc., Hilton Head, SC) *via* gastrostomy tube 3.5 h before arrival. Vital signs were temperature of 36.7°C, heart rate at 90 beats per minute, arterial blood pressure of 104/56 mmHG, respiratory rate of 28 breaths per minute, SpO₂ at 98% in room air, weight of 13.9 kg, and height of 96.3 cm. Examination of her airway, lungs, and heart was unremarkable. Her skin was pale, nondiaphoretic, and without rash.

Her medications taken that morning included vitamin E (Maxilife Rice Tocotrienols; Twin Labs, Inc., American Fork, UT), each capsule with 50 mg of tocotrienols, six capsules bid for a total daily tocotrienol supplement of 600 mg, or 43 mg/kg per day; Green Tea-70 (FoodScience of Vermont, Essex Junction, VT), each capsule standardized to contain 350 mg of epigallocatechin-3-gallate, one capsule bid for a total daily dose of 700 mg, or 1.1 g · m⁻² per day; calcium supplement, 250 mg bid; famotidine (Pepcid; Salix Pharmaceuticals, Raleigh, NC), 40 mg per 5 ml oral suspension; 2 ml tid; and budesonide (Pulmicort; AstraZeneca, Wilmington, DE) nebulizer bid.

Acetaminophen (210 mg) and midazolam (6 mg, injectable, without red dye) were administered per gastrostomy tube in the preoperative holding area 20 min before induction of anesthesia. Showing no anxiety on separation from her parents, the child was accompanied to the operating room by the nurse. The operating room lights were dimmed and background conversation was held to a minimum in order to decrease sensorial stimuli. Together with the usual emergency drugs, we prepared the following medications (and intended doses): clonidine (0.5–1 µg/kg IV) and esmolol (25–100 µg/kg IV) for hypertensive crisis, and phenylephrine (0.5–1 µg/kg IV) for significant hypotension.

General anesthesia was induced by facemask with incremental concentrations of sevoflurane (to 8%) in oxygen; a peripheral intravenous catheter was placed after several attempts; and tracheal intubation was performed uneventfully (cuffed 4.5 oral Ring Adair Elwyn tube; Mallinckrodt, Covidien L.L.C., Mansfield, MA) after a 20 mg IV propofol bolus. Nondepolarizing neuromuscular blocking agents were not used because of the brevity of the procedure and to obviate the need for reversal. Her eyes were taped closed in the conventional fashion to prevent corneal abrasion. To mitigate postoperative nausea and vomiting risk, we avoided nitrous oxide, discontinued sevoflurane after induction, administered dexamethasone 7 mg (0.5 mg/kg IV), and used a propofol infusion (150 µg/kg per min) for maintenance. Neither ondansetron nor opioid was administered. An intraoperative venous blood sample demonstrated: hemoglobin = 8.5 g/dL; hematocrit = 26.3%; leukocytes = 5.3 ×

10³ mm⁻³; platelets = 241 × 10³ mm⁻³; prothrombin time = 14.6 s (normal: 11–13.5); international normalized ratio = 1.3; and partial thromboplastin time = 27.7 s. A total of 200 ml lactated Ringer's solution was administered. Blood loss was minimal and the surgical procedure was completed without complications. Other than a transient fall in arterial blood pressure from 84/49 to 70/29 during induction, and before completion of an intravenous fluid bolus, there were no significant alterations in heart rate (range 76–114) or arterial blood pressure (range 74–98/33–65). Neither vasopressors nor antihypertensive medications were required. A warming blanket set at 37°C was used throughout. On emergence the child showed spontaneous, regular respirations, good strength, and purposeful movements. Extubation was uneventful, and SpO₂ was 96% or more with supplemental oxygen by mask.

Though a pediatric intensive care unit bed had been reserved in case of significant hemodynamic instability, we were able to transport the awakening, stable child to the postanesthesia care unit. Initial vital signs were arterial blood pressure of 88/40; heart rate at 75 beats per minute; respiratory rate of 28; SpO₂ at 99%; and temperature of 36.3°C. Within minutes the child was fully alert, with only mild throat pain. Supplemental oxygen by nasal cannula was started at 1 l/min to keep SpO₂ at 94% or more. No analgesics were required. After 2 h of observation in the postanesthesia care unit, the patient was admitted to the medical/surgical floor.

A detailed chart review and follow-up interviews with the child's parents were conducted. In contrast to earlier surgical experiences, and now with tocotrienol and green tea supplements restarted immediately after surgery, the family reported total satisfaction with postoperative clinical conditions. The child had no nausea or vomiting; her hemodynamic conditions remained stable; and there was no other evidence of autonomic dysfunction. The SpO₂ remained 99–100% on 0.5 l/min O₂ by nasal cannula, which was stopped on the day of discharge. The Face, Legs, Activity, Crying, Consolability (FLACC) pain score was 0 or 1 (out of 10) throughout the hospital admission, with a single value of 2 several hours after the operation.¹⁰ Only two additional doses of acetaminophen were administered before discharge on postoperative day 1 and the child remained pain-free at home, off further analgesics.

Discussion

FD is considered a progressive neurologic disorder that can lead to substantial loss of neuronal function.^{1,8} Patients demonstrate variable signs and symptoms that may include neonatal hypotonia, delayed developmental milestones, unsteady gait, oropharyngeal incoordination with possible inability to swallow, failure to thrive, decreased perception of somatic pain and temperature, labile body temperature and blood pressure, minimal tearing, and scoliosis.^{1,4} Respiratory dysfunction may result from recurrent aspiration pneumonia, restrictive lung dis-

ease, and apnea secondary to blunted responses to hypoxia and hypercarbia.³ Unlike somatic pain pathways, visceral and musculoskeletal pain pathways remain largely intact.^{9,11} A majority of patients have characteristic dysautonomic crises, which are extended periods of nausea, vomiting, diaphoresis, hypertension, tachycardia, and erythematous skin rashes.¹⁻⁵ Stress and pain can trigger these critical events. There is evidence of enhanced sensitivity to exogenous adrenergic and cholinergic agents, and increased levels of norepinephrine and dopamine in FD patients during crises.⁵

Uncontrolled FD represents a true challenge for the anesthesiologist, who must manage risks associated with all phases of anesthesia and perioperative care. The preoperative period can be problematic for FD patients because anxiety may trigger dysautonomic crisis. A visit to the hospital in advance of surgery may be beneficial not only in conducting a thorough preoperative evaluation and in developing a comprehensive management plan, but also in introducing the patient to a new environment and personnel, thereby allaying some fears of the unfamiliar. We chose not to draw a blood sample at the time of her preanesthesia evaluation because we elicited no history of unusual bleeding or bruising; our consultant (BYR) assured us of near-normal hematology and coagulation values in this patient population; and we wanted to avoid the possibility of a painful, traumatic blood draw.

On the day of surgery we began anesthesia care with preoperative midazolam administered *via* gastrostomy tube. Although midazolam may depress respiratory drive and potentially transiently worsen obstructive sleep apnea, its anxiolytic properties and short duration of action were thought to be ideal. Following midazolam administration, our patient became relaxed, but not sedated, and she calmly entered the quiet operating room with dimmed lighting.

Induction may be accomplished with various agents, but several experts recommend rapid-sequence intravenous induction with cricoid pressure because of the common presence of active gastroesophageal reflux.⁴ Among intravenous anesthetics, ketamine may be less likely to trigger hypotension in FD patients, although there are reports of bradycardia and cardiac arrest after thiopental administration.^{3,4,12} Because our child came without intravenous access, appeared to have small peripheral vessels, and was appropriately fasted, we proceeded with an inhalation induction using sevoflurane in oxygen. To minimize the risk of postoperative nausea and vomiting, we administered dexamethasone, avoided nitrous oxide and further potent agent, and maintained anesthesia with a propofol infusion. We did not administer ondansetron for two reasons: a higher incidence of QTc prolongation in FD patients, and the possible altered serotonin metabolism secondary to decreased monoamine oxidase A activity.⁴ By also avoiding nondepolarizing neuromuscular blocking agents and, subsequently, anticholinergic and anticholinesterase combinations, we also may have mitigated the poten-

tial for adverse cardiac events during emergence seen in some patients with long QT syndrome.¹³

Our patient demonstrated normal hemodynamic variability associated with anesthesia and surgery for this procedure. She experienced none of the most common intraoperative problems reported in FD patients (hypoxemia, hypotension, hypertension, bradycardia, dysrhythmias, heart block, and/or cardiac arrest) and, later, none of the associated postoperative complications (intractable vomiting, excessive secretions, atelectasis, pneumonia and respiratory arrest requiring reintubation).^{3,4,12} We attribute our patient's perioperative hemodynamic stability to the continuation of her tocotrienol and GTE regimen. Before this therapy and shortly after its introduction, she likely had insufficient drug and low IKAP levels, resulting in two difficult postoperative courses that included apnea, hypotension, and severe, refractory vomiting.

Knowledge Gap

There are two genetic mutations known to cause FD.^{2,14,15} The major or more common mutation, c.2204 + 6T→C (formerly IVS20 + 6T→C), is a T→C transition in position 6 of the donor splice site of intron 20, which causes a skipping of exon 20 (fig. 1). The absence of exon 20 creates a frameshift that in turn generates a truncated IKAP protein. The minor or less common FD-causing mutation, p.R696P, is a G→C transversion in exon 19 of the reported IKBKAP complementary DNA. This mutation causes an arginine to proline substitution of amino acid residue 696 of IKAP (R696) and the disruption of a consensus serine/threonine kinase phosphorylation site (arginine/isoleucine/valine/threonine to proline/isoleucine/valine/threonine, RIVT→pIVT).

There remains an incomplete understanding of the many IKAP biologic activities and how these may mediate the neurologic deficits seen in the FD population.² At the cellular level, IKAP has been shown to regulate transcriptional elongation,¹⁶ the c-Jun N-terminal kinase (JNK) signaling pathway,¹⁷ exocytosis,¹⁸ neuronal development during embryogenesis,¹⁹ transfer RNA modification,²⁰ and actin cytoskeleton formation.²¹ The more extensively studied c.2204 + 6T→C mutation gives rise to a truncated IKAP, which is functionally not effective. However, tocotrienols up-regulate IKAP transcription, resulting in increased levels of the full-length, functional IKAP in normal and in FD-derived cells.^{2,5,7,8} Epigallocatechin-3-gallate also increases the levels of the full-length protein in FD-derived cells,⁶ but, as shown in figure 1, by correction of aberrant splicing rather than by gene up-regulation. These agents that increase functional IKAP levels also enhance monoamine oxidase gene expression, which is significant in FD patients because there are reduced baseline levels of monoamine oxidase A in FD tissues. Because monoamine oxidase A oxidizes norepinephrine and serotonin, and, to a lesser degree, dopamine and tyramine, tocotrienol and epigallocatechin-3-gallate therapy in FD can restore ap-

propriate metabolism of these vasoactive substances and minimize hemodynamic instability.^{2,5}

Although administration of tocotrienols and GTE greatly improves autonomic stability and lacrimation, not all features of FD are reversed by the combination.^{2,8} In particular, sensitivities to pain and temperature tend not to be significantly improved. It is possible that FD-associated *in utero* neuronal deficits in these pathways are irrevocably altered. With regard to QT variability and other conduction abnormalities in the FD population,^{22–24} it is unknown whether tocotrienols and GTE return patients to normal conduction patterns, and in particular, to normal transmural dispersion of repolarization. The normal electrocardiograms for our patient were done while she was on high-dose therapy. To date there is no evidence that suggests the selective responsiveness of cell types to the effects of tocotrienols and GTE. Daily administration of tocotrienols and GTE remains essential, however. Those patients who stop taking these medications begin to experience return of FD symptoms within 1 week and, by 2 weeks, revert to having all their characteristic symptoms, especially increasing malaise and frequent hypertensive crises. It is unclear at what point washout of tocotrienols and epigallocatechin-3-gallate would result in reduced full-length IKAP concentrations insufficient to prevent cardiovascular instability during anesthesia and postoperative recovery. No intensified rebound symptoms, such as those seen in the setting of acute withdrawal of opioids or adrenergic blockers, have been seen with cessation of tocotrienols and epigallocatechin-3-gallate.

With varying success, other compounds have recently been used to treat FD. Pregabalin may improve some symptoms associated with FD,²⁵ but does not address the underlying functional protein deficiency. Kinetin, a plant cytokinin, does facilitate the inclusion of exon 20 in the transcript generated in FD-derived cell lines,²⁶ but significant hepatotoxicity has been seen in early clinical trials.²⁷ And although no clinical studies employing phosphatidylserine have been reported in the literature, treatment of FD-derived cells with phosphatidylserine elevates IKBKAP expression, resulting in increased production of the full-length transcript from the c.2204 + 6T→C-bearing allele.²⁸

Though the American Society of Anesthesiologists has not published formal guidelines regarding the preoperative use of herbal medications and nutritional supplements, given the limited clinical data available, a conservative approach that discontinues use up to 2 or 3 weeks in advance of surgery seems favored.^{29,30} In particular, continuation of vitamin E derivatives is not recommended because these may increase bleeding, especially in conjunction with other anticoagulant and antithrombotic drugs. Vitamin E complex includes tocopherols and tocotrienols, with α -tocopherol the most potent isomer.³¹ There is evidence that it inhibits *in vitro* platelet aggregation and release. However, none of those effects has been seen *in vivo* even with high-dose vitamin E supplementa-

tion (400–1,200 U/day for 2 weeks in healthy adults.)^{31,32} Some authors report an inhibitory effect of vitamin E on platelet adhesion at lower doses (200 U/day) because of a change of platelet shape.³² There is an unequivocal increase in anticoagulation effect with high doses of vitamin E among patients taking oral anticoagulants.³³ Mensink *et al.* conducted a double-blind randomized controlled trial on 40 adults taking either tocotrienol or tocopherol in which no one had changes of platelet function.³⁴ Because our patient was not on anticoagulation/antiplatelet medications and stood to greatly benefit from continued tocotrienol administration, we elected to continue it and found no evidence of significant clinical bleeding during or after the procedure.

Green tea is the nonoxidized/nonfermented derivative of the leaves of *Camellia sinensis*. It contains caffeine and polyphenols, such as epigallocatechin-3-gallate. Although studies are limited in humans, catechins like epigallocatechin-3-gallate do not show any hematologic toxicity. There is, however, evidence of increased bleeding time in rats exposed to catechins, probably because of adenosine diphosphate inhibition and platelet aggregation dysfunction, and there is a dose-dependent inhibition of human platelet aggregation *in vitro*.³⁵ Although several European countries removed GTEs from market in 2003 following a case report of acute liver failure in a previously healthy woman after 6 months of use, this would seem to have been an exceptionally rare association.³⁶ In adults, the maximum tolerated dose for GTE is 1.3–4.2 g/m².^{37–39} A total dose of 2.25 g (approximately 1.3 g/m²) is equivalent to 10 cups of green tea. Different formulations of GTE may have varying amounts of epigallocatechin-3-gallate: that in Green Tea-70 is more concentrated than in the GTE product (manufactured by Ito En, Tokyo, Japan) used in the Laurie study³⁷ (70% *vs.* 13.9% by weight.) Considering only the epigallocatechin-3-gallate contained in the GTE, its maximum tolerated dose might then range from 180–580 mg/m² per day. Our patient was taking 700 mg a day, or roughly 1.1 g/m² per day, of epigallocatechin-3-gallate. The most common adverse symptoms associated with GTE, possibly related to the caffeine component in some preparations (6.8% by weight in the Ito En product), include epigastric discomfort, heartburn, diarrhea, insomnia, and anxiety.^{37,39}

The evidence demonstrating a significant beneficial effect of tocotrienols and green tea supplementation in this patient and others with FD, and the lack of convincing data about important hematologic toxicity from these same substances, persuaded us to continue the treatment before an elective surgery. Our patient showed no hemodynamic instability and had no unusual bleeding associated with her procedure. For patients undergoing procedures requiring anticoagulation with heparin or warfarin, we may not have chosen to continue these supplements. FD patients are now surviving longer, and may present for various surgical procedures. Based on the current literature and the successful case de-

Table 1. Recommended Anesthetic Management of a Child with Familial Dysautonomia on Tocotrienols and Green Tea Extract**Preoperative**

Obtain history of dysautonomic episodes, pain and temperature insensitivity, and lacrimation on therapy.
 Complete blood count with platelets, prothrombin time, international normalized ratio, and partial thromboplastin time for history of unusual bleeding or bruising, or as indicated for procedure.
 Electrocardiogram for determination of QT and QTc.
 Encourage hydration with clear liquids up to 2 h before induction of anesthesia.
 Continue tocotrienols and GTE through morning of surgery unless anticoagulation is planned, in which case consider reducing the tocotrienol regimen.
 Midazolam for anxiolysis.

Intraoperative

Reduce patient stimulation, possibly employing parental presence at induction of anesthesia.
 Induce inhalation with sevoflurane or intravenous induction with propofol.
 If long QT, consider minimizing sevoflurane exposure and avoid ondansetron, especially during reversal and emergence.
 Consider propofol infusion to minimize postoperative nausea and vomiting.
 Limited systemic analgesics with sparing use of opioids.
 Employ regional adjuvant techniques, when feasible.
 Use warming blanket/forced air warmer.
 Tape eyes, use lubricant as indicated for procedure.
 Use invasive monitoring only as indicated for procedure itself.
 Prepare for administration of emergency medications: clonidine (0.5 or 1 $\mu\text{g}/\text{kg}$), esmolol (25–100 $\mu\text{g}/\text{kg}$), or phenylephrine (0.5 or 1 $\mu\text{g}/\text{kg}$).

Postoperative

Reduced analgesic requirements: acetaminophen and nonsteroidal anti-inflammatory agents generally suffice, add reduced doses of opioids as needed.
 Resume tocotrienols and GTE as soon as patient able to tolerate enteral medications.
 Routinely monitor vital signs.
 Question for nausea/vomiting, consider benzodiazepine treatment.

GTE = green tea extract.

scribed here, we propose a perioperative care plan for children with FD (table 1). Additional studies are needed on larger cohorts of these patients to determine: ideal dosing regimens; whether routine transaminases, prothrombin time, international normalized ratio, partial thromboplastin time, platelet levels, and/or bleeding time are required; and whether measures to minimize postoperative nausea and vomiting, such as avoiding nitrous oxide and halogenated anesthetics, are warranted. At present, anesthesiologists caring for FD patients should strongly consider continuation of tocotrienols and green tea supplements to improve perioperative care.

References

1. Axelrod FB, Chelmsky GG, Weese-Mayer DE: Pediatric autonomic disorders. *Pediatrics* 2006; 118:309–21
2. Rubin BY, Anderson SL: The molecular basis of familial dysautonomia: Overview, new discoveries and implications for directed therapies. *Neuromolecular Med* 2008; 10:148–56
3. Weingarten TN, Sprung J, Burgher AH: Perioperative management of familial dysautonomia: A systematic review. *Eur J Anaesthesiol* 2007; 24:309–16
4. Ngai J, Kreyenin I, Kim JT, Axelrod FB: Anesthesia management of familial dysautonomia. *Paediatr Anaesth* 2006; 16: 611–20
5. Anderson SL, Rubin BY: Tocotrienols reverse IKAP and monoamine oxidase deficiencies in familial dysautonomia. *Biochem Biophys Res Commun* 2005; 336:150–6
6. Anderson SL, Qiu J, Rubin BY: EGCG corrects aberrant splicing of IKAP mRNA in cells from patients with familial dysautonomia. *Biochem Biophys Res Commun* 2003; 310: 627–33
7. Anderson SL, Qiu J, Rubin BY: Tocotrienols induce IKBKAP expression: A possible therapy for familial dysautonomia. *Biochem Biophys Res Commun* 2003; 306:303–9
8. Rubin BY, Anderson SL, Kapás L: Can the therapeutic efficacy of tocotrienols in neurodegenerative familial dysautonomia patients be measured clinically? *Antioxid Redox Signal* 2008; 10:837–41
9. Axelrod FB: A world without pain or tears. *Clin Auton Res* 2006; 16:90–7
10. von Baeyer CL, Spagrud LJ: Systematic review of observational (behavioral) measures of pain for children and adolescents aged 3 to 18 years. *Pain* 2007; 127:140–50
11. Weingarten TN, Sprung J, Ackerman JD, Bojanic K, Watson JC, Dyck PJ: Anesthesia and patients with congenital hyposensitivity to pain. *ANESTHESIOLOGY* 2006; 105:338–45
12. Axelrod FB, Donenfeld RF, Danziger F, Turndorf H: Anesthesia in familial dysautonomia. *ANESTHESIOLOGY* 1988; 68:631–5
13. Nathan AT, Berkowitz DH, Montenegro LM, Nicolson SC, Vetter VL, Jobes DR: Implications of anesthesia in children with long QT syndrome. *Anesth Analg* 2011; 112:1163–8
14. Anderson SL, Coli R, Daly IW, Kichula EA, Rork MJ, Volpi SA, Ekstein J, Rubin BY: Familial dysautonomia is caused by mutations of the IKAP gene. *Am J Hum Genet* 2001; 68: 753–8
15. Slaugenhaupt SA, Blumenfeld A, Gill SP, Leyne M, Mull J, Cuajungco MP, Liebert CB, Chadwick B, Idelson M, Reznik L, Robbins C, Makalowska I, Brownstein M, Krappmann D, Scheidereit C, Maayan C, Axelrod FB, Gusella JF: Tissue-specific expression of a splicing mutation in the IKBKAP gene causes familial dysautonomia. *Am J Hum Genet* 2001; 68:598–605
16. Hawkes NA, Otero G, Winkler GS, Marshall N, Dahmus ME, Krappmann D, Scheidereit C, Thomas CL, Schiavo G, Erdjument-Bromage H, Tempst P, Svejstrup JQ: Purification and characterization of the human elongator complex. *J Biol Chem* 2002; 277:3047–52
17. Holmberg C, Katz S, Lerdrup M, Herdegen T, Jäättelä M, Aronheim A, Kallunki T: A novel specific role for I kappa B kinase complex-associated protein in cytosolic stress signaling. *J Biol Chem* 2002; 277:31918–28
18. Rahl PB, Chen CZ, Collins RN: E1p1p, the yeast homolog of the FD disease syndrome protein, negatively regulates exocytosis independently of transcriptional elongation. *Mol Cell* 2005; 17:841–53
19. Chen YT, Hims MM, Shetty RS, Mull J, Liu L, Leyne M, Slaugenhaupt SA: Loss of mouse Ikbkap, a subunit of elongator, leads to transcriptional deficits and embryonic lethality that can be rescued by human IKBKAP. *Mol Cell Biol* 2009; 29:736–44

20. Mehlgarten C, Jablonowski D, Wrackmeyer U, Tschitschmann S, Sondermann D, Jäger G, Gong Z, Byström AS, Schaffrath R, Breunig KD: Elongator function in tRNA wobble uridine modification is conserved between yeast and plants. *Mol Microbiol* 2010; 76:1082-94
21. Cheishvili D, Maayan C, Cohen-Kupiec R, Lefler S, Weil M, Ast G, Razin A: IKAP/Elp1 involvement in cytoskeleton regulation and implication for familial dysautonomia. *Hum Mol Genet* 2011; 20:1585-94
22. Rotstein A, Charrow J, Deal BJ: Documented transient third-degree atrioventricular block and asystole in a child with familial dysautonomia. *Pediatr Cardiol* 2008; 29:202-4
23. Solaimanzadeh I, Schlegel TT, Feiveson AH, Greco EC, DePalma JL, Starc V, Marthol H, Tutaj M, Buechner S, Axelrod FB, Hiltz MJ: Advanced electrocardiographic predictors of mortality in familial dysautonomia. *Auton Neurosci* 2008; 144:76-82
24. Nussinovitch U, Katz U, Nussinovitch M, Nussinovitch N: Late ventricular potentials and QT dispersion in familial dysautonomia. *Pediatr Cardiol* 2009; 30:747-51
25. Axelrod FB, Berlin D: Pregabalin: A new approach to treatment of the dysautonomic crisis. *Pediatrics* 2009; 124:743-6
26. Slaugenhaupt SA, Mull J, Leyne M, Cuajungco MP, Gill SP, Hims MM, Quintero F, Axelrod FB, Gusella JF: Rescue of a human mRNA splicing defect by the plant cytokinin kinetin. *Hum Mol Genet* 2004; 13:429-36
27. Axelrod FB, Liebes L, Gold-Von Simson G, Mendoza S, Mull J, Leyne M, Norcliffe-Kaufmann L, Kaufmann H, Slaugenhaupt SA: Kinetin improves IKBKAP mRNA splicing in patients with familial dysautonomia. *Pediatr Res* 2011; 70:480-3
28. Keren H, Donyo M, Zeevi D, Maayan C, Pupko T, Ast G: Phosphatidylserine increases IKBKAP levels in familial dysautonomia cells. *PLoS One* 2010; 5:e15884
29. Ang-Lee MK, Moss J, Yuan CS: Herbal medicines and perioperative care. *JAMA* 2001; 286:208-16
30. Kaye AD, Kucera I, Sabar R: Perioperative anesthesia clinical considerations of alternative medicines. *Anesthesiol Clin North America* 2004; 22:125-39
31. Dereska NH, McLemore EC, Tessier DJ, Bash DS, Brophy CM: Short-term, moderate dosage Vitamin E supplementation may have no effect on platelet aggregation, coagulation profile, and bleeding time in healthy individuals. *J Surg Res* 2006; 132:121-9
32. Steiner M: Influence of vitamin E on platelet function in humans. *J Am Coll Nutr* 1991; 10:466-73
33. Booth SL, Golly I, Scheck JM, Roubenoff R, Dallal GE, Hamada K, Blumberg JB: Effect of vitamin E supplementation on vitamin K status in adults with normal coagulation status. *Am J Clin Nutr* 2004; 80:143-8
34. Mensink RP, van Houwelingen AC, Kromhout D, Hornstra G: A vitamin E concentrate rich in tocotrienols had no effect on serum lipids, lipoproteins, or platelet function in men with mildly elevated serum lipid concentrations. *Am J Clin Nutr* 1999; 69:213-9
35. Kang WS, Lim IH, Yuk DY, Chung KH, Park JB, Yoo HS, Yun YP: Antithrombotic activities of green tea catechins and (-)epigallocatechin gallate. *Thromb Res* 1999; 96:229-37
36. Molinari M, Watt KD, Kruszyna T, Nelson R, Walsh M, Huang WY, Nashan B, Peltekian K: Acute liver failure induced by green tea extracts: Case report and review of the literature. *Liver Transpl* 2006; 12:1892-5
37. Laurie SA, Miller VA, Grant SC, Kris MG, Ng KK: Phase I study of green tea extract in patients with advanced lung cancer. *Cancer Chemother Pharmacol* 2005; 55:33-8
38. Pisters KM, Newman RA, Coldman B, Shin DM, Khuri FR, Hong WK, Glisson BS, Lee JS: Phase I trial of oral green tea extract in adult patients with solid tumors. *J Clin Oncol* 2001; 19:1830-8
39. Suga K, Imai K, Sueoka N, Nakachi K: Phase I clinical trial with green tea tablets in a Japanese healthy population. *Cancer Prev Intl* 1998; 3:79-88