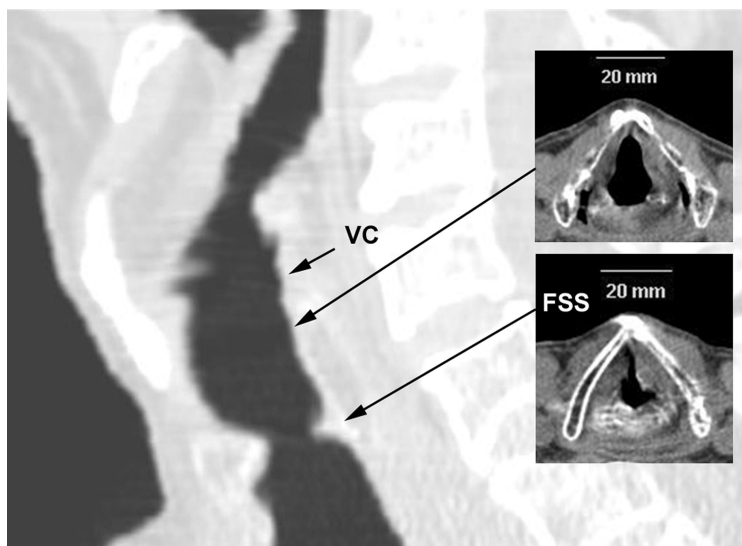


Images in Anesthesiology: Unexpected Difficult Intubation Caused by a Subglottic Tracheal Ring

Adrián Escudero, M.D.,* María Teresa Sariñena, M.D., Luis Delgado, M.D.,
María Dolores Guerrero, M.D., Jaime Canet, Ph.D.

*Department of Anesthesiology, Hospital Universitari Germans Trias I Pujol, Barcelona, Spain
29153aet@comb.cat



A 71-YR-OLD man admitted for elective off-pump coronary bypass grafting had a medical history of diphtheria in childhood, hypertension and myocardial ischemia with stable angina pectoris, and no previous anesthesia. The airway was Mallampati class 1 (thyromental distance 7 cm, normal cervical spine mobility).

General anesthesia was induced with sevoflurane. Ventilation through a facial mask was easy. The laryngoscopic view was Cormack-Lehane grade 1. When the endotracheal tube (8 mm internal diameter) did not advance beyond the vocal cords (VC), intubation was reattempted with smaller tubes until a 5.5-mm tube passed the glottis. Extubation was performed in the operating room, and no stridor was heard. Fiber-optic bronchoscopy showed a fibrotic subglottic stenosis (FSS) obstructing 75% of the tracheal

lumen under the vocal cords. Computed tomography in the sagittal view also demonstrated a membranous ring causing subglottic stenosis 1.2 cm under the vocal cords. The patient was discharged after 10 days.

Congenital abnormality and diphtheric membrane are possible causes of our patient's laryngeal web. Congenital webs have been estimated to occur in 1 in 10,000 births.¹ An acquired ring usually is iatrogenic, resulting from tracheal mucosal and submucosal injury, often from long-term intubation.² Dyspnea is more common than stridor, hoarseness, brassy cough, or cyanosis. Mild, asymptomatic stenosis in adults usually is diagnosed after difficult intubation or during respiratory endoscopy.

In this case, if the endotracheal tube had not passed the narrow section of the airway, we could have used a supraglottic airway or percutaneous femoral vascular cannulation and cardiopulmonary bypass with extracorporeal membrane oxygenation as alternatives.³

References

- Scholz A, Srinivas K, Stacey MR, Clyburn P: Subglottic stenosis in pregnancy. *Br J Anaesth* 2008; 100:385-8
- Ceron A, Ambroselli V, Zannoni C, Bertollo D: Unexpected difficult intubation caused by subglottic ring. *Anaesthesia* 2000; 55: 595-6
- Isono S, Kitamura Y, Asai T, Cook TM: Case scenario: Perioperative airway management of a patient with tracheal stenosis. *ANESTHESIOLOGY* 2010; 112:970-8