

Case Scenario: Anesthetic Considerations for Thoracoabdominal Aortic Aneurysm Repair

Stephen B. Vaughn, M.D.,* Scott A. LeMaire, M.D.,† Charles D. Collard, M.D.‡

THORACOABDOMINAL aortic aneurysm (TAAA) repair presents a challenging and complex task for both the surgeon and anesthesiologist. Historically, morbidity and mortality for TAAA repair has been high, and is both surgeon- and institution-dependent.¹ However, the TAAA complication rate has improved significantly in the past decade *via* research, improved surgical technique, and perioperative management.^{2–11} An update on the perioperative management of the patient undergoing open TAAA repair is presented.

Case Report

A 69-yr-old Caucasian man presented for repair of a 7.6 cm extent II TAAA (fig. 1). The patient's history was significant for a ruptured type I aortic dissection repaired in 1998; redo-sternotomy for repair of an ascending aortic graft pseudoaneurysm and the aortic arch, with "elephant trunk" placement ("elephant trunk" is a technique used during aortic arch repair where an excess distal length of tubular graft material extends freely into the descending aorta to facilitate the subsequent repair of a descending aortic aneurysm) in 1999; abdominal aortic aneurysm repair in 2001; hypertension; sick sinus syndrome (managed with a pacemaker); giant cell arteritis; and chronic renal insufficiency secondary to a right

atrophic kidney. All previous surgeries were performed at another hospital. Preoperative laboratory values were within the normal range.

In addition to the standard American Society of Anesthesiologists' monitors, a right radial arterial line was inserted and near-infrared spectrometry and Bispectral Index leads placed on the patient's head. Initial cerebral oximetry readings were 70% and 72% on the right and left hemispheres, respectively. The patient's pacemaker was converted to an asynchronous mode at a rate of 80 beats/min. Anesthesia was induced with etomidate, fentanyl, and rocuronium, with isoflurane used for anesthetic maintenance. After induction, a 35-French, left-sided double lumen tube was inserted. Additional intravenous access was obtained *via* right internal jugular vein 9-French multilumen access and pulmonary artery catheter. After inserting a transesophageal echocardiography probe, the patient was placed in the right lateral decubitus position and a lumbar cerebrospinal fluid (CSF) drain placed. Aminocaproic acid was used for antifibrinolysis. Vancomycin was administered before incision per the Surgical Care Improvement Project guidelines.

Upon left posterolateral thoracoabdominal surgical incision, the mean arterial pressure (MAP) was maintained between 65–80 mmHg before cross-clamping. Permissive hypothermia was allowed, resulting in a decrease of the patient's temperature to approximately 32.2 C° (measured *via* a nasopharyngeal temperature probe) just before aortic cross-clamping. Mannitol 25 g was given to help maintain renal perfusion, and 1 mg/kg heparin was administered before commencement of left heart bypass (LHB). LHB was instituted *via* cannulation of the left inferior pulmonary vein and the lower descending thoracic aorta, and flows were maintained at 1.5–2 l/min to maintain a MAP of approximately 80 mmHg. The proximal aortic clamp was then placed on the aortic arch between the left common carotid and left subclavian arteries; a separate clamp was placed across the left subclavian artery. Nicardipine was used to offset the increase in afterload after clamping. During cross-clamping, the MAP was kept between 85–90 mmHg to maintain spinal cord perfusion. CSF was drained intermittently to keep the

* Fellow, Baylor College of Medicine, Division of Cardiovascular Anesthesiology, Texas Heart Institute, St. Luke's Episcopal Hospital, Houston, Texas. † Professor and Director of Research, Division of Cardiothoracic Surgery, Michael E. DeBakey Department of Surgery, Baylor College of Medicine, Houston, Texas. ‡ Professor, Baylor College of Medicine, Anesthesiologist-in-Chief, St. Luke's Episcopal Hospital, Chief, Division of Cardiovascular Anesthesiology, Texas Heart Institute, Houston, Texas.

Received from the Texas Heart Institute, St. Luke's Episcopal Hospital, Houston, Texas. Submitted for publication April 20, 2011. Accepted for publication July 18, 2011. Support provided solely from institutional and/or departmental sources.

Address correspondence to Dr. Collard: St. Luke's Episcopal Hospital, Division of Cardiovascular Anesthesiology, Texas Heart Institute, 6720 Bertner Avenue, Room 0520, MC 1–226, Houston, Texas 77030. ccollard@heart.thi.tmc.edu. This article may be accessed for personal use at no charge through the Journal Web site, www.anesthesiology.org.

Copyright © 2011, the American Society of Anesthesiologists, Inc. Lippincott Williams & Wilkins. Anesthesiology 2011; 115:1093–102

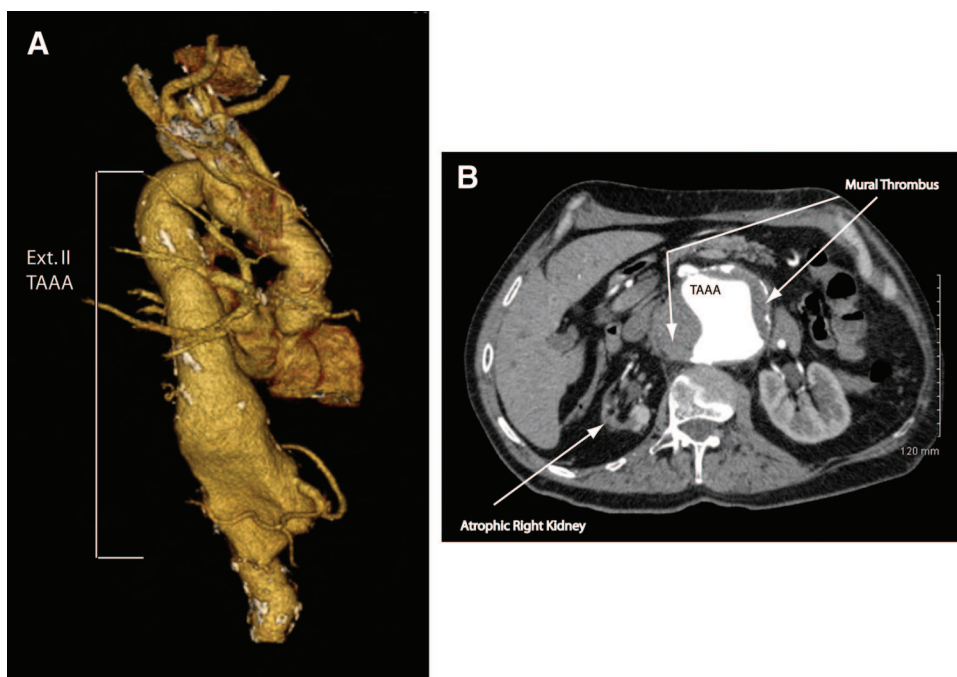


Fig. 1. Three-dimensional reconstruction (A) and axial contrast enhanced computed tomography image (B) of thoracoabdominal aortic aneurysm. Note the aneurysm is lined with thrombus and the right kidney is severely atrophic (arrows). TAAA = thoracoabdominal aortic aneurysm.

CSF pressure less than 15 mmHg. After the proximal anastomosis was completed, the left subclavian artery clamp was removed and the proximal aortic clamp was moved onto the graft; this restored flow to the left subclavian artery. LHB (26 min) was discontinued, and the remainder of the aneurysm was opened. Selected intercostal arteries (T7-T9), the celiac axis, and the superior mesenteric artery were reimplanted using an “island” technique (an “island” technique involves reimplanting a patch of aortic tissue that contains the blood vessels to the graft). The left renal artery was reattached using a 10-mm Dacron interposition graft. The right renal artery was not reattached given the patient’s history of severe right kidney atrophy. A renal perfusate consisting of chilled lactated Ringer’s solution, mannitol, and methylprednisolone was intermittently used to achieve left kidney hypothermia during aortic clamping. The cross-clamp moved sequentially down the aorta to reperfuse the intercostal arteries, bowel, lower extremities, and the left kidney for “unprotected” ischemic times (*e.g.*, the ischemic time after LHB was discontinued) of 20, 38, 38, and 54 min, respectively. Approximately 10 min before removal of the aortic cross-clamp and reperfusion of the intercostal arteries, a norepinephrine infusion was initiated to maintain the MAP between 80–90 mmHg. During this period, the patient was also given two units of packed erythrocytes to maintain the hemoglobin more than 10 g/dL, 5% albumin for intravascular volume support, calcium chloride, and sodium bicarbonate to help counteract the metabolic derangements seen with aortic reperfusion.

At the time of left kidney reperfusion, furosemide and indigo carmine were given, with 12 min passing before blue dye was observed in the urine. From the time of aortic cross-clamping to left kidney reperfusion, the patient’s body temperature decreased to 30.5°C. After reversal of the heparin with protamine active rewarming was begun, which included increasing the ambient room temperature, warming the intravenous fluids, irrigating the surgical field with warm saline, and use of a forced-air body warmer. Norepinephrine was used to maintain a MAP between 80–90 mmHg, with intermittent boluses of calcium chloride given to maintain a normal plasma ionized concentration. Transfusion totals for the surgery included 5 units packed erythrocytes, 6 units fresh frozen plasma, 20 units platelets, and 1,250 ml cell saver blood; also administered were 1,500 ml 5% albumin and 2,000 ml crystalloid. Outputs were 2,500 ml urine and a 3,000-ml estimated blood loss. The patient was taken to the intensive care unit with a propofol infusion for sedation.

In the intensive care unit, the patient was hemodynamically stable, neurologically intact, and receiving no inotropic support, with MAPs between 80–90 mmHg and CSF pressures less than 15 mmHg. On postoperative day 1, the patient was extubated and the CSF drain clamped; there was no evidence of neurologic sequelae.

Discussion

TAAAs are most commonly classified according to the Crawford classification system (fig. 2). The mean growth rate for all thoracic aortic aneurysms is 0.1 cm per year, with aortic aneurysm size directly correlating with rupture, dissection,

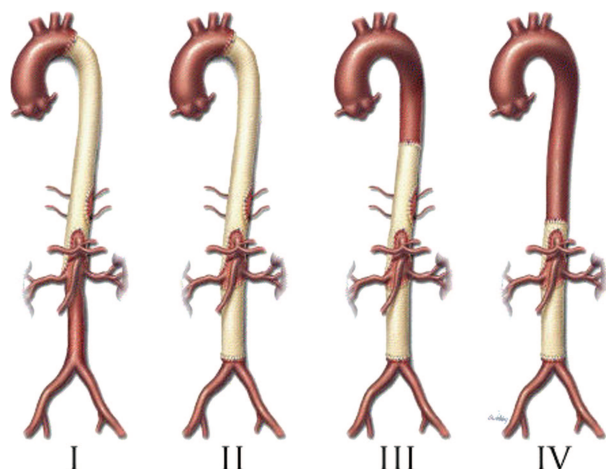


Fig. 2. The Crawford classification scheme for thoracoabdominal aneurysm repair. Reproduced with permission from Coselli JS, Bozinovski J, LeMaire SA: Open surgical repair of 2286 thoracoabdominal aneurysms. *Ann Thorac Surg* 2007; 83:s862–4. Copyright Elsevier.

and death. Growth rate is greater for descending aortic aneurysms compared with ascending aortic aneurysms; aneurysms caused by dissection compared with nondissection aneurysms; and aneurysms associated with conditions such as Marfan syndrome and other connective tissue disorders compared with those without such conditions.¹²

Dapunt *et al.* looked at the risk factors for aneurysm expansion and found that a history of hypertension, male sex, age older than 70 yr, history of smoking, and initial aneurysm diameter more than 5 cm at diagnosis were independent predictors of rapid expansion.¹³ A prospective study in which more than 500 TAAA patients were followed over 9 yr revealed the annual rupture or dissection rate was 7% for aneurysms more than 6 cm.¹⁴ This same study showed pre-emptive surgical repair restored normal life expectancy.¹⁴ Crawford and DeNatale followed 94 TAAA patients who had not been managed surgically and found that 75% of these patients died within 2 yr, of which approximately 50% of the deaths were secondary to aneurysm rupture.¹⁵ Therefore, surgical intervention is generally advised for TAAAs, especially when the aneurysm is more than 6 cm in diameter. When determining whether or not a patient should undergo TAAA repair, the benefit versus the risk of such a procedure must be weighed. Because the risk of acute perioperative death may be higher than the repair benefit in patients with preexisting, uncorrectable medical comorbidities, the prudent decision might be to forego surgery.

Historically, elective surgical TAAA repair has carried a mortality rate of 5–25%, with mortality being significantly higher when this type of surgery is performed at institutions or by surgeons inexperienced with the surgical technique.^{1,16} Therefore, it has been proposed that regionalization of care of these types of surgical cases to the higher-volume hospitals and surgeons is warranted.^{1,16}

Preoperative Management

Given the potential risks and complications of TAAA repair, a thorough preoperative evaluation is imperative. Particular attention should be given to the patient's cardiac, respiratory, renal, and neurologic function because these patients are at highest risk of developing complications related to these systems (table 1).^{3,9,17–18} Symptoms of an enlarging TAAA include back pain, epigastric pain, hoarseness related to left recurrent laryngeal nerve palsy, and those related to direct compression of the tracheobronchial tree, such as shortness of breath, cough, and hemoptysis.

Cardiac. Perioperative cardiac morbidity and mortality for TAAA repair is approximately 10–15% or greater.^{17–18} The heart is subjected to significant hemodynamic stress by placement of the proximal aortic cross-clamp,¹⁹ as well as considerable physiologic alterations secondary to fluid shifts and blood loss. Hafez *et al.*¹⁸ found that approximately 30% of patients undergoing TAAA repair experienced some type of cardiac dysfunction within 24 h postoperatively. They also reported significant increases in the myocardial injury marker troponin-T at 8 and 24 h after reperfusion in patients who underwent TAAA repair with supraceliac aortic clamping.¹⁸ Using transesophageal echocardiography, Fayad *et al.* demonstrated acute diastolic dysfunction upon aortic cross clamping in two thirds of patients undergoing TAAA repair.²⁰ Thus, the presence of coronary artery disease, valvular function, and overall heart function should be assessed preoperatively,²¹ and if possible, significant cardiac issues should be corrected before surgery.

Pulmonary. The leading cause of postoperative morbidity and mortality in patients undergoing TAAA repair is respiratory failure.⁹ Pulmonary function must be carefully evaluated because one-lung ventilation is essential for surgical repair of extent I, II, and III aneurysms. Because an aneurysm can distort the left mainstem bronchus, chest x-ray and computed tomography scan may give vital information regarding double lumen endotracheal tube placement. If feasible, patients who are actively smoking should be advised to quit at least 4 weeks before surgery.²² Patients showing good response to bronchodilators should be started on the same preoperatively to improve pulmonary function. Patients with poor diffusing capacity or severe chronic obstructive pulmonary disease may require the use of cardiopulmonary bypass for TAAA repair because they may not tolerate one-lung ventilation. Patients should be evaluated for a preoperative history of right recurrent laryngeal nerve damage because it is not uncommon for the left recurrent laryngeal nerve to be damaged during TAAA repair, which could lead to respiratory compromise upon extubation (fig. 3).

Renal. Preoperative renal insufficiency in patients undergoing open TAAA repair is an independent predictor of postoperative renal failure and mortality.^{2,3,9} Thus, baseline renal function should be assessed. Among patients presenting for TAAA repair, 13–24% have baseline renal insufficiency (serum creatinine more than 1.5 mg/dl), pri-

Table 1. Perioperative Considerations for the Major Organ Systems Involved in Thoracoabdominal Aortic Aneurysm Repair

System	Preoperative	Intraoperative	Postoperative
CV	Assess aneurysm extent	Adequate IV access/invasive monitoring	BP control to ensure SCPP
	Cardiac evaluation per AHA/ACC guidelines β -blockade per AHA/ACC guidelines	BP control to prevent aneurysm rupture Manage hemodynamic changes of aortic clamping/unclamping, LHB or CPB	Monitor for signs of myocardial dysfunction
Pulmonary	Consider statin therapy Smoking cessation 4–6 weeks	DLT placement	Airway edema (consider leaving DLT in place) RLN injury possible
	Assess tracheobronchial involvement of aneurysm Discuss possibility of tracheostomy	Considerations of single lung ventilation, including use of CPAP, PEEP, bronchodilators,	Pulmonary edema, TRALI, ARDS possible
Renal	Assess preexisting renal dysfunction	Renal protection strategies (e.g., hypothermia, distal aortic perfusion, cold crystalloid perfusate)	Monitor for signs of renal failure
	Discuss possibility of postoperative renal failure		Hemodialysis possible
CNS	Assess baseline neurologic status; document deficits	Neuroprotection strategies (e.g., permissive hypothermia, LHB, CSF drainage, epidural cooling, reimplantation of intercostal arteries, deep hypothermia)	Assess and monitor neurologic status
	Discuss potential for paralysis	Neuromonitoring (SSEPs, MEPs)	Maintain SCPP (via BP and CSF drainage)
Hematology	Baseline SSEPs, MEPs		
	Assess coagulation status and use of anticoagulant/antiplatelet drugs	Systemic heparinization (LHB)	Coagulation monitoring
	Discuss likelihood of blood transfusion	Antifibrinolytic therapy	Ensure normal coagulation and platelet count/function before removal of CSF catheter
	Type and cross-match —	Potential for massive transfusion Protamine considerations	

ACC = American College Cardiology; AHA = American Heart Association; ARDS = acute respiratory distress syndrome; BP = blood pressure; CNS = central nervous system; CPAP = continuous positive airway pressure; CPB = cardiopulmonary bypass; CSF = cerebrospinal fluid; CV = cardiovascular; DLT = double lumen tube; IV = intravenous; LHB = left heart bypass; MEPs = motor-evoked potentials; PEEP = positive end-expiratory pressure; RLN = recurrent laryngeal nerve; SCPP = spinal cord perfusion pressure; SSEPs = somatosensory-evoked potentials; TRALI = transfusion related acute lung injury.

marily related to hypertension, diabetes, and atherosclerotic disease. Because thoracoabdominal aneurysms involve the visceral and juxtarenal aorta, renovascular disease is often encountered. Urgency of the surgery, preoperative renal dysfunction, increased aortic cross clamp time, and advanced age are independent predictors of acute postoperative renal failure after TAAA repair, with an overall incidence of 7–40%.¹⁷

Radiologic Evaluation. Complete radiographic evaluation of the aorta is necessary for surgical planning. Studies may include computed tomography, contrast arteriography, and magnetic resonance angiography. All iodinated contrast studies should be performed in advance of the

planned procedure to avoid contrast-related renal dysfunction. Patients with baseline renal insufficiency may receive *N*-acetylcysteine to reduce the risk of contrast-related nephropathy and progressive renal failure. Preoperative assessment of the aneurysm anatomy and of the major branches is critical.²³ Computed tomography angiography and magnetic resonance angiography detect the arteria radicularis magna (ARM), also known as the artery of Adamkiewicz, in only 50–80% of patients. This is significant as the risk of postoperative paraplegia is 5% if the artery of Adamkiewicz is identified preoperatively and reimplanted, whereas it is as high as 50% if the artery is not identified and reattached.

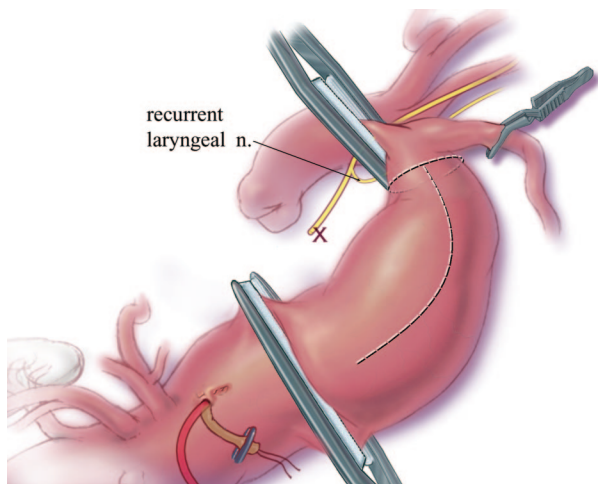


Fig. 3. Relationship between the left recurrent laryngeal nerve and the aortic arch. The left recurrent laryngeal nerve is susceptible to injury with aortic cross-clamping during thoracoabdominal aortic aneurysm repair involving the distal aortic arch and proximal descending aorta. Reproduced with permission from Coselli JS, LeMaire SA: Tips for successful outcomes for descending thoracic and thoracoabdominal aortic aneurysm procedures. *Semin Vasc Surg* 2008;21:13–20. Copyright Elsevier.

Intraoperative Management

Monitors and Left Heart Bypass. Central to the successful management of patients undergoing TAAA repair is the ability to quickly respond to hemodynamic changes and volume shifts. Preoperative anxiety or pain from placement of invasive monitoring lines can result in an increase of the patient's blood pressure and heart rate, which may increase the risk of potential aneurysm rupture. Thus, adequate preoperative sedation before induction for line placement is indicated where tolerated. The right radial artery is the preferred location for arterial monitoring because a left radial arterial line would be compromised if the aortic cross-clamp is placed proximal to the left subclavian artery. Although rare, an unrepaired aberrant right subclavian artery could pose a challenge to blood pressure monitoring in similar fashion. In this situation, collaboration between the anesthesiologist and the surgeon is required to determine the best site for arterial blood pressure monitoring. A concurrent femoral arterial line can also be placed to monitor distal aortic perfusion if LHB is to be used.

To obtain sufficient central venous access, a “double-stick” technique is often used in which two introducers are placed in the same central vein after induction, along with a pulmonary artery catheter. A rapid infusion device is also essential to manage volume shifts and need for rapid transfusion during TAAA repair. Transesophageal echocardiography can also be a valuable adjunct for monitoring fluid shifts and ventricular function.

LHB has proven benefit for repair of extent I and II TAAAs (fig. 4).²⁴ Although LHB has been used for extent III and IV TAAA repairs, its benefit has not been reliably demonstrated. LHB entails bypass of oxygenated blood from the

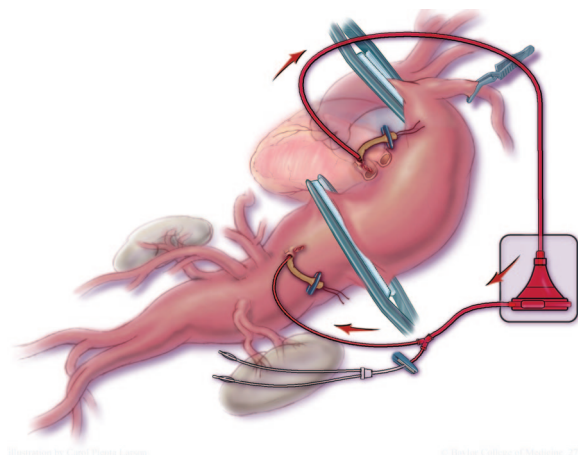


Fig. 4. Left heart bypass. Left heart bypass involves partial bypass of oxygenated blood from the left atrium or pulmonary veins to the distal aorta or femoral artery during thoracoabdominal aortic aneurysm repair. Reproduced with permission from Coselli JS, LeMaire SA: Tips for successful outcomes for descending thoracic and thoracoabdominal aortic aneurysm procedures. *Semin Vasc Surg* 2008;21:13–20. Copyright Elsevier.

left atrium to the distal aorta or femoral artery, maintaining spinal cord, renal, mesenteric, and lower extremity perfusion during proximal aortic clamping.^{24–25} LHB is instituted before aortic cross-clamping to reduce preload to the left ventricle, such that the abrupt rise in blood pressure that typically occurs with aortic cross-clamping is curtailed minimizing the use of vasodilators.

Antifibrinolytic Therapy. Supraceliac aortic cross-clamping is associated with the development of primary fibrinolysis, which can lead to coagulopathy.²⁶ Thus, antifibrinolytic therapy is recommended for TAAA repair. However, there are few actual data to suggest efficacy of this practice (largely because randomized controlled trials are difficult to perform in this population).²⁷ Either ϵ -aminocaproic acid or tranexamic acid are considered viable options for antifibrinolytic therapy.

Hemodynamic Changes with Aortic Cross-Clamping. The most profound hemodynamic response to aortic cross-clamping is an increase in arterial blood pressure, which is attributed to an increase in afterload.¹⁹ Generally, the more proximal the aortic clamp, the more extreme the augmentation of blood pressure. Clamping of the supraceliac aorta is associated with significant increases in MAP, left ventricular filling pressures, and end-systolic/diastolic volumes.¹⁹ Nicardipine, nitroglycerin, nitroprusside, and/or the vasodilating properties of inhaled volatile agents may be used to help offset the increase in afterload seen with aortic cross-clamping. Left ventricular wall motion abnormalities and diastolic dysfunction occur in more than 50% of cases where a supraceliac aortic cross-clamp is used.²⁰ Also seen with supraceliac aortic clamping is passive venous recoil and catecholamine release, both of which lead to decreased venous capacitance. As a result, blood from the splanchnic and other

vascular beds below the level of the aortic cross-clamp are expelled back to the heart, thereby increasing preload, and subsequently, cardiac output.¹⁹ With prolonged duration of the aortic cross-clamp, systemic vascular resistance increases and cardiac output decreases.¹⁹

Increases in myocardial preload and afterload secondary to supraceliac aortic cross-clamping lead to an increase in myocardial contractility and oxygen demand.¹⁹ The response by the heart is to increase myocardial oxygen supply by increasing coronary blood flow.¹⁹ Thus, although the increase in blood pressure in response to aortic cross-clamping must be managed judiciously, care must be taken to ensure arterial blood pressure is not overly reduced, which may result in decreased coronary artery, cerebral, spinal cord, renal, and/or mesenteric perfusion. Indeed, in situations where LHB is not used, blood pressure distal to the aortic cross-clamp is directly reliant upon blood pressure proximal to the cross-clamp.¹⁹ During aortic cross-clamping, distal blood flow occurs *via* collateral vessels and is primarily dependent on pressure rather than cardiac output.¹⁹ Thus, proximal and distal aortic pressures should be maintained at levels to ensure adequate end-organ perfusion when LHB is not used. Johnston *et al.* showed that application of 15 cmH₂O positive end-expiratory pressure with aortic cross-clamping reduces the hypertensive response typically seen and allows for concomitant volume expansion, which results in better maintenance of stroke volume and blood pressure after clamp removal.²⁸

Hemodynamic Changes with Unclamping of the Aorta.

The primary hemodynamic derangement typically seen with aortic cross-clamp release is decreased systemic vascular resistance and arterial blood pressure.¹⁹ The hypotension seen with unclamping is multifactorial.¹⁹ Blood volume redistribution to the lower extremities leads to central hypovolemia. Hypoperfusion of tissues distal to the aortic cross-clamp leads to accumulation of vasoactive and myocardial-depressant metabolites (*e.g.*, lactate), which are released upon cross-clamp removal. Hypotension after aortic cross-clamp release can be combated with volume loading, infusion of vasoactive medications, prompt treatment of metabolic abnormalities, minimized the aortic clamp time, and gradual release of aortic cross-clamp.¹⁹ Sodium bicarbonate may be given to counteract this metabolic acidosis, but should be given cautiously in the setting of a mixed respiratory acidosis. Generally, it is advisable to maintain a higher blood pressure than normal after cross-clamp release to ensure adequate renal and spinal cord perfusion.²⁹ However, the fact that TAAA repair involves multiple suture lines and is prone to bleeding must also be taken into consideration when determining the optimal blood pressure; this is a particularly important consideration in patients with extremely fragile aortic tissue, such as those with Marfan syndrome.

Renal Protection. Methods used for renal protection include maintaining distal aortic perfusion during aortic cross-clamping, as well as running cold perfusate into the renal arteries

during periods of ischemia. Köksoy *et al.* demonstrated that cold crystalloid renal perfusate confers superior protection compared with isothermic blood perfusate for preventing acute postoperative renal dysfunction after TAAA repair.³⁰ Subsequently, LeMaire *et al.* showed that 4°C crystalloid, along with mannitol and methylprednisolone, intermittently perfused into the renal arteries consistently yielded kidney temperatures less than 28°C and provided protection against postoperative renal dysfunction.¹¹ Because there is a strong association between distal aortic pressure and renal blood flow,¹⁹ LHB can be used to maintain the perfusion pressure during aortic cross-clamping. The use of mannitol or dopamine for preserving renal function is controversial and has not been shown to reduce the incidence of postoperative renal dysfunction.³¹ Indigo carmine dye and furosemide may be administered upon return of renal perfusion to assess both renal perfusion and ureter patency. If dye is not noted in the urine within 30 min, correctable surgical causes such as kinked renal artery or ureter should be sought.

Neuroprotection. A devastating complication of TAAA repair is paraplegia, with incidences ranging from 2.7–20%.^{2,4–6,16,31,32} Not only is paraplegia associated with significant morbidity, but also increased mortality.^{4,16} CSF drainage, maintenance of MAP, LHB, hypothermia, and reimplantation of intercostal/radicular arteries have proven effective in decreasing the incidence of paraplegia.^{4–5,24,32–35} However, no single method has proved entirely effective.

The spinal cord derives its blood supply from a single anterior spinal artery (ASA) and two posterior spinal arteries. The ASA supplies the anterior two thirds of the spinal cord, which is the motor region. The posterior spinal arteries supply the dorsal third of the spinal cord, which is the sensory region (fig. 5). The cervical region of the ASA receives its blood supply primarily from the vertebral arteries. The thoracic region of the ASA is supplied by radicular arteries. The ARM is the largest and most important of the radicular vessels supplying the ASA, and originates between T9 and T12 in most people. However, in some individuals, anastomosis may occur at a higher thoracic level or even lumbar level. Svensson *et al.* showed that the diameter of the ASA is smaller above the entry point of the ARM, and larger below its entry.³⁶ As a result, blood flow resistance is 52 times greater traveling up the ASA compared with traveling below the ARM entry. Therefore, distal aortic perfusion during aortic cross-clamping primarily has beneficial effects on spinal cord perfusion below the ARM, but decreased benefit above the ARM. Preoperative radiologic ARM identification provides useful information allowing for successful reimplantation and improved spinal cord function.^{23,37}

Neuromonitoring techniques such as somatosensory-evoked potentials and motor-evoked potentials (MEPs) may be used to detect spinal cord ischemia. Somatosensory-evoked potentials are typically used to monitor the integrity of the posterior (sensory) spinal cord, and MEPs are used to detect dysfunction of the anterior (motor) spinal cord. MEPs

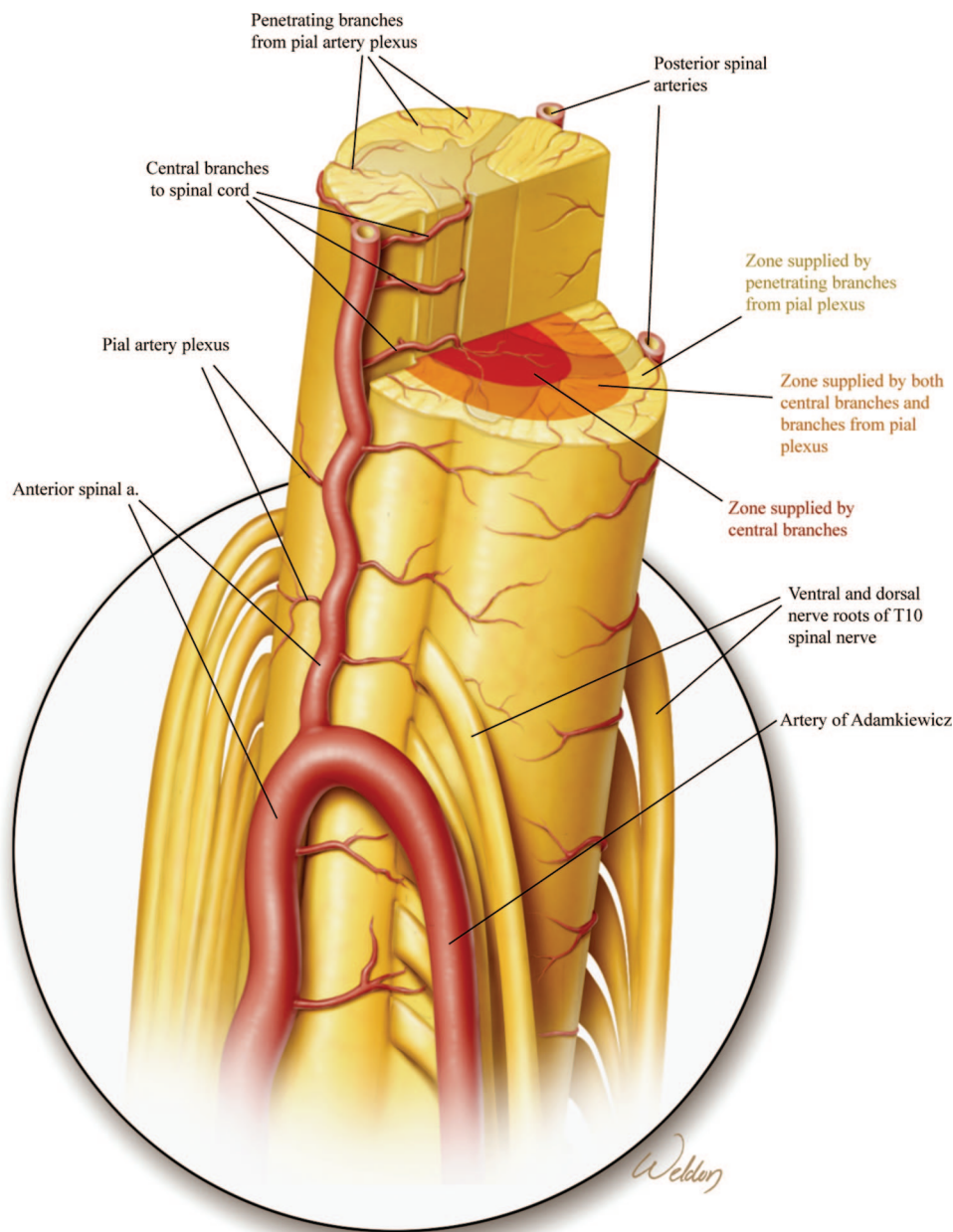


Fig. 5. Spinal cord blood supply. A single anterior spinal artery supplies the anterior two thirds of the spinal cord, and two posterior spinal arteries supply the posterior third of the spinal cord. The artery of Adamkiewicz is the largest radicular artery supplying the spinal cord, and is considered to play an integral role in preservation of spinal cord function.

in particular have been shown to aid in detecting early spinal cord ischemia and improving neurologic outcomes in TAAA repairs,^{10,37–40} especially when used in conjunction with LHB and CSF drainage.³⁷ Using MEP monitoring, Shine *et al.* showed that the length of MEP signal loss during aortic cross-clamping directly correlated with the risk of paralysis.¹⁰ However, there are limitations and drawbacks for the use of somatosensory-evoked potentials and MEPs for these procedures, and they are not standard practice at all institutions.⁴¹

CSF drainage has been shown to substantially reduce the risk of paraplegia in patients undergoing TAAA repairs, particularly extents I, II, and possibly III.⁴ Spinal cord perfusion

pressure is equal to MAP-CSF pressure. With placement of an aortic cross-clamp there is a compensatory rise in venous pressure, resulting in increased intraspinal venous congestion causing a rise in CSF pressure.⁴² Therefore, measures to increase the MAP or decrease the CSF pressure will augment spinal cord perfusion pressure. By removing CSF, intrathecal pressure is decreased, thereby improving spinal cord perfusion pressure. CSF drainage occurs *via* a spinal drain, placed in the lower lumbar region, with a goal of maintaining a CSF pressure approximately 10–15 mmHg.⁴ In 326 patients who underwent TAAA, extent II repair, Coselli found that the incidence of paraplegia to be 4.8% in patients in which LHB

was used, compared with 13.1% in patients which LHB was not used.²⁴ Combined use of LHB and CSF drainage may thus reduce the incidence of paraplegia in comparison with use of each alone.⁵⁻⁷ Finally, reports have also shown the benefits of a CSF drain placed postoperatively in patients who develop delayed-onset paraplegia in whom a spinal drain was not present intraoperatively.⁴³ At our institution, CSF drains are routinely placed after induction of general anesthesia. Although this procedure may be controversial, we think it presents minimal risk due to low lumbar placement (no complications have been reported) and avoids evoking a strong sympathetic response in an awake patient that could risk TAAA rupture/leak.

Although there is clear benefit of CSF drainage in patients undergoing TAAA repair,⁴ it is not without risk. Dardik *et al.* revealed a 3.5% incidence of subdural hematomas in patients undergoing CSF drainage, which also strongly correlated with the amount of CSF drained.²⁵ In their study, patients who developed a subdural hematoma had on average 690 ± 79 ml CSF removed, whereas those patients who did not develop a subdural hematoma had on average of 359 ± 24 ml removed. Other potential complications of CSF drainage include meningitis, spinal or epidural hematomas, and post-dural puncture headache.

Intentional hypothermia may also convey protective benefit to the spinal cord and central nervous system by reducing both metabolic rate and the oxygen requirement.⁴⁴ In an animal model, Strauch *et al.* found that mild hypothermia to 32°C yielded a doubling of the spinal cord ischemic tolerance.⁴⁴ For TAAA repairs at our institution, permissive hypothermia is achieved by allowing the patient's core temperature to drift to 32°C. Monitoring of core temperature may include any of the following sites: pulmonary artery, distal esophagus, tympanic membrane, or nasopharynx.⁴⁵ Systemic hypothermia *via* cardiopulmonary bypass and circulatory arrest and regional spinal cord cooling *via* epidural infusion of cold saline have also been reported to improve outcomes.^{8,34}

Intercostal artery reimplantation is another technique that has helped to reduce devastating neurologic events in patients undergoing TAAA repair. Acher *et al.* found that intercostal reimplantation decreased the incidence of paralysis from 4.8–0.9% when combined with other neuroprotective adjuncts.³⁵ In a small trial, Woo *et al.* reported a 0% incidence of paraplegia using intercostal reimplantation.³⁸ Similarly, Etz *et al.* recently showed that staged TAAA repair may improve neurologic outcome. Of 35 patients who underwent a two-stage TAAA extent I repair, none became paralyzed.⁴⁶ No matter what neuroprotection techniques are used, it is vital that the patient undergoing TAAA repair be awakened shortly after completion of the surgery to assess neurologic status.

Knowledge Gap

Another extremely promising and burgeoning area of TAAA management involves the use of endovascular technology in

hope of reducing the physiologic insult associated with traditional open repair.⁴⁷⁻⁴⁹ Thoracic endovascular aneurysm repair could be particularly useful when treating high-risk patients with significant coexistent morbidities, many of whom are not considered candidates for open repair. To date, several thoracic endovascular aneurysm repair studies have yielded positive short-term to mid-term results, with low morbidity and mortality rates.⁴⁷ Although the thoracic endovascular aneurysm repair approach offers relative surgical simplicity, one must always be ready to convert to open TAAA repair should the endovascular approach be untenable or if the patient becomes hemodynamically unstable secondary to aneurysm rupture.⁴⁷

Endovascular TAAA repair is not without limitations. Thoracic endovascular aneurysm repair necessitates the use of specialized grafts that feature fenestrations and/or branches that facilitate perfusion of the visceral arteries that arise from the excluded aortic segment. As an alternative, several centers have explored the utility of hybrid procedures, which comprise an open surgical procedure to create extra-anatomic bypasses to the branch arteries, and an endovascular procedure to exclude the entire TAAA with stentgrafts. The results of hybrid TAAA repairs have yielded outcomes similar to that of open repair, but data are sparse.⁴⁷ Finally, it should be noted that patients who undergo thoracic endovascular aneurysm repair require long-term surveillance and commonly require reintervention secondary to graft migration or endoleak.⁴⁷ Overcoming the current limitations of endovascular TAAA repair is an area of intensive investigation that promises to increase availability of treatment options to patients who otherwise would not be considered candidates for aneurysm repair.

Although extensive progress has been made over the past decades in reducing the TAAA surgical complication rate, continued research efforts are needed to further reduce and eliminate devastating sequelae; in particular, paraplegia and renal failure. Although focused efforts to prevent ischemic injury of the spinal cord have led to a substantial reduction in the risk of immediate paraplegia, delayed deficits remain a vexing problem.⁵⁰ Recent studies by Etz *et al.* have provided insight into the extensive collateral network that helps maintain spinal cord perfusion after segmental arteries are ligated during TAAA repair.⁵¹ The effect of hyperglycemia on spinal cord injury is also of interest; hyperglycemia has been shown to have deleterious effects in patients with ischemic strokes.⁵² It is feasible that similar mechanisms seen in hyperglycemia-associated cerebral injuries could contribute to poorer neurologic outcomes in patients undergoing TAAA repair. In addition, both hypercapnia and hypocapnia can have profound effects on the cerebral vasculature, cerebral blood flow, and intracranial pressure. Perhaps investigation into carbon dioxide and spinal cord blood flow and its effects on neurologic outcome for TAAA surgery would reveal an optimal level for which arterial carbon dioxide tension should be

maintained in patients undergoing TAAA repair to minimize ischemic injury.

Compared with the large number of studies related to spinal cord protection during TAAA repair, research focusing on renal protection in this setting is quite limited. Consequently, major progress in preventing renal failure after TAAA repair remains elusive. The principal strategies for protecting the kidneys during TAAA repair are maintaining renal hypothermia during the ischemic period, maintaining adequate perfusion pressure, and avoiding administration of nephrotoxic agents. Other than these basic approaches to kidney protection, few modalities to prevent renal failure to date have been successful. Interestingly, there is evidence that chronic statin therapy decreases the likelihood of postoperative myocardial infarction, stroke, and renal dysfunction in patients undergoing aortic surgery.⁵³

Conclusion

We present a patient who underwent extent II TAAA repair, using permissive hypothermia, LHB, CSF drainage, and cold crystalloid renal perfusion. Although data analyzing this method or similar variations for TAAA repair are favorable, it should be noted that data also exist for other strategies. For example, Kouchoukos *et al.* demonstrated good results for TAAA repair using hypothermic total cardiopulmonary bypass, supplemented with periods of circulatory arrest.⁸ This technique offers the potential benefit of providing protection against brain, cardiac, renal, visceral, and spinal dysfunction without having to use adjuncts such as LHB, CSF drainage, selective perfusion of renal and visceral arteries, regional spinal cooling, or sequential aortic clamping. Thus, TAAA repair (open or endovascular) remains a significant clinical management challenge, and although no one technique has eliminated all complications, significant headway has been achieved in decreasing morbidity and mortality.

The authors thank Scott A. Weldon, M.A., C.M.I., and Kristy Beal, Clinical Assistant, for creating the illustrations.

References

- Cowan JA Jr, Dimick JB, Henke PK, Huber TS, Stanley JC, Upchurch GR Jr: Surgical treatment of intact thoracoabdominal aortic aneurysms in the United States: Hospital and surgeon volume-related outcomes. *J Vasc Surg.* 2003; 37:1169-74
- Coselli JS, LeMaire SA, Miller CC 3rd, Schmittling ZC, Köksoy C, Pagan J, Curling PE: Mortality and paraplegia after thoracoabdominal aortic aneurysm repair: A risk factor analysis. *Ann Thorac Surg* 2000; 69:409-14
- LeMaire SA, Miller CC 3rd, Conklin LD, Schmittling ZC, Köksoy C, Coselli JS: A new predictive model for adverse outcomes after elective thoracoabdominal aortic aneurysm repair. *Ann Thorac Surg* 2001; 71:1233-8
- Coselli JS, LeMaire SA, Köksoy C, Schmittling ZC, Curling PE: Cerebrospinal fluid drainage reduces paraplegia after thoracoabdominal aortic aneurysm repair: Results of a randomized clinical trial. *J Vasc Surg* 2002; 35:631-9
- Estrera AL, Miller CC 3rd, Chen EP, Meada R, Torres RH, Porat EE, Huynh TT, Azizzadeh A, Safi HJ: Descending thoracic aortic aneurysm repair: 12-year experience using distal aortic perfusion and cerebrospinal fluid drainage. *Ann Thorac Surg* 2005; 80:1290-6; discussion 1296
- Safi HJ, Estrera AL, Miller CC, Huynh TT, Porat EE, Azizzadeh A, Meada R, Goodrick JS: Evolution of risk for neurologic deficit after descending and thoracoabdominal aortic repair. *Ann Thorac Surg* 2005; 80:2173-9; discussion 2179
- Safi HJ, Miller CC 3rd, Huynh TT, Estrera AL, Porat EE, Winnerkvist AN, Allen BS, Hassoun HT, Moore FA: Distal aortic perfusion and cerebrospinal fluid drainage for thoracoabdominal and descending thoracic aortic repair: Ten years of organ protection. *Ann Surg* 2003; 238:372-81; discussion 380-1
- Kouchoukos NT, Masetti P, Rokkas CK, Murphy SF, Blackstone EH: Safety and efficacy of hypothermic cardiopulmonary bypass and circulatory arrest for operations on the descending thoracic and thoracoabdominal aorta. *Ann Thorac Surg* 2001; 72:699-708
- Coselli JS, LeMaire SA, Conklin LD, Köksoy C, Schmittling ZC: Morbidity and mortality after extent II thoracoabdominal aortic aneurysm repair. *Ann Thorac Surg* 2002; 73:1107-15; discussion 1115-6
- Shine TS, Harrison BA, De Ruyter ML, Crook JE, Heckman M, Daube JR, Stapelfeldt WH, Cherry KJ, Gloviczki P, Bower TC, Murray MJ: Motor and somatosensory evoked potentials: Their role in predicting spinal cord ischemia in patients undergoing thoracoabdominal aortic aneurysm repair with regional lumbar epidural cooling. *ANESTHESIOLOGY* 2008; 108:580-7
- LeMaire SA, Jones MM, Conklin LD, Carter SA, Criddell MD, Wang XL, Raskin SA, Coselli JS: Randomized comparison of cold blood and cold crystalloid renal perfusion for renal protection during thoracoabdominal aortic aneurysm repair. *J Vasc Surg* 2009; 49:11-9; discussion 19
- Isselbacher EM: Thoracic and abdominal aortic aneurysms. *Circulation* 2005; 111:816-28
- Dapunt OE, Galla JD, Sadeghi AM, Lansman SL, Mezrow CK, de Asla RA, Quintana C, Wallenstein S, Ergin AM, Griep RB: The natural history of thoracic aortic aneurysms. *J Thorac Cardiovasc Surg* 1994; 107:1323-33
- Davies RR, Goldstein LJ, Coady MA, Tittle SL, Rizzo JA, Kopf GS, Elefteriades JA: Yearly rupture or dissection rates for thoracic aortic aneurysms: Simple prediction based on size. *Ann Thorac Surg* 2002; 73:17-28
- Crawford ES, DeNatale RW: Thoracoabdominal aortic aneurysm: Observations regarding the natural course of the disease. *J Vasc Surg* 1986; 3:578-82
- Black JH 3rd, Cambria RP: Contemporary results of open surgical repair of descending thoracic aortic aneurysms. *Semin Vasc Surg* 2006; 19:11-17
- Svensson LG, Crawford ES, Hess KR, Coselli JS, Safi HJ: Experience with 1509 patients undergoing thoracoabdominal aortic operations. *J Vasc Surg* 1993; 17:357-68; discussion 368-70
- Hafez HM, Berwanger CS, McColl A, Richmond W, Wolfe JH, Mansfield AO, Stansby G: Myocardial injury in major aortic surgery. *J Vasc Surg* 2000; 31:742-50
- Gelman S: The pathophysiology of aortic cross-clamping and unclamping. *ANESTHESIOLOGY* 1995; 82:1026-60
- Fayad A, Yang H, Nathan H, Bryson GL, Cina CS: Acute diastolic dysfunction in thoracoabdominal aortic aneurysm surgery. *Can J Anaesth* 2006; 53:168-73
- Flu WJ, van Kuijk JP, Hoeks SE, Kuiper R, Schouten O, Goei D, Elhendy A, Verhagen HJ, Thomson IR, Bax JJ, Fleisher LA, Poldermans D: Prognostic implications of asymptomatic left ventricular dysfunction in patients undergoing vascular surgery. *ANESTHESIOLOGY* 2010; 112:1316-24
- Mills E, Eyawo O, Lockhart I, Kelly S, Wu P, Ebbert JO: Smoking cessation reduces postoperative complications: A

- systemic review and meta-analysis. *Am J Med* 2011; 124: 144-54
23. Nijenhuis RJ, Jacobs MJ, Schurink GW, Kessels AG, van Engelshoven JM, Backes WH: Magnetic resonance angiography and neuromonitoring to assess spinal cord blood supply in thoracic and thoracoabdominal aortic aneurysm surgery. *J Vasc Surg* 2007; 45:71-7; discussion 77-8
 24. Coselli JS: The use of left heart bypass in the repair of thoracoabdominal aortic aneurysms: Current techniques and results. *Semin Thorac Cardiovasc Surg* 2003; 15:326-32
 25. Dardik A, Perler BA, Roseborough GS, Williams GM: Subdural hematoma after thoracoabdominal aortic aneurysm repair: An underreported complication of spinal fluid drainage? *J Vasc Surg* 2002; 36:47-50
 26. Illig KA, Green RM, Ouriel K, Riggs PN, Bartos S, Whorf R, DeWeese JA, Chhibber A, Marder VJ, Francis CW: Primary fibrinolysis during supraceliac aortic clamping. *J Vasc Surg* 1997; 25:244-51; discussion 252-4
 27. Shore-Lesserson L, Bodian C, Vela-Cantos F, Silvaj G, Reich DL: Antifibrinolytic use and bleeding during surgery on the descending thoracic aorta: A multivariate analysis. *J Cardiothorac Vasc Anesth* 2005; 19:453-8
 28. Johnston WE, Conroy BP, Miller GS, Lin CY, Deyo DJ: Hemodynamic benefit of positive end-expiratory pressure during acute descending aortic occlusion. *ANESTHESIOLOGY* 2002; 97:875-81
 29. Izumi S, Okada K, Hasegawa T, Omura A, Munakata H, Matsumori M, Okita Y: Augmentation of systemic blood pressure during spinal cord ischemia to prevent postoperative paraplegia after aortic surgery in a rabbit model. *J Thorac Cardiovasc Surg* 2010; 139:1261-8
 30. Köksoy C, LeMaire SA, Curling PE, Raskin SA, Schmittling ZC, Conklin LD, Coselli JS: Renal perfusion during thoracoabdominal aortic operations: Cold crystalloid is superior to normothermic blood. *Ann Thorac Surg* 2002; 73:730-8
 31. Pass IJ, Eberhart RC, Brown JC, Rohn GN, Estrera AS: The effect of mannitol and dopamine on the renal response to thoracic aortic cross-clamping. *J Thorac Cardiovasc Surg* 1988; 95:608-12
 32. LeMaire SA, Miller CC 3rd, Conklin LD, Schmittling ZC, Coselli JS: Estimating group mortality and paraplegia rate after thoracoabdominal aortic aneurysm repair. *Ann Thorac Surg* 2003; 75:508-13
 33. Ling E, Arellano R: Systematic overview of the evidence supporting the use of cerebrospinal fluid drainage in thoracoabdominal aneurysm surgery for prevention of paraplegia. *ANESTHESIOLOGY* 2000; 93:1115-22
 34. Cambria RP, Clouse WD, Davison JK, Dunn PF, Corey M, Dorer D: Thoracoabdominal aneurysm repair: Results with 337 operations performed over a 15-year interval. *Ann Surg* 2002; 236:471-9; discussion 479
 35. Acher CW, Wynn MM, Mell MW, Tefera G, Hoch JR: A quantitative assessment of the impact of intercostal artery reimplantation on paralysis risk in thoracoabdominal aortic aneurysm repair. *Ann Surg* 2008; 248:529-40
 36. Svensson LG, Rickards E, Coull A, Rogers G, Fimmel CJ, Hinder RA: Relationship of spinal cord blood flow to vascular anatomy during thoracic aortic cross-clamping and shunting. *J Thorac Cardiovasc Surg* 1986; 91:71-8
 37. Jacobs MJ, Elenbaas TW, Schurink GW, Mess WH, Mochtar B: Assessment of spinal cord integrity during thoracoabdominal aortic aneurysm repair. *Ann Thorac Surg* 2002; 74:S1864-6; discussion S1892-8
 38. Woo EY, Mcgarvey M, Jackson BM, Bavaria JE, Fairman RM, Pochettino A: Spinal cord ischemia may be reduced *via* a novel technique of intercostal artery revascularization during open thoracoabdominal aneurysm repair. *J Vasc Surg* 2007; 46:421-6
 39. Dong CJ, MacDonald DB, Janusz MT: Intraoperative spinal cord monitoring during descending thoracic and thoracoabdominal aneurysm surgery. *Ann Thorac Surg* 2002; 74: S1873-6; discussion S1892-8
 40. Jacobs MJ, de Mol BA, Elenbaas T, Mess WH, Kalkman CJ, Schurink GW, Mochtar B: Spinal cord blood supply in patients with thoracoabdominal aortic aneurysms. *J Vasc Surg* 2002; 35:30-7
 41. Coselli JS, Tsai PI: Motor evoked potentials in thoracoabdominal aortic surgery: CON. *Cardiol Clin* 2010; 28:361-8
 42. Drenger B, Parker SD, Frank SM, Beattie C: Changes in cerebrospinal fluid pressure and lactate concentrations during thoracoabdominal aortic aneurysm surgery. *ANESTHESIOLOGY*. 1997; 86:41-7
 43. Cheung AT, Weiss SJ, McGarvey ML, Stecker MM, Hogan MS, Escherich A, Bavaria JE: Interventions for reversing delayed-onset postoperative paraplegia after thoracic aortic reconstruction. *Ann Thorac Surg* 2002; 74:413-19; discussion 420-1
 44. Strauch JT, Lauten A, Spielvogel D, Rinke S, Zhang N, Weisz D, Bodian CA, Griep RB: Mild hypothermia protects the spinal cord from ischemic injury in a chronic porcine model. *Eur J Cardiothorac Surg* 2004; 25:708-15
 45. Sessler DI: Temperature monitoring and perioperative thermoregulation. *ANESTHESIOLOGY* 2008; 109:318-38
 46. Etz CD, Zoli S, Mueller CS, Bodian CA, Di Luozzo G, Lazala R, Plestis KA, Griep RB: Staged repair significantly reduces paraplegia rate after extensive thoracoabdominal aortic aneurysm repair. *J Thorac Cardiovasc Surg* 2010; 139:1464-72
 47. Scali ST, Goodney PP, Walsh DB, Travis LL, Nolan BW, Goodman DC, Lucas FL, Stone DH: National trends and regional variation of open and endovascular repair of thoracic and thoracoabdominal aneurysms in contemporary practice. *J Vasc Surg* 2011; 53:1499-505
 48. Bakoyiannis CN, Economopoulos KP, Georgopoulos S, Klonaris C, Shialarou M, Kafeza M, Papanambros E: Fenestrated and branched endografts for the treatment of thoracoabdominal aortic aneurysms: A systematic review. *J Endovasc Ther* 2010; 17:201-9
 49. Greenberg R, Eagleton M, Mastracci T: Branched endografts for thoracoabdominal aneurysms. *J Thorac Cardiovasc Surg* 2010; 140:S171-8
 50. Wong DR, Coselli JS, Amerman K, Bozinovski J, Carter SA, Vaughn WK, LeMaire SA: Delayed spinal cord deficits after thoracoabdominal aortic aneurysm repair. *Ann Thorac Surg* 2007; 83:1345-55
 51. Etz CD, Kari FA, Mueller CS, Brenner RM, Lin HM, Griep RB: The collateral network concept: Remodeling of the arterial collateral network after experimental segmental artery sacrifice. *J Thorac Cardiovasc Surg* 2011; 141:1029-36
 52. Bruno A, Liebeskind D, Hao Q, Raychev R, for the UCLA Stroke Investigators: Diabetes mellitus, acute hyperglycemia, and ischemic stroke. *Curr Treat Options Neurol* 2010; 12: 492-503
 53. Le Manach Y, Ibanez Esteves C, Bertrand M, Goarin JP, Fléron MH, Coriat P, Koskas F, Riou B, Landais P: Impact of preoperative statin therapy on adverse postoperative outcomes in patients undergoing vascular surgery. *ANESTHESIOLOGY* 2011; 114:98-104