

Ultrasound Imaging Facilitates Spinal Anesthesia in Adults with Difficult Surface Anatomic Landmarks

Ki Jinn Chin, F.R.C.P.C.,* Anahi Perlas, F.R.C.P.C.,† Vincent Chan, F.R.C.P.C.,‡
Danielle Brown-Shreves, M.B.B.S.,§ Arkadiy Koshkin, M.D.,§ Vandana Vaishnav, F.C.A.R.C.S.I.||

ABSTRACT

Background: Poor surface anatomic landmarks are highly predictive of technical difficulty in neuraxial blockade. The authors examined the use of ultrasound imaging to reduce this difficulty.

Methods: The authors recruited 120 orthopedic patients with one of the following: body mass index more than 35 kg/m² and poorly palpable spinous processes; moderate to severe lumbar scoliosis; or previous lumbar spine surgery. Patients were randomized to receive spinal anesthetic by the conventional surface landmark-guided technique (group LM) or by an ultrasound-guided technique (group US). Patients in group US had a preprocedural ultrasound scan to locate and mark a suitable needle insertion point. The primary outcome was the rate of successful dural puncture on the first needle insertion attempt. Normally distributed data were summarized as mean \pm SD and nonnormally distributed data were summarized as median [interquartile range].

Results: The first-attempt success rate was twice as high in group US than in group LM (65% *vs.* 32%; $P < 0.001$). There was a twofold difference between groups in the number of needle insertion attempts (group US, 1 [1–2] *vs.* group LM, 2 [1–4]; $P < 0.001$) and number of needle passes (group US, 6 [1–10] *vs.* group LM, 13 [5–21]; $P = 0.003$). More time was required to establish landmarks in group US (6.7 ± 3.1 ; group LM, 0.6 ± 0.5 min; $P < 0.001$), but this was partially offset by a shorter spinal anesthesia performance time (group US, 5.0 ± 4.9 *vs.* group LM, 7.3 ± 7.6 min; $P = 0.038$). Similar results were seen in subgroup analyses of

What We Already Know about This Topic

- Spinal needle insertion can be difficult in patients with spinal deformities or spinous processes that are difficult to palpate

What This Article Tells Us That Is New

- In 120 patients with obesity, moderate to severe lumbar scoliosis, or previous lumbar spinal surgery, ultrasound imaging before needle insertion added 6 min to the procedure time but reduced the number of passes for spinal needle insertion

patients with body mass index more than 35 kg/m² and patients with poorly palpable landmarks.

Conclusion: Preprocedural ultrasound imaging facilitates the performance of spinal anesthesia in the nonobstetric patient population with difficult anatomic landmarks.

NEURAXIAL blockade traditionally has been accomplished using a surface landmark-guided technique in which the approximate location of the neuraxial midline and lumbar interspinous and interlaminar spaces are determined based on palpation of the intercrystal line and the tips of the spinous processes. Not surprisingly, the technical difficulty of neuraxial blockade correlates with the quality of palpable surface landmarks.^{1–5} These surface landmarks may be absent, indistinct, or distorted in many adult patients because of obesity, previous spinal surgery, deformity, or degenerative changes of aging. Obesity, in particular, affects more than 30% of the adult population in the United States⁶ and as many as 50% of patients presenting for joint replacement surgery.^{7,8} In an audit of central neuraxial blockade performed for total hip or knee arthroplasty at our institution between 2007 and 2009, 48% of patients were 70 yr or older, and 22% had a body mass index (BMI) greater than 35 kg/m² (K.J.C., unpublished retrospective data, December 2010).

Reducing the technical difficulty of neuraxial blockade is desirable because multiple needle insertion attempts may increase the risk of complications such as postdural puncture headache, paresthesiae, and epidural hematoma.^{1,9–12} Preprocedural ultrasonography of the spine has been shown to facilitate labor epidural insertion.^{13,14} However, limited data exist on its utility in the older nonobstetric population. In a recent feasibility study of ultrasound-guided spinal anesthesia in patients undergoing total joint replacement, we consistently identified and marked the interlaminar spaces using ultrasound imaging.¹⁵ Spinal anesthesia was successful with a

* Assistant Professor, † Associate Professor, ‡ Professor, § Research Associate, || Clinical Fellow, Department of Anesthesia, Toronto Western Hospital, University of Toronto, Toronto, Ontario, Canada.

Received from the Department of Anesthesia, Toronto Western Hospital, University of Toronto, Toronto, Ontario, Canada. Submitted for publication November 3, 2010. Accepted for publication March 2, 2011. Supported by a grant from the Dean's Fund, University of Toronto, and a Merit Award grant from the Department of Anesthesia, University of Toronto. Dr. Chan receives ultrasound equipment support from Sonosite (Markham, Ontario, Canada), GE Healthcare (Mississauga, Ontario, Canada), and Philips Healthcare (Markham, Ontario, Canada).

Address correspondence to Dr. Chin: Toronto Western Hospital, McL 2–405, 399 Bathurst Street, Toronto, Ontario, M5T 2S8 Canada. gasgenie@gmail.com. This article may be accessed for personal use at no charge through the Journal Web site, www.anesthesiology.org.

Copyright © 2011, the American Society of Anesthesiologists, Inc. Lippincott Williams & Wilkins. Anesthesiology 2011; 115:94–101

single needle insertion attempt in 84% of these patients, despite that nearly half of them had poorly palpable surface landmarks. This compares favorably with large prospective cohort studies, which have found that successful neuraxial blockade is achieved on the first needle insertion attempt in only 61–64% of all patients.^{1,2,16}

The current study was designed to test the hypothesis that the ultrasound-guided technique reduces the technical difficulty of spinal anesthesia in the older nonobstetric patient population with difficult surface anatomic landmarks compared with a conventional surface landmark-guided technique.

Materials and Methods

General Description

This prospective, randomized, controlled trial investigated the impact of an ultrasound-guided technique on the ease of performance of spinal anesthesia in patients with difficult surface anatomic landmarks. The study was conducted between July 2009 and July 2010 at the Toronto Western Hospital (Toronto, Ontario) and was registered with ClinicalTrials.gov (NCT00956137) before recruitment. Approval for the study was obtained from the University Health Network Research Ethics Board, and written informed consent was obtained from all patients.

Patients presenting for elective orthopedic lower limb surgery with spinal anesthesia were considered eligible for enrollment if they had difficult surface anatomic landmarks, defined as one or more of the following: (1) poorly palpable or impalpable spinous processes and a BMI of $>35 \text{ kg/m}^2$; (2) moderate to severe lumbar scoliosis on clinical examination; (3) previous lumbar spinal surgery involving removal of two or more spinous processes of the L2–L5 vertebrae. Patients were excluded from the study if they were unable to provide informed consent or if there were clinical contraindications to neuraxial blockade.

After patients gave consent, a computer-generated block randomization schedule was used to randomize patients in a 1:1 ratio and in blocks of 10 to 1 of two treatment groups: either the conventional surface landmark-guided technique (group LM) or an ultrasound-guided technique (group US) of spinal anesthesia. Group allocation was concealed from study personnel to the time of the procedure using a system of sealed opaque envelopes. The patient, physician performing the spinal anesthesia, and outcome assessor were subsequently blinded to group allocation.

All study procedures were performed 30–45 min in advance of surgery in a room dedicated to the performance of regional block. Standard monitors (three-lead electrocardiogram, noninvasive blood pressure, and pulse oximetry) were applied, intravenous access was established, and 1–2 mg intravenous midazolam was administered as needed for anxiolysis in all patients.

Study Interventions

Spinal anesthesia was performed in patients randomized to group LM using conventional surface anatomic landmark-guided technique and a midline approach. The operator in all cases was a clinical fellow in regional anesthesia or consultant with more than 5 yr clinical experience. Patients were placed in a sitting position, whereupon the pertinent surface anatomic landmarks (iliac crests, spinous processes, interspinous gaps) were palpated to determine the location of the neuraxial midline and lumbar intervertebral spaces. The quality of the surface landmarks was graded according to the overall ease with which these landmarks could be palpated (4-point scale: easy, moderate, difficult, or impossible). The spinal anesthesia was performed with a 25-gauge, 90-mm, pencil-point needle inserted through a 20-gauge introducer needle (MED-RX® spinal anesthesia kit; Benlan, Oakville, Ontario, Canada). The operator was given the discretion to use a 25-gauge 120-mm spinal needle for the initial attempt, to make subsequent changes in the needle gauge or length, or to attempt a different lumbar intervertebral space if deemed necessary. If dural puncture was unsuccessful after four or more needle insertion attempts, the operator was allowed (but not required) to use other means to locate a lumbar interlaminar space, including a paramedian needle approach, ultrasound, a combined spinal-epidural technique, or a second anesthesiologist. Once dural puncture was achieved and confirmed by backflow of cerebrospinal fluid from the needle hub, a standard intrathecal anesthetic solution of 15 mg plain bupivacaine, 0.5%, and 100 μg morphine was injected. Success of the spinal anesthesia was determined by a motor and sensory block to the T7 dermatome or higher within 30 min of injection.

Patients randomized to group US were placed in a sitting position and had their surface anatomic landmarks assessed and graded in the same manner as that used for group LM. Before the spinal anesthesia, ultrasound imaging of the lumbar spine was performed by an anesthesiologist with experience with more than 30 ultrasound-guided neuraxial blocks, using a Sonosite M-Turbo (Sonosite, Bothell, WA) ultrasound machine and a low-frequency (2–5 MHz) curved-array probe. A systematic ultrasound scanning protocol was used, which previously was described in detail¹⁵ and is summarized briefly here. The probe was oriented longitudinally to obtain a parasagittal oblique view of the lumbosacral spine, in which the L2–L3 to L4–L5 interlaminar spaces were identified and marked by counting upward from the sacrum (fig. 1A). The probe was then rotated 90 degrees to obtain a transverse view of the lumbar spine (fig. 1B). The L2–L3 to L4–L5 interspinous and interlaminar spaces were identified by visualizing the intrathecal space between the ligamentum flavum–dura mater complex and the posterior aspect of the vertebral body. The midline (interspinous ligament) and the location of each interlaminar space were marked on the skin (fig. 1, C and D). The intersection of these two markings was used to guide a midline approach to

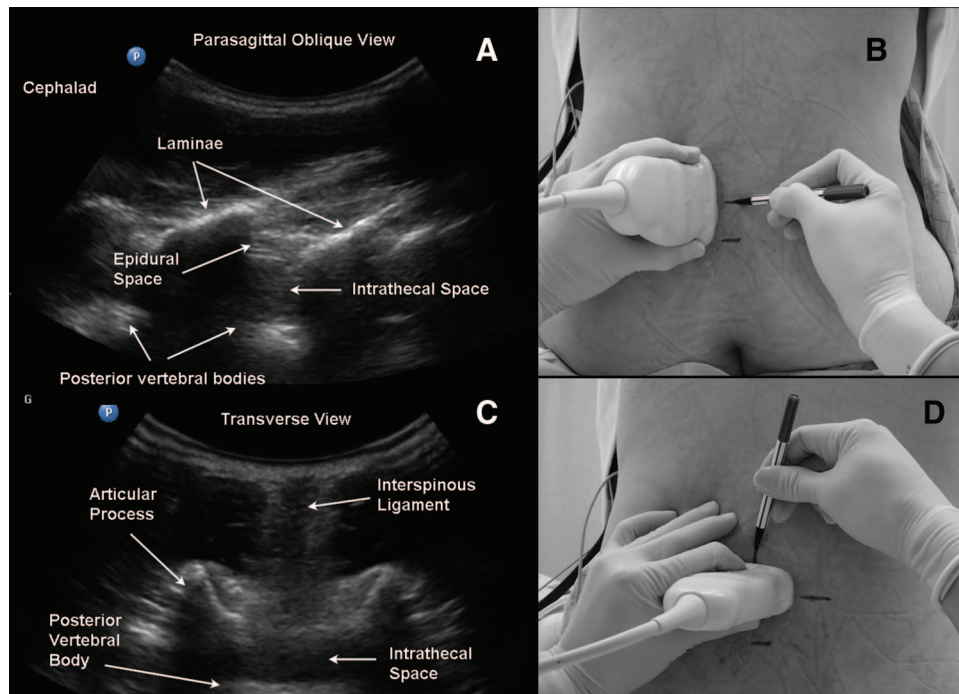


Fig. 1. In the paramedian sagittal oblique view, each lumbar interlaminar space is centered in turn on the ultrasound screen (A). A corresponding skin mark is made at the midpoint of the probe's long edge (B). The probe is then turned 90 degrees to obtain the transverse view (C). The midline is centered on the ultrasound screen, and skin marks are made at the midpoint of the probe's long and short edges (D). The intersection of these two marks provides an appropriate needle insertion point for a midline approach to the epidural or intrathecal space at that level. (From *Ultrasound Imaging for Regional Anesthesia: A Practical Guide Booklet*, 3rd edition, Ultrasound for Regional Anesthesia. Used with permission from the publisher.)

spinal anesthesia, which was performed in a manner similar to that described for group LM. Both the ultrasound scan and spinal anesthesia were performed by the same operator. The interlaminar level used for the initial attempt was left to the operator's discretion but was based in general on the relative ease with which the intrathecal space could be visualized in the transverse view.

Study Outcomes

The primary outcome was the rate of successful dural puncture on the first needle insertion attempt. A subsequent needle insertion attempt was defined as needle insertion preceded by complete withdrawal of the spinal or introducer needle from the patient's skin. In contrast, a needle redirection attempt was defined as any change in needle insertion trajectory that did not involve complete withdrawal of the needle from the patient's skin. We defined a needle pass as either a needle insertion or redirection attempt. Secondary outcomes included the following:

1. Number of needle insertion attempts required for successful dural puncture.
2. Number of needle passes (insertion + redirection attempts) required for successful dural puncture.
3. Time taken to establish landmarks. In group LM, this was defined as the period beginning when the operator first touched the patient and ending when the operator declared the examination complete. In

group US, this was defined as the period beginning when the probe was first placed on the patient and ending when the operator declared the examination complete.

4. Time taken to perform the spinal anesthesia, defined as the period between the first insertion of the needle used to infiltrate skin with local anesthetic, and withdrawal of the spinal needle after injection of the anesthetic solution into the intrathecal space.
5. Total procedure time, defined as the sum of the time to establish landmarks and perform the spinal anesthesia.
6. Block-associated pain score, rated by patients immediately after completion of the spinal anesthesia, on an 11-point verbal analog scale (0–10).
7. Patient satisfaction with the block procedure, rated by patients immediately after completion of administration of the spinal anesthesia, on a 5-point scale (5 = very good, 4 = good, 3 = satisfactory, 2 = unpleasant, 1 = very unpleasant).

All data, including needle insertions and passes, were measured and recorded by an independent observer (research assistant).

Statistical Analysis

We based the sample size calculation on the primary outcome of successful dural puncture on the first needle insertion attempt. The expected rates, based on previous studies in

Table 1. Patients' Clinical Characteristics

| | Ultrasound-guided Technique (n = 60) | Landmark-guided Technique (n = 60) | P Value |
|--|---|---------------------------------------|------------|
| Age (yr) | 62.5 ± 9.7 | 61.2 ± 9.8 | 0.484 |
| Height (cm) | 164.8 ± 11.4 | 164.6 ± 10.8 | 0.927 |
| Weight (kg) | 104.6 ± 22.0 | 111.8 ± 20.6 | 0.067 |
| Body mass index (kg/m ²) | 38.5 ± 8.8 | 41.2 ± 5.9 | 0.051 |
| Gender (male:female) | 20:40 | 22:38 | 0.702 |
| Type of surgery | — | — | 0.024 |
| TKR | 36 (60%) | 49 (82%) | — |
| THR | 22 (37%) | 9 (15%) | — |
| Other | 2 (3%) | 2 (3%) | — |
| Abnormalities of the lumbar spine | — | — | 0.176 |
| None | 44 (73%) | 50 (83%) | — |
| Scoliosis | 9 (15%) | 2 (3%) | — |
| Previous spinal surgery | 7 (12%) | 8 (13%) | — |
| Ease of palpation of surface landmarks | — | — | 0.054 |
| Easy | 5 (8%) | 1 (2%) | — |
| Moderate | 18 (30%) | 9 (15%) | — |
| Difficult | 26 (43%) | 34 (57%) | — |
| Impossible | 11 (18%) | 16 (27%) | — |

Data are reported as n (%) or mean ± SD.

THR = total hip replacement; TKR = total knee replacement.

the general patient population, were 60% and 84% with the surface landmark-guided technique¹⁶ and ultrasound-guided technique,¹⁵ respectively. We concluded that 80 patients would be required in each group (160 patients in total) to achieve a power of 0.9 and a type 1 error rate of less than 0.05.

Statistical analysis was performed using SPSS 16.0 (SPSS Inc., Chicago, IL). Categorical binary outcomes were compared using the chi-square test. Continuous data were tested for normality using Q-Q plots and the Shapiro-Wilk W statistic. Normally distributed outcome data were summarized as mean ± SD and were compared between groups using the independent-measures *t* test. Nonnormally distributed data were summarized as median [interquartile range] and were compared using the Mann-Whitney U test. A two-tailed *P* value <0.05 was taken to indicate statistical significance.

Results

The study was stopped early after an unplanned interim analysis revealed a significant difference in all outcomes related to ease of performance of the spinal anesthesia. We applied the Haybittle-Peto rule¹⁷ and specified a nominal significance level of 0.001 for early stopping so as to preserve an overall type 1 error rate of less than 0.05.¹⁸

A total of 145 patients were recruited into the study, 25 of whom were excluded before randomization for the following reasons: staff with expertise in the ultrasound-guided technique were unavailable (14 patients); it was deemed that there was insufficient time to perform study assessments (8 patients); or the surgical procedure was canceled by the surgical team (3 patients).

One hundred twenty patients completed the study; no data were missing, and no patients were lost to follow-up.

Their clinical characteristics are summarized in table 1. Patients in group US had a lower mean BMI (38.5 ± 8.8 *vs.* group LM, 41.2 ± 5.9 kg/m²; *P* = 0.051) and fewer of them had surface landmarks that were difficult or impossible to palpate (62% *vs.* group LM 83%). However, there were more patients with scoliosis in group US (15% *vs.* group LM, 3%).

Successful dural puncture on the first needle insertion attempt was achieved in twice as many patients in group US than in group LM (65% *vs.* 32%, respectively; *P* < 0.001) (table 2 and fig. 2). There was also a twofold difference between groups in the median number of needle insertion attempts (group US, 1 [1–2] *vs.* group LM, 2 [1–4]; *P* < 0.001) and number of needle passes (group US, 6 [1–10] *vs.* group LM, 13 [5–21]; *P* = 0.003) required to achieve dural puncture (table 2).

Not surprisingly, significantly more time was required to establish landmarks by ultrasound imaging compared with palpation of surface anatomic landmarks (6.7 ± 3.1 *vs.* 0.6 ± 0.5 min, respectively; *P* < 0.001) (table 2). This was partially offset by a reduction in the time required to perform the spinal anesthesia in group US (5.0 ± 4.9 min) *versus* group LM (7.3 ± 7.6 min; *P* = 0.038). The total procedure time, defined as the time required to establish landmarks and perform the spinal anesthetic, was 4.2 min longer in group US (12.2 ± 6.0; mean difference, 95% CI 1.7–6.7 min) than in group LM (7.9 ± 7.7; *P* < 0.001).

To address the potential confounding effect of the observed differences in BMI and quality of surface landmarks between both groups, we performed *post hoc* subgroup analyses of patients with BMI more than 35 kg/m² (group US, n = 46; group LM, n = 56) and patients with landmarks that were difficult or impossible to palpate (group US, n =

Table 2. Outcomes Reflecting Ease of Performance of Spinal Anesthesia

| | Ultrasound-guided Technique (n = 60) | Landmark-guided Technique (n = 60) | P Value |
|---|---|---------------------------------------|------------|
| Successful dural puncture | — | — | — |
| On 1st needle insertion attempt | 39 (65%) | 19 (32%) | < 0.001 |
| On 1st needle pass | 16 (27%) | 5 (8%) | 0.008 |
| Within 5 needle passes | 30 (50%) | 16 (27%) | 0.009 |
| Within 10 needle passes | 45 (75%) | 26 (43%) | < 0.001 |
| Total number of needle insertion attempts | 1 [1–2] | 2 [1–4] | < 0.001 |
| Total number of needle passes | 6 [1–10] | 13 [5–21] | < 0.001 |
| Time taken to establish landmarks (min) | 6.7 ± 3.1 | 0.6 ± 0.5 | < 0.001 |
| Time taken to perform spinal anesthetic (min) | 5.0 ± 4.9 | 7.3 ± 7.6 | 0.038 |
| Total procedure time (min) | 12.2 ± 6.0 | 7.9 ± 7.7 | < 0.001 |

Data are reported as n (%), mean ± standard deviation, or median [interquartile range].

37; group LM, n = 50). These results are presented in table 3. As shown, the direction and magnitude of between-group differences were similar to those of the overall analysis, the only exception being the lack of a statistically significant difference in time taken to perform the spinal anesthetic.

A change in spinal needle was required in 4 (6.7%) patients in group US and 16 (26.7%) in group LM ($P = 0.003$). In group US, a longer needle (25-gauge, 120 mm) was requested for one patient and a larger-gauge needle (22-gauge, 90 mm) for one patient. In group LM, a longer needle (120 mm) was requested for 11 patients (25-gauge in 8 and 22-gauge in 3) and a larger-gauge needle (22-gauge) in 5 (90 mm in 2, and 120 mm in 3). A needle similar to the first one (25-gauge, 90 mm) was requested in all other patients.

Dural puncture could not be achieved with a spinal needle in two patients in group LM despite five needle insertion attempts. Both patients were obese (BMI 39 and 41 kg/m²) and had surface landmarks that were difficult or impossible to palpate. A combined spinal-epidural technique was used in both patients, and this eventually resulted in successful spinal anesthesia. The combined spinal-epidural needle insertion and redirection attempts were not included in the

analysis. Dural puncture was unsuccessful in one patient in group US despite four needle insertion attempts (two each at L3–L4 and L4–L5 interspaces). The patient was moderately obese (BMI 36 kg/m²) with landmarks that were difficult to palpate. The ligamentum flavum–dura mater complex and posterior aspect of the vertebral body could not be visualized at the L2–L3 and L3–L4 interspaces and were only faintly visible at the L4–L5 interspace. Subsequent attempts by a second anesthesiologist using a combined spinal-epidural technique (again not included in the analysis) also were unsuccessful, and the patient received a general anesthetic.

There were no significant differences between groups in either block-associated pain scores (group US, 3 [1–4] *vs.* group LM, 3 [1–5]) or patient satisfaction scores (4 [3–5] in both groups). All patients in whom dural puncture was successfully achieved experienced complete sensory loss to the T7 dermatome or higher. None of the patients experienced any adverse events as a direct result of the study protocol.

Discussion

The technical difficulty of neuraxial blockade is measured using two main parameters: the number of needle manipulations required for success and the time taken to perform the block. Of the two, the former is more important because multiple needle insertions are an independent predictor of complications, such as inadvertent dural puncture, vascular puncture, and paresthesia.¹ Elicitation of paresthesia, in turn, is a significant risk factor for persistent neurologic deficit after spinal anesthesia.^{9,11}

Approximately halfway through the study, it became apparent that the first-attempt success rate using the surface landmark-guided technique was going to be lower than anticipated. In retrospect, this is not surprising because we based our initial estimate on studies in the general adult population^{1,2,15,16} instead of the subset of patients with predictors of difficulty. Recently published data from Ellinas *et al.*³ indicate that the first-pass success rate for neuraxial blockade in parturients with a BMI of 35 kg/m² or greater is approximately 35%, which is consistent with our observa-

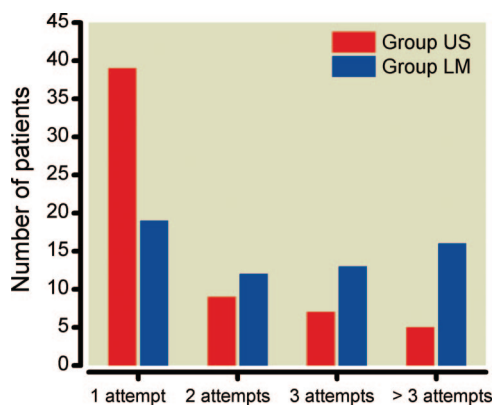


Fig. 2. Comparison of the number of patients requiring one, two, three, or more than three needle insertion attempts for successful dural puncture, depending on whether an ultrasound-guided (group US) or a surface landmark-guided (group LM) technique of spinal anesthesia was used.

Table 3. Subgroup Analysis by BMI and Ease of Palpation of Surface Landmarks

| BMI Greater Than 35 kg/m ² | Ultrasound-guided Technique (n = 46) | Landmark-guided Technique (n = 56) | P Value |
|---|---|---------------------------------------|------------|
| Successful dural puncture | — | — | — |
| On 1st needle insertion attempt | 27 (59%) | 17 (30%) | 0.004 |
| On 1st needle pass | 11 (24%) | 5 (9%) | 0.038 |
| Within 5 needle passes | 23 (50%) | 14 (25%) | 0.009 |
| Within 10 needle passes | 33 (72%) | 23 (41%) | 0.002 |
| Total number of needle insertion attempts | 1 [1–2] | 3 [1–4] | 0.001 |
| Total number of needle passes | 6 [2–15] | 13 [5–21] | 0.008 |
| Time taken to perform spinal anesthetic (min) | 5.5 ± 5.3 | 7.5 ± 7.7 | 0.18 |
| Total procedure time (min) | 12.6 ± 6.4 | 8.1 ± 7.9 | < 0.001 |
| Surface Landmarks Difficult or Impossible to Palpate | Ultrasound-guided Technique (n = 37) | Landmark-guided Technique (n = 50) | P Value |
| Successful dural puncture | — | — | — |
| On 1st needle insertion attempt | 21 (57%) | 15 (30%) | 0.012 |
| On 1st needle pass | 9 (24%) | 3 (6%) | 0.014 |
| Within 5 needle passes | 17 (46%) | 13 (26%) | 0.05 |
| Within 10 needle passes | 24 (65%) | 18 (36%) | 0.008 |
| Total number of needle insertion attempts | 1 [1–3] | 3 [1–4] | 0.003 |
| Total number of needle passes | 7 [2–20] | 14 [5–26] | 0.025 |
| Time taken to perform spinal anesthetic (min) | 5.9 ± 5.9 | 8.1 ± 8.0 | 0.109 |
| Total procedure time (min) | 13.3 ± 7.1 | 8.8 ± 8.2 | < 0.001 |

Data are reported as n (%), mean ± standard deviation, or median [interquartile range].

BMI = body mass index.

tions. Thus, we decided that an unplanned interim analysis was warranted and applied the stringent stopping rule described in the first paragraph of Results. It should be noted that early stopping may have exaggerated the magnitude of the treatment difference.¹⁹ Nevertheless, the results of the current study clearly show that the ultrasound-guided technique reduces the technical difficulty of spinal anesthesia in patients who have difficult surface anatomic landmarks, even in the hands of experienced anesthesiologists. Additional benefits of using ultrasound to preview the spinal anatomy include estimation of the depth to the intrathecal or epidural space^{15,20,21} and more accurate identification of the intervertebral levels,^{22–24} which in turn may reduce the risk of conus medullaris injury.^{25,26}

The ease with which surface anatomic landmarks can be palpated and identified has been found consistently to be the most important predictor of technical difficulty in neuraxial blockade.^{1–5} This was the primary inclusion criterion for most patients in our study. We also included patients with distorted surface landmarks (*i.e.*, those with clinically obvious lumbar scoliosis), which has also been associated with technical difficulty.^{1,4,27–29} These accounted for only a small proportion of subjects (9%). In addition, there were more patients with scoliosis in group US than in group LM, and this is the probable explanation for the observed differences in BMI and surface landmarks between the two groups. Subgroup analyses based on BMI and ease of landmark palpation consistently demonstrated that technical difficulty was reduced by the ultrasound-guided technique, confirming its effectiveness in patients with these clinical features. How-

ever, the utility of ultrasound in patients with scoliosis remains unclear and requires additional study.

There are three other limitations to our study. First, neither operators nor observers were blinded to the technique used because doing so was not feasible. Although this introduces the possibility of therapeutic personality bias (systematic error caused by the operator's convictions about the relative efficacy of the interventions) or expectation bias (systematic error in measuring and recording observations to concur with previous expectations),³⁰ it is unlikely this would change the study's conclusions, given the magnitude of the observed difference. In addition, 65% of all procedures studied were performed by anesthesiologists who were not otherwise involved in the design or conduct of the study.

Second, the incidence of paresthesia or vascular puncture was not recorded, so the impact of the ultrasound-guided technique on these outcomes can only be inferred from the reduction in needle manipulations. Finally, we did not study the efficacy of the paramedian approach to surface landmark-guided neuraxial blockade, which has been shown to be superior to the midline approach in some studies^{31–33} but not in others.^{2,34,35} The appropriate needle trajectory in the paramedian approach is determined partly by triangulation based on the location of the spinous processes and the estimated depth to the vertebral canal and thus may offer little advantage in patients with poorly palpable surface landmarks.

Multiple case reports demonstrate the utility of ultrasound in guiding neuraxial blockade in patients with difficult spinal anatomy,^{18,36–40} but there has been only one other randomized, controlled trial to date on the subject. Grau

*et al.*¹⁴ recruited 72 parturients in whom labor epidural insertion was anticipated to be difficult. Thirty-eight percent of patients were selected based on a BMI of more than 33 kg/m². The rest had a lumbar spinal deformity (26%) or had previously experienced difficulty with epidural insertion (36%). The epidural was performed by a single operator using either the conventional surface landmark-guided technique or an ultrasound-guided technique. They found that the mean number of needle passes was significantly lower in the ultrasound-guided group (1.5 *vs.* 2.6). The ultrasound-guided technique was also associated with significant improvements in block-associated pain scores and patient satisfaction.

However, the ultrasound-guided technique is not without its limitations. Imaging the vertebral canal on ultrasound (ligamentum flavum, dura mater, and posterior aspect of the vertebral body) can be difficult in the same patient populations in which it is most useful. In obese patients, structures are often less distinct because of the attenuation that occurs as ultrasound waves travel a greater distance through soft tissue. In addition, a phase aberration effect caused by the varying speed of sound in the irregularly shaped adipose layers has been described.⁴¹ Advanced imaging technology may compensate for this deterioration in image quality, so we deliberately performed this study with a midrange compact ultrasound machine typical of that available to most anesthesia departments.

Elderly patients may have degenerative spinal disease with narrowed interspinous spaces and interlaminar spaces as a result of ossification of the interspinous ligaments and hypertrophy of the facet joints, respectively. In such patients, directing an ultrasound beam or needle into the vertebral canal may be physically difficult or impossible. This is likely to have been the reason for the three failures in our study. However, even in the most difficult circumstances, ultrasonography can provide potentially useful information on the location of the neuraxial midline and the interlaminar space.

There is an inherent degree of inaccuracy when marking the needle insertion point on the skin during the preprocedure scan. Currently available curved-array probes do not have markings that precisely indicate from where the ultrasound beam emanates. There is also an element of tissue distortion when performing the ultrasound scan, particularly in the elderly, who often have loose and mobile skin. In addition, skin marking does not indicate the caudad-to-cephalad angle at which the needle must be advanced in a midline approach. This can be estimated only from the probe tilt required to produce an optimal image of the interlaminar space. These factors can be compensated for by experience with the ultrasound-guided technique, although the learning curve has yet to be clearly defined.⁴²

Finally, although the spinal anesthesia performance time was shorter in group US, the overall procedure time (taking into account the time required for scanning) was anywhere from 2 to 7 min longer. We do not consider this clinically

significant when weighed against the benefits of the technique in this select population of patients.

In conclusion, preprocedural ultrasound imaging facilitates the performance of spinal anesthesia in the nonobstetric patient population with difficult anatomic landmarks. We believe this is a valuable skill to acquire, especially given the increasing number of elderly and obese patients presenting for orthopedic surgery of the lower limb.^{6–8,43}

References

- de Filho GR, Gomes HP, da Fonseca MH, Hoffman JC, Pederneras SG, Garcia JH: Predictors of successful neuraxial block: A prospective study. *Eur J Anaesthesiol* 2002; 19: 447–51
- Sprung J, Bourke DL, Grass J, Hammel J, Mascha E, Thomas P, Tubin I: Predicting the difficult neuraxial block: A prospective study. *Anesth Analg* 1999; 89:384–9
- Ellinas EH, Eastwood DC, Patel SN, Maitra-D'Cruze AM, Ebert TJ: The effect of obesity on neuraxial technique difficulty in pregnant patients: A prospective, observational study. *Anesth Analg* 2009; 109:1225–31
- Atallah MM, Demian AD, Shorrah AA: Development of a difficulty score for spinal anaesthesia. *Br J Anaesth* 2004; 92:354–60
- Collier CB, Gatt SP: More reports of spinal cord damage by spinal needles. *Anaesth Intensive Care* 2002; 30:532
- Flegal KM, Carroll MD, Ogden CL, Curtin LR: Prevalence and trends in obesity among US adults, 1999–2008. *JAMA* 2010; 303:235–41
- Fehring TK, Odum SM, Griffin WL, Mason JB, McCoy TH: The obesity epidemic: Its effect on total joint arthroplasty. *J Arthroplasty* 2007; 22:71–6
- Wingerter SA, Mehrle RK: Hip disease and hip arthroplasty. *Orthop Clin North Am* 2011; 42:115–21
- Auroy Y, Narchi P, Messiah A, Litt L, Rouvier B, Samii K: Serious complications related to regional anesthesia: Results of a prospective survey in France. *ANESTHESIOLOGY* 1997; 87:479–86
- Harrison DA, Langham BT: Spinal anaesthesia for urological surgery. A survey of failure rate, postdural puncture headache and patient satisfaction. *Anaesthesia* 1992; 47:902–3
- Horlocker TT, McGregor DG, Matsushige DK, Schroeder DR, Besse JA: A retrospective review of 4767 consecutive spinal anesthetics: Central nervous system complications. Perioperative Outcomes Group. *Anesth Analg* 1997; 84:578–84
- Wulf H: Epidural anaesthesia and spinal haematoma. *Can J Anaesth* 1996; 43:1260–71
- Grau T, Bartussek E, Conradi R, Martin E, Motsch J: Ultrasound imaging improves learning curves in obstetric epidural anesthesia: A preliminary study. *Can J Anaesth* 2003; 50:1047–50
- Grau T, Leipold RW, Conradi R, Martin E: Ultrasound control for presumed difficult epidural puncture. *Acta Anaesthesiol Scand* 2001; 45:766–71
- Chin KJ, Perlas A, Singh M, Arzola C, Prasad A, Chan V, Brull R: An ultrasound-assisted approach facilitates spinal anesthesia for total joint arthroplasty. *Can J Anaesth* 2009; 56: 643–50
- Tessler MJ, Kardash K, Wahba RM, Kleiman SJ, Trihas ST, Rossignol M: The performance of spinal anesthesia is marginally more difficult in the elderly. *Reg Anesth Pain Med* 1999; 24:126–30
- Peto R, Pike MC, Armitage P, Breslow NE, Cox DR, Howard SV, Mantel N, McPherson K, Peto J, Smith PG: Design and analysis of randomized clinical trials requiring prolonged observation of each patient. I. Introduction and design. *Br J Cancer* 1976; 34:585–612

18. Geller NL, Pocock SJ: Interim analyses in randomized clinical trials: Ramifications and guidelines for practitioners. *Biometrics* 1987; 43:213-23
19. Schulz KF, Grimes DA: Multiplicity in randomised trials II: Subgroup and interim analyses. *Lancet* 2005; 365:1657-61
20. Arzola C, Davies S, Rofaef A, Carvalho JC: Ultrasound using the transverse approach to the lumbar spine provides reliable landmarks for labor epidurals. *Anesth Analg* 2007; 104: 1188-92
21. Balki M, Lee Y, Halpern S, Carvalho JC: Ultrasound imaging of the lumbar spine in the transverse plane: The correlation between estimated and actual depth to the epidural space in obese parturients. *Anesth Analg* 2009; 108:1876-81
22. Broadbent CR, Maxwell WB, Ferrie R, Wilson DJ, Gawne-Cain M, Russell R: Ability of anaesthetists to identify a marked lumbar interspace. *Anaesthesia* 2000; 55:1122-6
23. Pysyk CL, Persaud D, Bryson GL, Lui A: Ultrasound assessment of the vertebral level of the palpated intercrystal (Tuffier's) line. *Can J Anaesth* 2010; 57:46-9
24. Whitty R, Moore M, Macarthur A: Identification of the lumbar interspinous spaces: Palpation *versus* ultrasound. *Anesth Analg* 2008; 106:538-40
25. Reynolds F: Logic in the safe practice of spinal anaesthesia. *Anaesthesia* 2000; 55:1045-6
26. Reynolds F: Damage to the conus medullaris following spinal anaesthesia. *Anaesthesia* 2001; 56:238-47
27. Leung CC, Yu KS, Chau LF, Sze TS: Management of difficult spinal anaesthesia in a patient with adult lumbar scoliosis. *Anaesth Intensive Care* 2002; 30:101
28. McLeod A, Roche A, Fennelly M: Case series: Ultrasonography may assist epidural insertion in scoliosis patients. *Can J Anaesth* 2005; 52:717-20
29. Chien I, Lu IC, Wang FY, Soo LY, Yu KL, Tang CS: Spinal process landmark as a predicting factor for difficult epidural block: A prospective study in Taiwanese patients. *Kaohsiung J Med Sci* 2003; 19:563-8
30. Sackett DL: Bias in analytic research. *J Chronic Dis* 1979; 32:51-63
31. Blomberg RG, Jaanivald A, Walther S: Advantages of the paramedian approach for lumbar epidural analgesia with catheter technique. A clinical comparison between midline and paramedian approaches. *Anaesthesia* 1989; 44:742-46
32. Leeda M, Stienstra R, Arbous MS, Dahan A, Th Veering B, Burm AG, Van Kleef JW: Lumbar epidural catheter insertion: The midline *vs.* the paramedian approach. *Eur J Anaesthesiol* 2005; 22:839-42
33. Rabinowitz A, Bourdet B, Minville V, Chassery C, Pianezza A, Colombani A, Eychemme B, Samii K, Fourcade O: The paramedian technique: A superior initial approach to continuous spinal anesthesia in the elderly. *Anesth Analg* 2007; 105: 1855-7
34. Kopacz DJ, Neal JM, Pollock JE: The regional anesthesia 'learning curve': What is the minimum number of epidural and spinal blocks to reach consistency? *Reg Anesth* 1996; 21:182-90
35. Cook TM: Combined spinal-epidural techniques. *Anaesthesia* 2000; 55:42-64
36. Chin KJ, Chan VW, Ramlogan R, Perlas A: Real-time ultrasound-guided spinal anesthesia in patients with a challenging spinal anatomy: Two case reports. *Acta Anaesthesiol Scand* 2010; 54:252-5
37. Chin KJ, Macfarlane AJ, Chan V, Brull R: The use of ultrasound to facilitate spinal anesthesia in a patient with previous lumbar laminectomy and fusion: A case report. *J Clin Ultrasound* 2009; 37:482-5
38. Costello JF, Balki M: Cesarean delivery under ultrasound-guided spinal anesthesia in a parturient with poliomyelitis and Harrington instrumentation. *Can J Anaesth* 2008; 55: 606-11
39. O'Donnell D, Prasad A, Perlas A: Ultrasound-assisted spinal anesthesia in obese patients. *Can J Anaesth* 2009; 56:982-3
40. Peng PW, Rofaef A: Using ultrasound in a case of difficult epidural needle placement. *Can J Anaesth* 2006; 53:325-6
41. Saranteas T: Limitations in ultrasound imaging techniques in anesthesia: Obesity and muscle atrophy? *Anesth Analg* 2009; 109:993-4
42. Margarido CB, Arzola C, Balki M, Carvalho JC: Anesthesiologists' learning curves for ultrasound assessment of the lumbar spine. *Can J Anaesth* 2010; 57:120-6
43. Bitton R: The economic burden of osteoarthritis. *Am J Manag Care* 2009; 15:S230-5