

Distribution of Epidural Saline Upon Injection and the Epidural Volume Effect in Pregnant Women

Hideyuki Higuchi, M.D.,* Shunichi Takagi, M.D.,† Eriko Onuki, M.D.,‡ Nobuko Fujita, M.D.,§ Makoto Ozaki, M.D.||

ABSTRACT

Background: How injected epidural solution is distributed and affects the epidural volume in pregnant women are unclear.

Methods: Lumbar epidural catheters were placed using the loss-of-resistance technique with saline in eight full-term (39 weeks' gestation) parturients for labor and eight volunteer nonpregnant women. Lumbosacral cerebrospinal fluid volume was measured on thoracic and lumbosacral axial magnetic resonance images. Another image series was obtained after injecting 10 ml saline into the epidural space through the catheter to compare the saline distribution (dural sac coating and exit from foramina) and cerebrospinal fluid volume before and after epidural injection. Dural sac coating was based on observation of epidural saline in the anterior epidural space after injection in axial magnetic resonance images at the pedicle levels from T12 to L5. Saline leakage from the foramina was determined by the same method at six disc levels from T11–T12 to L4–L5.

Results: Significantly fewer images of pregnant women than nonpregnant women showed saline surrounding the dural sac (0 [0–0] vs. 3 [1–4], median [interquartile range]; $P < 0.01$) and saline leakage from the foramina (0 [0–1] vs. 6 [4–6]; $P < 0.01$). The mean reduction in cerebrospinal fluid volume was significantly greater in pregnant (8.4 ± 1.4 ml; mean \pm SD) than in nonpregnant women (4.6 ± 1.1 ml; $P < 0.001$).

Conclusion: Limited dural sac coating and decreased leakage from the foramina of saline injected into the epidural space may account for the facilitation of longitudinal spread

What We Already Know about This Topic

- The effect of pregnancy on spread of epidurally injected solution is not known

What This Article Tells Us That Is New

- Compared with 10 ml epidural saline injection in nonpregnant women, injection at term pregnancy showed less leakage into foramina and a greater reduction in cerebrospinal fluid volume, consistent with a greater volume effect

of epidural analgesia in pregnant women. The epidural volume effect is greater in pregnant than in nonpregnant women.

SOLUTION injected into the epidural space spreads freely, but not necessarily uniformly, through the epidural space and coats the cylindrical dural sac while partly leaking from the foramina in nonpregnant patients.^{1–3} Injected solution preferentially accumulates in the posterior epidural space, although there is some accumulation in the anterior or posterolateral areas. The dural sac is displaced anteriorly when solution accumulates in the posterior areas, resulting in great compression of the dural sac.^{1,3} Dural sac compression by epidural solution injection squeezes the cerebrospinal fluid (CSF) compartment and displaces the CSF cephalad, thus promoting the cephalad spread of spinal anesthesia in combination with spinal-epidural anesthesia (CSE). This epidural volume effect is thought to partly explain the phenomenon of epidural “top-up” (increased spread of local anesthetic due to epidural fluid injection).^{3–6} Lumbosacral CSF volume is the major determinant of the sensory block spread of spinal anesthesia.^{7–9} In a previous study, we measured the reduction in CSF volume after epidural saline injection using a magnetic resonance (MR) imaging technique to investigate whether the reduction in CSF volume is relevant to the reinforcement of spinal anesthesia in CSE.³ Our findings demonstrated that a 10-ml epidural saline injection decreased CSF volume by 4.4 ml, corresponding to approximately 10% of preinjection volume of lumbosacral CSF.³

In pregnant women, the dural sac is narrowed in association with the engorged venous plexus in the anterior or posterolateral epidural space and the inward movement of soft tissue in the intervertebral foramina caused by increased pressure in the retroperitoneal area, which is thought to facilitate the spread of neuraxial block.^{10–13} Thus, the distribution of

* Associate Professor, † Lecturer, ‡ Assistant Professor, § Senior Resident, || Professor Chair, Department of Anesthesiology, Tokyo Women's Medical University, Tokyo, Japan.

Received from the Department of Anesthesiology, Tokyo Women's Medical University, Tokyo, Japan. Submitted for publication August 18, 2010. Accepted for publication December 3, 2010. Support was provided solely from institutional and/or departmental sources. Presented in part at the Annual Meeting of International Anesthesia Research Society, Honolulu, Hawaii, March 20, 2010.

Address correspondence to Dr. Higuchi: Department of Anesthesiology, Tokyo Women's Medical University, 8-1 Kawadacho, Shinjuku, Tokyo 162-8666, Japan. hhiguchi@anes.twmu.ac.jp. Information on purchasing reprints may be found at www.anesthesiology.org or on the masthead page at the beginning of this issue. ANESTHESIOLOGY's articles are made freely accessible to all readers, for personal use only, 6 months from the cover date of the issue.

Copyright © 2011, the American Society of Anesthesiologists, Inc. Lippincott Williams & Wilkins. Anesthesiology 2011; 114:1155–61

injected epidural solution may be different between pregnant and nonpregnant women. We hypothesized that the engorged epidural venous plexus and the inward movement of soft tissue related to increased pressure in the retroperitoneal area interfere with the coating of the dural sac and decrease leakage from the foramina, thereby facilitating the spread of epidural anesthesia in pregnant women. Because the capacity of the dural sac readily changes,¹⁴ we also hypothesized that epidural saline injection in pregnant women whose dural sac is already narrow acts to further narrow the dural sac, resulting in a greater reduction in CSF volume in pregnant women than in nonpregnant women. In the current study, we used MR images to investigate the distribution of epidural saline injection and the extent of the CSF reduction in pregnant women.

Materials and Methods

After approval from the Hospital Ethics Committee (Tokyo Women's Medical University Hospital in Tokyo, Japan), written informed consent was obtained from eight healthy full-term (39 weeks' gestation) primiparous women with a singleton pregnancy requesting epidural analgesia for labor and eight nonpregnant nulliparous volunteers. Pregnancy was confirmed by ultrasound and report of last menstruation. Nonpregnant women had negative pregnancy tests results and reported menstruation in the previous 4 weeks. Apart from the usual contraindications for epidural anesthesia, patients with obesity (body mass index more than 30), a history of back trauma, obvious spinal postural abnormalities (kyphosis), or neurologic disturbances, were excluded from the study.

One day before exogenous oxytocin administration to augment labor in the pregnant subjects who were all awaiting augmentation, an epidural puncture was performed using an 18-gauge Tuohy needle at the L3–L4 level by a single anesthesiologist (H.H.), using the loss-of-resistance technique with saline, taking care not to inject more than 1 ml saline. A midline approach was used with the patient in the lateral decubitus position. Counting the spines of the vertebrae and palpation of the iliac crest was used to identify the L3–L4 level interspace. After confirmation of the epidural space, an epidural catheter (Prefix, B Braun, Tokyo, Japan), with lateral side ports at 14, 10, and 6 mm from the closed tip, was advanced 3–5 cm into the epidural space. Before insertion, the catheter and bacterial filter were primed with physiologic saline, aiming to achieve an air-free column of fluid from the connector to the catheter tip.

Low thoracic and lumbosacral axial MR images were obtained for measuring CSF volume after catheter insertion using an MR imaging system (Magnetom Vision, Siemens, Tokyo, Japan) operating at 1.5 T, similar to the previously described method.^{3, 7–9, 15} Sagittal MR images of the lower

thoracic lumbosacral column were obtained to determine the level of the disc between the eleventh and twelfth thoracic vertebrae. Then, low thoracic, lumbar, and spinal axial MR images caudal from this site were obtained at 8-mm increments (3-mm thick, 5-mm interval) with a fast-spin echo sequence to obtain CSF volume measurements. These measurements required 51 s, and 8 min and 6 s, respectively. After the MR images were obtained, 10 ml saline was injected into the epidural space through the epidural catheter at a rate of 0.5 ml/s using a 10-ml syringe. Immediately after the injection was completed, MR images were obtained in the same order as before the epidural saline injection. All study subjects were placed in the supine position without uterine tilting during the measurements by the MR imaging system and saline injection through the catheter.

One of the authors (S.T.) determined the dural sac and spinal cord areas for each axial MR image using the public domain National Institutes of Health Image 1.44 program (developed at the Research Services Branch of the National Institutes of Mental Health, Bethesda, MD).# The images were encoded and randomized to blind the investigator to the source of the image with regard to the presence or absence of epidural saline injection and pregnancy. The axial section area (the area of the dural sac minus spinal cord) and perimeter were each multiplied by the interval between slices (8 mm) to calculate the CSF volume. The resulting volume included the spinal nerve roots and is referred to as the CSF volume.

Individual CSF volume before epidural saline injection was compared with that after epidural saline injection. Further, to examine whether the engorged epidural venous plexus interferes with the dural sac coating, each axial MR image at the level of the pedicles of the vertebral bodies from T12 to L5 before saline injection was compared with that after saline injection. Six axial levels at the level of the pedicles of the vertebral bodies, in which the anterior epidural space was filled with veins and was isolated from the rest of the epidural space by a membranous lateral extension of the posterior longitudinal ligament,¹⁶ were selected as a reference for anatomic segmentation in each subject. The dural sac coating was determined based on the number of axial images in which epidural saline was observed in the anterior epidural space. Similarly, to determine saline leakage from the foramina, axial MR images at six disc levels from T11–T12 to L4–L5 before saline injection were compared with images after saline injection. Leakage of saline from the foramina was determined by counting the foramina that contained saline on either side (right or left) of the criteria line, defined as a straight line passing through the center of the intervertebral joint and the point of contact with the vertebral body at the disc level (Fig. 1).

Statistical Analysis

Power analysis ($\alpha = 0.05$, $\beta = 0.20$) indicated that a patient sample size of eight per group was needed to reveal a signif-

Available at: <http://rsb.info.nih.gov/ij/>. Accessed October 26, 2010.

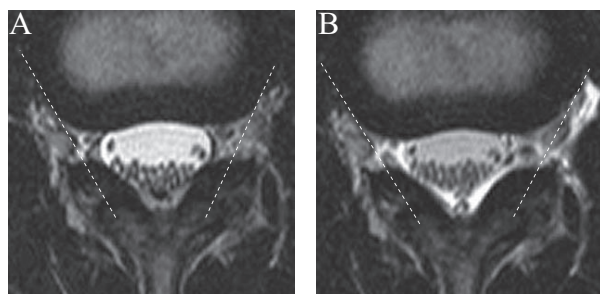


Fig. 1. Example of the criteria line for saline leakage from the intervertebral foramina, defined as a straight line passing through the center of intervertebral joint and the point of contact with the vertebral body at disk level. The magnetic resonance images are shown for nonpregnant woman before (A) and after (B) saline injection at the L2–L3 intervertebral disk level. Saline was observed far beyond the left criteria line (i.e., leaking from the left intervertebral foramina).

icant difference in the CSF volume before saline injection between two groups, assuming that the difference in the CSF volume before saline injection between the pregnant and nonpregnant woman was 9.0 ± 6 ml SD, which was based on a preliminary study. Data are expressed as mean \pm SD and analyzed using unpaired, paired *t* test or Mann–Whitney test where appropriate. A *P* value of less than 0.05 was considered statistically significant (two-tailed). Statistical analyses were performed with JMP 8.0.2 software (SAS Institute, Cary, NC).

Results

Patient characteristics of the 15 women (8 pregnant, 7 nonpregnant subjects) included in the study are presented in table 1. One nonpregnant woman was excluded from analysis because MR images revealed that almost all of the saline was located in the right psoas muscle, with only some of the

Table 1. Patient Characteristics and Magnetic Resonance Imaging Measurements in the Pregnant and Nonpregnant Women

| | Pregnant (n = 8) | Nonpregnant (n = 7) |
|-----------------------------------|---------------------|------------------------|
| Age (yr) | 31 \pm 6 | 30 \pm 6 |
| Height (cm) | 162 \pm 7 | 160 \pm 5 |
| Weight (kg) | 60 \pm 9* | 52 \pm 5 |
| Cerebrospinal fluid volume (ml) | 33.6 \pm 6.5* | 42.0 \pm 4.2 |
| Dural sac coating† | 0 (0–3)‡ | 3 (1–6) |
| Saline leakage from the foramina§ | 0 (0–2)‡ | 6 (3–6) |

Continuous data are expressed as mean \pm SD or discrete data are expressed as medians (ranges).

* *P* < 0.05, † *P* < 0.01 compared with each value in the nonpregnant women. ‡ Data are presented as number of axial images in which epidural saline coated the dural sac. § Data are presented as number of the foramina from which saline leaked out. See Materials and Methods for details.

saline encircling the dural sac. We did not add another nonpregnant woman because the significant difference in the CSF volume before saline injection between the two groups remained. Compared with the axial MR images before saline injection in the nonpregnant group, the anterior and lateral epidural venous plexus in the pregnant group was enlarged in association with dural sac narrowing (figs. 1, 2). As a result, CSF volume before saline injection in the pregnant women was significantly less than that in the nonpregnant women (table 1; *P* < 0.05).

In general, in nonpregnant women, saline injected into the epidural space spread freely through the epidural space and coated the cylindrical dural sac, while partly leaking through the foramina in no particular pattern. However, saline injected into the epidural space of the pregnant women did not leak through the intervertebral foramina, and the engorged epidural venous plexus seemed to interfere with coating of the dural sac, resulting in only posterior accumulation of saline injected into the epidural space at the level of the pedicles of the vertebral bodies (fig. 2). A comparison of the number of axial images at the six pedicle levels in which epidural saline coated the dural sac revealed that pregnant women had significantly less dural sac coating than did nonpregnant women (table 1; *P* < 0.01). Similarly, the number of the foramina through which saline leaked beyond the criteria line in the pregnant women was significantly lower than that in the nonpregnant women (table 1; *P* < 0.01).

Individual lumbosacral CSF volume was compared before and after saline injection. Mean CSF volume decreased significantly in both the pregnant and nonpregnant groups after the injection of saline (fig. 3; *P* < 0.001). However, the mean reduction in CSF volume in the pregnant group (8.4 ± 1.4 ml) was significantly greater than that in the nonpregnant women (4.6 ± 1.1 ml, *P* < 0.001; fig. 4).

Discussion

The findings of the current study indicate that saline injected into the epidural space of pregnant women was blocked from coating the dural sac and exiting from the foramina and that the reduction in CSF volume after the epidural injection of saline was greater in pregnant women than in nonpregnant women. This study is the first to demonstrate the distribution of epidural saline after injection and the epidural volume effect in pregnant women, in whom the dural sac is narrowed in association with the engorged venous plexus in the anterior and lateral epidural space.

The lumbosacral CSF volume before saline injection (42.0 ml) in the nonpregnant women in the current study was comparable with that obtained in male patients in our previous studies (39.0–41.7 ml).^{3,8,9} Similarly, the reduction in the CSF volume induced by 10 ml saline injection in nonpregnant women (4.6 ml) was consistent with the finding from our previous study (4.3 ml).³ Furthermore, CSF volume before saline injection (33.6 ml) in the pregnant women in the current study was consistent with that in preg-

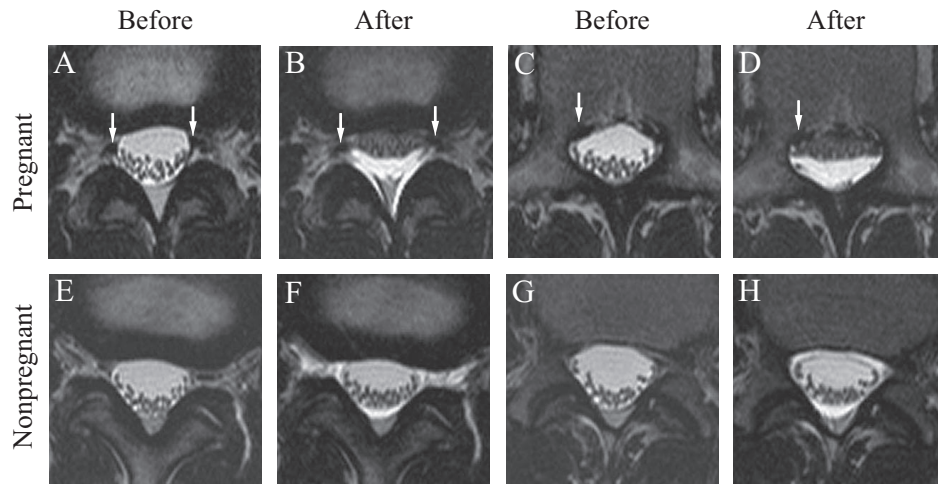


Fig. 2. Magnetic resonance (MR) images (A, C, E, G) before and (B, D, F, H) after epidural saline (10 ml) injection in a 27-yr-old pregnant woman at 39 weeks' gestation, whose cerebrospinal fluid volume decreased from 40.5 ml to 30.1 ml (top; A-D), and in a 22-yr-old nonpregnant woman, whose cerebrospinal fluid volume decreased from 35.1 ml to 31.3 ml (bottom; E-H). In these axial images, anterior is at the top of the figure and anatomic right is at the left of the figure. (Top; A-D) The epidural venous plexus was enlarged, which is a common finding among pregnant women (arrows). (A) Axial MR image at the L2–L3 disk level. The dural area at this level was 1.91 cm². (B) Saline accumulated only posterior to the dura and outlined the posterior epidural fat without leaking from the intervertebral foramina. Dural area at this level decreased to 1.03 cm². (C) Axial MR image at the pedicle of L3. The dural area at this level was 2.03 cm². (D) The enlarged epidural venous plexus seemed to block the saline from spreading anteriorly. Dural area at this level decreased to 0.89 cm². (Bottom; E–H) The epidural venous plexus was not enlarged in the nonpregnant women. (E) Axial MR image at the L2–L3 disk level. The dural area at this level was 1.86 cm². (F) Saline spread around the dural sac, except for the anterior portion, and leaked through the intervertebral foramina. Dural area at this level decreased to 1.63 cm². (G) Axial MR image at the pedicle of L3. The dural area at this level was 2.16 cm². (H) After 10 ml saline was injected, the saline encircled the dura. Dural area at this level decreased to 1.91 cm².

nant female volunteers (mean gestation, 36 weeks) in our previous study (33.2 ml).¹³ In contrast to the study by Saitoh *et al.*,¹⁷ demonstrating no leakage of contrast medium from the intervertebral foramina in approximately 40% of subjects, several sites of leakage from the intervertebral foramina were observed in all nonpregnant women in the current study. The discrepancy between the findings of Saitoh *et al.*¹⁷

and those of the current study of pregnant women might be attributable to methodological differences in the studies, such as the insertion level of the epidural catheter (thoracic *vs.* lumbar vertebrae) and the method of determining leakage (longitudinal *vs.* axial view).

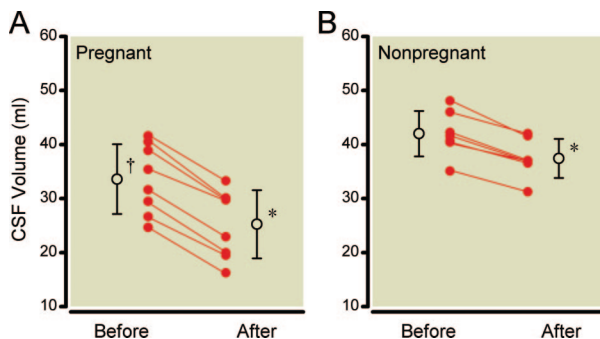


Fig. 3. Changes in cerebrospinal fluid (CSF) volume before and after epidural saline injection in (A) pregnant (n = 7) and (B) nonpregnant (n = 8) women. Individual (filled circles) and mean \pm SD (open circles) values are shown. CSF volume before saline injection differed significantly between the two groups. CSF volumes of all subjects decreased after saline injection in both groups. ($\dagger P < 0.05$ compared with CSF volume before saline injection in the nonpregnant women. $*P < 0.001$ compared with each value before saline injection in each group.)

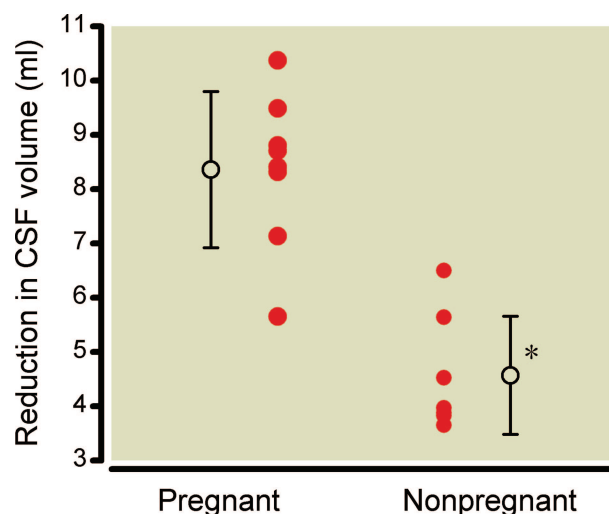


Fig. 4. The reduction in cerebrospinal fluid (CSF) volume produced by saline injection. Individual (closed circles) and mean \pm SD (open circles) values in both groups are shown. The reduction in CSF volume differed significantly between the two groups. ($*P < 0.001$ compared with the reduction in CSF volume in the pregnant women.)

Epidural blood vessels become engorged even during the first trimester of pregnancy because of the increase in the systemic blood volume associated with pregnancy. As pregnancy progresses, gravid uterine growth may partially obstruct the inferior vena cava in the supine position, and the epidural venous flow, collateral to the inferior vena cava, further increases.¹² Contrary to the classic concept,¹⁸ the engorged venous plexus is observed only in the anterior and lateral epidural space and not in the posterior epidural space.^{11,13} Because the engorged venous plexus in the lateral epidural space induces narrowing of the bilateral foramina at the disc level, leakage of solution injected into the epidural space from the foramen may be directly obstructed.¹¹ However, axial images revealed that the engorged epidural venous plexus in the lateral space did not always occupy all the foramina: there were still spaces in some foramina that would allow for solutions to leak through (fig. 2). In our previous study, we proposed that the inward pressure from the increase in the pressure in the retroperitoneal area contributes to bilateral dural sac narrowing induced by pregnancy because the engorged veins do not cause overall distortion of the dura. Rather, fat tissue surrounds the veins and abuts much of the lateral aspect of the dura.¹³ As shown in figure 2, the injected saline appears to be dammed, even in the absence of engorged epidural veins in the foramina. Our results suggest that the inward pressure from the retroperitoneal area contributes to a decrease in saline leakage from the foramina. Similarly, the increased inward pressure might limit dural sac coating, even in the anterior epidural space, a closed compartment that is crowded with the engorged veins, which are not rigid and easily compressive. Although the precise mechanisms of the limited dural sac coating and saline leakage during pregnancy are unclear, the findings of the current study suggest that the restricted distribution of solutions injected epidurally is related to facilitated longitudinal spread of epidural analgesia in the pregnant women. In our previous study, we suggested the involvement of a mechanism other than dural sac narrowing because the reduction in the dural sac surface area by dural sac narrowing alone was not sufficient to explain the facilitation of epidural anesthesia in pregnant women.¹³

Hogan *et al.*¹⁹ investigated the effect of abdominal compression and the mechanics of obesity on dural compression, and reported that abdominal compression decreases CSF volume by a mean of 3.6 ml. Hogan *et al.* suggested that the mechanism by which abdominal compression decreases the dural area is probably the inward movement of soft tissue in the intervertebral foramina, which compresses the dural sac. Lee *et al.*¹⁴ investigated the effect of hyperventilation, abdominal compression, and hyperventilation with abdominal compression on CSF volume reduction and found an additive effect of abdominal compression and hyperventilation: hyperventilation, abdominal compression, and combined hyperventilation with abdominal compression decreased CSF volume by 3.7, 10.1, and 14.9 ml, respectively. They

reported that the additive effect of abdominal compression and hyperventilation represented a combination of two independent effects: decreased cerebral blood volume requires reciprocal replacement of the deficit by intracranial CSF drawn from the spinal CSF reservoir below.¹⁴ In our study, the reduction in CSF volume by saline injection in the pregnant women was greater than that in the nonpregnant women, possibly because of a mechanism similar to that in the study by Lee *et al.*¹⁴ During pregnancy, tidal volume are increased and contribute to pregnancy-induced respiratory alkalosis, which may affect the reduction in lumbosacral CSF volume to compensate for the increase in intracranial CSF volume.²⁰ In addition, the dural sac was displaced posteriorly and inwardly during pregnancy in association with the engorged venous plexus and increased inward pressure, resulting in dural sac narrowing. Injection of saline through the epidural catheter resulted in saline accumulation in the posterior epidural space in the pregnant women, displacing the dural sac anteriorly by compression. As a result, the dural sac was further narrowed and from more directions in the pregnant women than in the nonpregnant women.

Although the concept of “dural sac compressed during pregnancy” is often used in the anesthesia literature, including in our previous report,^{10,11,13} it may be argued that “dural sac compression by pregnancy” is not documented and may thus be physiologically inaccurate. This issue must be addressed in future studies. The dural sac is not a rigid bag and is distended only by its transmural pressure, readily changing its capacity to accommodate prevailing pressure gradients across its walls.^{21,22} For example, CSF pressure quickly returns to baseline values within a few minutes after epidural saline injection,^{23,24} although the decrease in the dural sac area lasts for at least 30 min after saline injection.³ CSF pressure in a full-term parturient is reported to be similar to that in nonpregnant women.²⁵ Further, the PaCO₂ declines to approximately 30 mmHg by 12 weeks’ gestation but does not change further during the remainder of the pregnancy.²⁰ As mentioned, pregnancy-induced respiratory alkalosis may contribute to narrowing of the dural sac, requiring reciprocal replacement of the deficit by intracranial CSF drawn from the spinal CSF reservoir below. Thus, the mechanism of change in the dural configuration during pregnancy is not straightforward, and further studies are required. Based on these potential mechanisms, we chose not to use the expression “dural sac compression by pregnancy” in the current study.

The phenomenon of epidural “top-up” is explained in part by an epidural volume effect.^{4–6} The volume effect occurs when the volume of the fluid injected into the epidural space compresses the dural sac, squeezes the CSF compartment, and displaces the CSF cephalad, thus increasing the cephalad spread of spinal drugs. Our finding that the reduction in CSF volume by saline injection in pregnant women was greater than that in nonpregnant women suggests that the epidural top-up effect in pregnant women is greater than

that in nonpregnant women when using the CSE technique. There are no published studies that directly compare the effect of epidural top-up in pregnant women with that in nonpregnant women. The finding of the current study may provide an explanation for the findings of previous studies by Sia and colleagues.^{26,27} In 2004, Goy and Sia, reported that the CSE technique, using a loss of resistance to 4 ml air (with or without introducing the epidural catheter into the epidural space), compared with single-shot spinal anesthesia, produced a two-segment increase in the sensory block height of spinal anesthesia among patients receiving 10 mg 0.5% hyperbaric bupivacaine and undergoing minor gynecological procedures.²⁶ In 2006, Sia's colleague reported that the CSE technique, using a loss of resistance to 2 ml air performed without placing an epidural catheter or administering epidural medication, resulted in a five-segment increase in the sensory block of spinal anesthesia when compared with the single-shot spinal anesthesia technique using the same dose of local anesthetic (10 mg 0.5% hyperbaric bupivacaine) given intrathecally to patients undergoing elective cesarean.²⁷ One possible explanation for a three-segment difference in the increased sensory block using the CSE technique between pregnant and nonpregnant women ($n = 5$ vs. 2) is that epidural air used for the loss of resistance in pregnant women further compressed the dural sac with a greater reduction in CSF volume than that in nonpregnant women, although we acknowledge that there is no evidence that small amounts of air compress the dural sac.

The current study has several limitations. First, the study was performed using only one type of epidural catheter. Different catheter designs and injection speeds or pressures might produce different patterns of solution distribution and dural sac compression.²⁸ Second, in the current study, saline was injected through the catheter with the patient in the supine position without uterine tilting. Compared with the supine position, the lateral position attenuates the effects of the gravid uterus on the inferior vena cava and on the epidural venous plexus in pregnant women.²⁹ Therefore, saline injection with the patient in a sitting position or a lateral position with or without uterine tilting might produce different results. Third, the MR images had limited resolution and CSF volume was obtained from a time-averaged value. These issues have been extensively discussed previously.^{3,8,9,13,15} Finally, the longitudinal distribution of saline was not investigated in the current study. Although we aimed to obtain sagittal MR images of the epidural saline, such as a three-dimensional surface rendering of epidurography, it was difficult to distinguish epidural saline from CSF and impossible to obtain axial and sagittal images simultaneously. The principal object of the current study was to investigate the epidural volume effect.

The current study demonstrated that saline injected into the epidural space spreads freely through the epidural space and coats the cylindrical dural sac while partly passing out of the foramina in nonpregnant women, and that epidural sa-

line is prevented from coating the dural sac and emerging from the foramina in pregnant women. These findings may facilitate the longitudinal spread of epidural anesthesia in pregnant women. The current study also demonstrated that the dural sac is narrowed from all directions, resulting in greater overall dural sac narrowing in pregnant women than in nonpregnant women.

The authors thank the pregnant women and nonpregnant study participants and the employees in the Department of Radiology of Tokyo Women's Medical University (Shinjuku, Tokyo, Japan) for their cooperation.

References

- Hogan Q: Epidural catheter tip position and distribution of injectate evaluated by computed tomography. *ANESTHESIOLOGY* 1999; 90:964-70
- Hogan Q: Distribution of solution in the epidural space: Examination by cryomicrotome section. *Reg Anesth Pain Med* 2002; 27:150-6
- Higuchi H, Adachi Y, Kazama T: Effects of epidural saline injection on cerebrospinal fluid volume and velocity waveform: A magnetic resonance imaging study. *ANESTHESIOLOGY* 2005; 102:285-92
- Blumgart CH, Ryall D, Dennison B, Thompson-Hill LM: Mechanism of extension of spinal anaesthesia by extradural injection of local anaesthetic. *Br J Anaesth* 1992; 69:457-60
- Stienstra R, Dahan A, Alhadi BZ, van Kleef JW, Burm AG: Mechanism of action of an epidural top-up in combined spinal epidural anesthesia. *Anesth Analg* 1996; 83:382-6
- Stienstra R, Dilrosun-Alhadi BZ, Dahan A, van Kleef JW, Veering BT, Burm AG: The epidural "top-up" in combined spinal-epidural anesthesia: The effect of volume *versus* dose. *Anesth Analg* 1999; 88:810-4
- Carpenter RL, Hogan QH, Liu SS, Crane B, Moore J: Lumbosacral cerebrospinal fluid volume is the primary determinant of sensory block extent and duration during spinal anesthesia. *ANESTHESIOLOGY* 1998; 89:24-9
- Higuchi H, Hirata J, Adachi Y, Kazama T: Influence of lumbosacral cerebrospinal fluid density, velocity, and volume on extent and duration of plain bupivacaine spinal anesthesia. *ANESTHESIOLOGY* 2004; 100:106-14
- Higuchi H, Adachi Y, Kazama T: The influence of lumbosacral cerebrospinal fluid volume on extent and duration of hyperbaric bupivacaine spinal anesthesia: A comparison between seated and lateral decubitus injection positions. *Anesth Analg* 2005; 101:555-60
- Hirabayashi Y, Shimizu R, Fukuda H, Saitoh K, Igarashi T: Soft tissue anatomy within the vertebral canal in pregnant women. *Br J Anaesth* 1996; 77:153-6
- Takiguchi T, Yamaguchi S, Tezuka M, Furukawa N, Kitajima T: Compression of the subarachnoid space by the engorged epidural venous plexus in pregnant women. *ANESTHESIOLOGY* 2006; 105:848-51
- Igarashi T, Hirabayashi Y, Shimizu R, Saitoh K, Fukuda H, Suzuki H: The fiberoptic findings of the epidural space in pregnant women. *ANESTHESIOLOGY* 2000; 92:1631-6
- Onuki E, Higuchi H, Takagi S, Nishijima K, Fujita N, Matsuura T, Ozaki M: Gestation-related reduction in lumbar cerebrospinal fluid volume and dural sac surface area. *Anesth Analg* 2010; 110:148-53
- Lee RR, Abraham RA, Quinn CB: Dynamic physiologic changes in lumbar CSF volume quantitatively measured by three-dimensional fast spin-echo MRI. *Spine* 2001; 26:1172-8
- Higuchi H, Adachi Y, Kazama T: Factors affecting the spread and duration of epidural anesthesia with ropivacaine. *ANESTHESIOLOGY* 2004; 101:451-60

16. Hogan QH: Lumbar epidural anatomy. A new look by cryomicrotome section. *ANESTHESIOLOGY* 1991; 75:767-75
17. Saitoh K, Hirabayashi Y, Shimizu R, Mitsuhata H, Fukuda H: Extensive extradural spread in the elderly may not relate to decreased leakage through intervertebral foramina. *Br J Anaesth* 1995; 75:688-91
18. Bromage PR: Mechanism of action of extradural analgesia. *Br J Anaesth* 1975; 47(Suppl):199-211
19. Hogan QH, Prost R, Kulier A, Taylor ML, Liu S, Mark L: Magnetic resonance imaging of cerebrospinal fluid volume and the influence of body habitus and abdominal pressure. *ANESTHESIOLOGY* 1996; 84:1341-9
20. Cunningham FG, Leveno KL, Bloom SL, Hauth JC, Rouse DJ, Spong CY: *Maternal and physiology*, Williams Obstetrics, 23rd edition. New York, McGraw-Hill, 2010, pp 107-35
21. Shah JL: Influence of cerebrospinal fluid on epidural pressure. *Anaesthesia* 1981; 36:627-31
22. Nystrom EU, Blomberg SG, Buffington CW: Transmural pressure of epidural veins in the thoracic and lumbar spine of pigs. *ANESTHESIOLOGY* 1998; 89:449-55
23. Usubiaga JE, Usubiaga LE, Brea LM, Goyena R: Effect of saline injections on epidural and subarachnoid space pressures and relation to postspinal anesthesia headache. *Anesth Analg* 1967; 46:293-6
24. Ramsay M, Roberts C: Epidural injection does cause an increase in CSF pressure (Letter). *Anesth Analg* 1991; 73:668(Letter)
25. Kapur D, Grimsehl K: A comparison of cerebrospinal fluid pressure and block height after spinal anaesthesia in the right and left lateral position in pregnant women undergoing Caesarean section. *Eur J Anaesthesiol* 2001; 18:668-72
26. Goy RW, Sia AT: Sensorimotor anesthesia and hypotension after subarachnoid block: Combined spinal-epidural *versus* single-shot spinal technique. *Anesth Analg* 2004; 98:491-6
27. Ithnin F, Lim Y, Sia AT, Ocampo CE: Combined spinal epidural causes higher level of block than equivalent single-shot spinal anesthesia in elective cesarean patients. *Anesth Analg* 2006; 102:577-80
28. Magides AD, Sprigg A, Richmond MN: Lumbar epidurography with multi-orifice and single orifice epidural catheters. *Anaesthesia* 1996; 51:757-63
29. Hirabayashi Y, Shimizu R, Fukuda H, Saitoh K, Igarashi T: Effects of the pregnant uterus on the extradural venous plexus in the supine and lateral positions, as determined by magnetic resonance imaging. *Br J Anaesth* 1997; 78:317-9