

# Accidental Intrathecal Injection of Aminophylline in Spinal Anesthesia

Muhammad Ajmal, M.B.B.S., D.A.\*

**M**EDICATION error has been an unfortunate chapter in the history of spinal anesthesia since its invention in 1899. Many catastrophic incidents have occurred from intrathecal injection of local anesthetics contaminated with other chemicals as well as the use of drugs not intended or approved for intrathecal administration.<sup>1-5</sup> In such situations, patient outcomes depend on the nature of the contaminant or the drug effects. Outcomes range from transient neurologic symptoms to permanent neurologic damage, including paraplegia.<sup>1-5</sup> Although there are reports on a wide variety of medication errors in spinal anesthesia,<sup>1-5</sup> accidental intrathecal use of aminophylline, a bronchodilator, has not been described previously.

## Case Report

This case is reported with the consent of the patient's next-of-kin. A healthy, 64-yr-old man (70 kg) was scheduled for transurethral prostate resection for benign hyperplasia. The night before surgery, the patient was assessed and spinal anesthesia was planned.

Before lumbar puncture, using a 5-ml disposable syringe, the anesthesiologist drew and injected supposed 3 ml plain bupivacaine (bupicain), 0.5%, from a single-use 10-ml amber-colored glass ampoule held by an assistant. Using aseptic technique, with the patient in a seated position, lumbar puncture was successful on first attempt at L3-L4 with a 23-gauge cutting spinal needle.

Immediately after intrathecal injection, the patient's lower limbs (calves) developed tetanic muscle spasm and he

complained of leg cramping. This unusual response aroused suspicion. After closer inspection, it was determined that aminophylline had been injected intrathecally instead of bupivacaine. The size, shape, and color of the 10-ml aminophylline ampoule (GlaxoSmithKline [formerly known as Wellcome], Karachi, Pakistan) was similar to that of the 10-ml bupicain ampoule (Howard, Lahore, Pakistan; fig. 1).

General anesthesia was induced immediately with 400 mg sodium thiopental and 100 mg suxamethonium. Tracheal intubation was achieved using an 8-mm ID cuffed endotracheal tube. Anesthesia was maintained with nitrous oxide, oxygen, and halothane mixture. Atracurium besilate was used to facilitate controlled ventilation.

The patient remained stable during surgery, which lasted 45 min. Intravenous dexamethasone (8 mg) was injected during anesthesia. Surgical management was customary for transurethral resection of prostate.

After recovery from anesthesia, the patient was comfortable and results of the neurologic examination were normal. Although the literature was searched to acquire any information regarding similar medication errors, no such report was available.<sup>6</sup> Immediately after the error and for the duration of the patient's hospital stay (24 h), he remained in normal condition. He did not exhibit neurologic problems or any other complaints.

In the absence of any clinical signs or symptoms of distress, and in the absence of any clinically proven intrathecal intervention (*e.g.*, intrathecal lavage to mitigate the effects of aminophylline medication error), a "wait and see" policy was followed.<sup>7</sup> The patient was, therefore, discharged from the hospital.

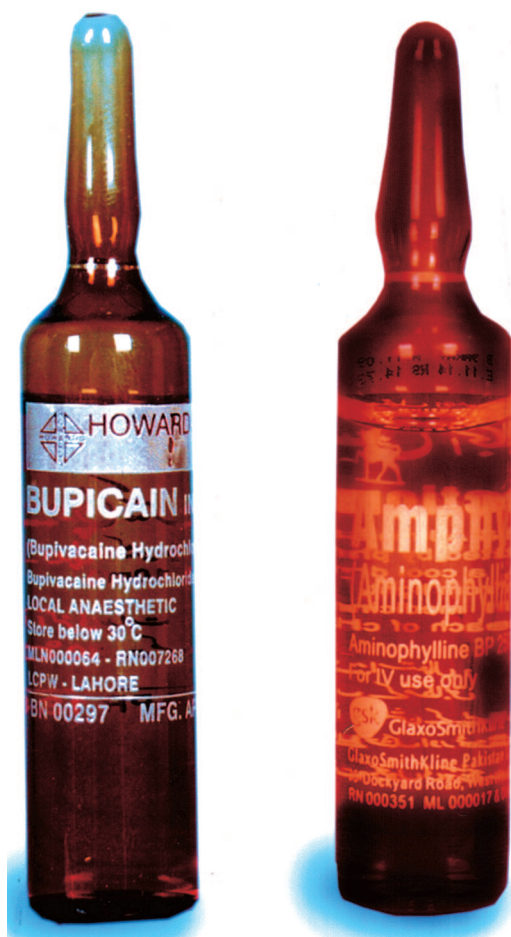The patient reported back to the hospital within 24 h of release because of weakness in his lower limbs. His care was transferred to a medical specialist who treated him with a high dose of vitamin B-complex oral supplements. Although it was hoped that the supplements would revitalize damaged neurons, no such treatment proved fruitful. Three days after the incident, a lumbar puncture was done to obtain cerebrospinal fluid specimen and to perform a myelogram. Results of cerebrospinal fluid analysis were considered normal, with elevated protein concentrations (54 mg/dl [normal = 15-45

\* Anesthesiologist, Aziz Fatima Hospital, Faisalabad, Pakistan. Current position: Resident, Department of Anesthesia, Letterkenny General Hospital, Letterkenny, Ireland.

Received from the Department of Anesthesia, Letterkenny General Hospital, Letterkenny, Ireland. Submitted for publication October 7, 2010. Accepted for publication November 24, 2010. Support was provided solely from institutional and/or departmental sources.

Address correspondence to Dr. Ajmal: Department of Anesthesia, Letterkenny General Hospital, Letterkenny, Ireland. ajmal\_c@hotmail.com. Information on purchasing reprints may be found at [www.anesthesiology.org](http://www.anesthesiology.org) or on the masthead page at the beginning of this issue. ANESTHESIOLOGY's articles are made freely accessible to all readers, for personal use only, 6 months from the cover date of the issue.

Copyright © 2011, the American Society of Anesthesiologists, Inc. Lippincott Williams & Wilkins. Anesthesiology 2011; 114: 998-1000

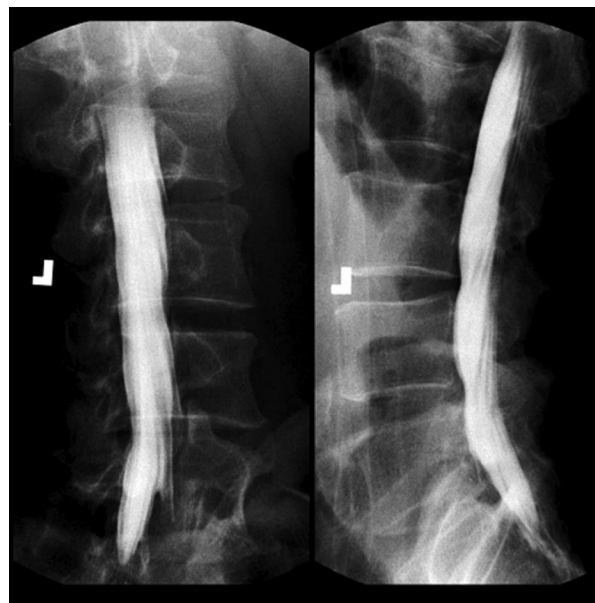


**Fig. 1.** Ten milliliter ampoules of bupivacaine (bupicain), 0.5%, versus aminophylline: similar size, shape, and color.

mg/dl). Lateral and oblique views of the lumbar myelogram showed mild external compression on the thecal sac at L3–L5, most likely the result of disc bulging at those levels. However, this type of radiographic finding is common in significant proportion within a healthy, asymptomatic population. Vertebral heights and disc spaces were likewise normal (fig. 2).

Medical professionals involved in case management were convinced that no measure at that stage could modify the outcome. Advanced imaging technology, such as magnetic resonance imaging, was not freely available—nor was the patient willing to bear the expense of further investigation that could not modify the outcome. Although pathologic diagnosis remained obscure, clinical diagnosis of the case was obvious: 3 ml aminophylline, 2.5%, had done the damage. The patient remained paraplegic and died 2 yr later. Considering social background and medical history, no autopsy was performed.

Drugs administered inadvertently during central neuraxial blocks have resulted in serious consequences as a result of direct drug or drug-additive neurotoxicity as well as extreme pH of the injectate. Pain on intrathecal injection is the most common sign when an irritant solution such as a



**Fig. 2.** Lumbar myelogram taken on third day after medication error. In preparation for transurethral prostate resection for benign hyperplasia, an intrathecal injection of 3 ml aminophylline was administered instead of bupivacaine (bupicain), 0.5%.

local anesthetic is contaminated with an acid or antiseptic solution.<sup>8</sup>

The patient described in this report did not complain of pain on intrathecal injection of aminophylline—even though it was a strong alkaline solution composed of theophylline and ethylenediamine (4:1). Theophylline is a methylxanthine and nonspecific phosphodiesterase inhibitor. It is central nervous system stimulant when used systemically and can lead to convulsions with toxic plasma levels. Its inadvertent intrathecal injection in the reported case resulted in initial excitation of spinal neurons. In some animal models, intrathecal aminophylline was shown to block the locus coeruleus stimulation-mediated antinociception in parafascicular neurons by antagonizing the adenosine receptors.<sup>9</sup> Ethylenediamine forms a stable mixture with theophylline to produce aminophylline. It is widely used in the chemical and pharmaceutical industries. Headache, dizziness, shortness of breath, nausea, and vomiting have been reported after exposure. It irritates the skin and mucous membranes. In the form of aminophylline, ethylenediamine is a diluted solution. It can cause skin burns in concentrated form. Allergic skin reactions can occur in individuals sensitized to this chemical.<sup>10</sup>

In Pakistan, the country where this incidence occurred, supply of consumable items (*e.g.*, medications, needles, canulae, sutures, *etc.*) required for anesthesia or surgery has been the responsibility of patients. They or their family members are required to purchase the necessary items from various medical stores or pharmacies and deliver them to operating rooms before, during, and after surgery, as needed. Operating departments cannot ensure uniformity in drug supplies, increasing the risk of medication errors.

After a medication error of this kind has occurred, often there is no definitive treatment strategy available. Prevention of such errors is the only measure to ensure patient safety. Strategies such as clear labeling and a system to ensure accurate drug identification are essential components of such preventive programs.<sup>7,11</sup> Ultimately, it is the anesthesiologist who is responsible and answerable for the safety of his or her patients.

The author thanks his brother-in-law Salman Ahmad, F.C.P.S. (Assistant Professor of Orthodontics, Multan Medical and Dental College, Multan, Pakistan), for help in organizing the digital artwork necessary to meet the requirements of publication.

## References

1. Maltby JR, Hutter CD, Clayton KC: The Woolley and Roe case. *Br J Anaesth* 2000; 84:121-6
2. Mohseni K, Jafari A, Nobahar MR, Arami A: Polymyoclonus seizure resulting from accidental injection of tranexamic acid in spinal anesthesia. *Anesth Analg* 2009; 108:1984-6
3. Kim M, Jeong S, Choi E, Ha H, Lee HY: Death after accidental injection of tranexamic acid during spinal anaesthesia. *Korean J Leg Med* 2009; 33:139-42
4. Maheshwari S, Sharma K, Chawla R, Bhattacharya A: Accidental intrathecal injection of a very large dose of neostigmine methylsulphate. *Indian J Anaesth* 2003; 47:299-301
5. Salihoglu Z, Demiroglu S, Kose Y: Accidental subarachnoid injection of atracurium: A case report. *J Anesth* 2002; 16:72-4
6. Kaiser KG, Bainton CR: Treatment of intrathecal morphine overdose by aspiration of cerebrospinal fluid. *Anesth Analg* 1987; 66:475-7
7. Hew CM, Cyna AM, Simmons SW: Avoiding inadvertent epidural injection of drugs intended for non-epidural use. *Anaesth Intensive Care* 2003; 31:44-9
8. Bogod D: The truth, the whole truth. *Anaesthesia News Newsletter* 2010; 271
9. Han BF, Zhang C, Qi JS, Qiao JT: ATP-sensitive potassium channels and endogenous adenosine are involved in spinal antinociception produced by locus coeruleus stimulation. *Acta Physiologica Sinica* 2002; 54:139-44
10. Allergy to aminophylline. *Lancet* 1984; 324:1192-3
11. Jensen LS, Merry AF, Webster CS, Weller J, Larsson L: Evidence-based strategies for preventing drug administration errors during anaesthesia. *Anaesthesia* 2004; 59:493-504