Anesthesiology 2010; 113:463

Patent Foramen Ovale, Bubble Test, and Major Spine Surgery

Sophie Rym Hamada, M.D., Jean Mantz, M.D., Ph.D.
Beaujon Universitary Hospital
sophiehamada@hotmail.com

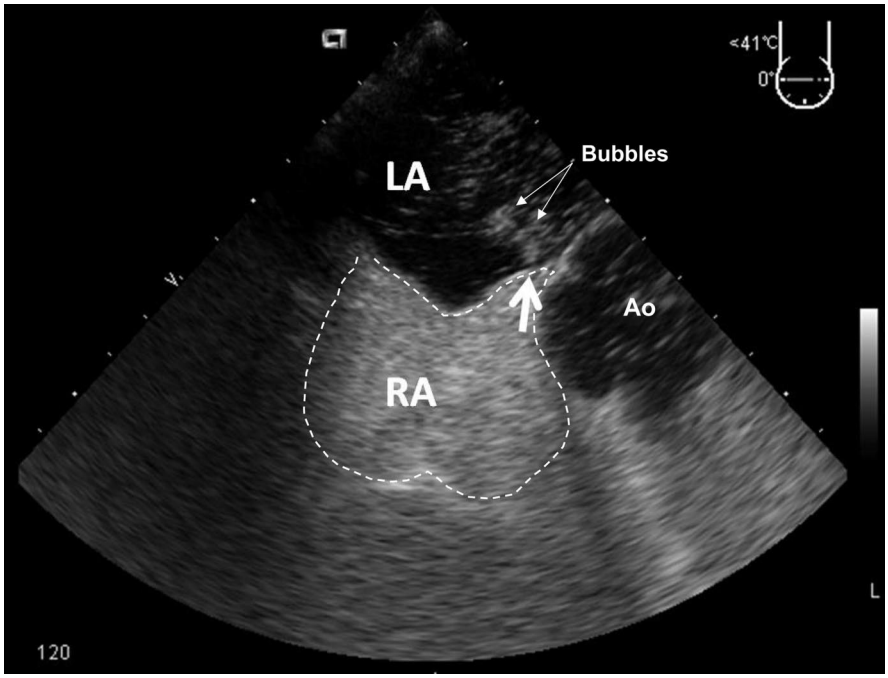

POSTOPERATIVE paradoxical embolism resulting from patent foramen ovale (PFO) is a serious complication associated with major surgery. The prevalence of PFO in the general population ranges from 10 to 15% (contrast echocardiography[1]) to 27.3% (autopsy series). Preoperative diagnosis of PFO is rarely performed except in special settings such as surgery in the sitting position. In this case, a 68-yr-old patient, having undergone thoracolumbar laminectomy and arthrodesis (T12–L1 levels), presented with a bilateral segmentary pulmonary embolism and a left parietooccipital stroke on postoperative day 1. Because of both venous and arterial embolism, PFO was suspected and confirmed with transesophageal echocardiography sensitized with the bubble test.[2] Contrast material was prepared by mixing 9 ml normal saline with 1 ml air through a three-way stopcock. This is known to produce 152 ± 79 microbubbles/mm^3 with a diameter of 30–100 μm. A PFO is considered to be present when at least one bubble is seen in the left atrium (LA) within three cardiac cycles after total opacification of the right atrium[3] (RA, *dotted line*) (see Supplemental Digital Content 1, which is a video showing bubbles in the left atrium immediately after total opacification of the right atrium, http://links.lww.com/ALN/A595). The *arrow* shows right-to-left shunting across the septum secundum not far from the aorta (Ao). Echocardiography with the bubble test is a safe, sensitive, and specific method to detect PFO. We suggest that systematic, prospective evaluation with bubble testing might be used for high-risk patients undergoing major spine surgery.

References

1. Lechat P, Mas JL, Lascault G, Loron P, Theard M, Klimczac M, Drobinski G, Thomas D, Grosgogeat Y: Prevalence of patent foramen ovale in patients with stroke. N Engl J Med 1988; 318:1148–52
2. Mas JL, Arquizan C, Lamy C, Zuber M, Cabanes L, Derumeaux G, Coste J: Recurrent cerebrovascular events associated with patent foramen ovale, atrial septal aneurysm, or both. N Engl J Med 2001; 345:1740–6
3. Homma S, Di Tullio MR, Sacco RL, Mihalatos D, Li Mandri G, Mohr JP: Characteristics of patent foramen ovale associated with cryptogenic stroke. A biplane transesophageal echocardiographic study. Stroke 1994; 25:582–6

Supplemental digital content is available for this article. Direct URL citations appear in the printed text and are available in both the HTML and PDF versions of this article. Links to the digital files are provided in the HTML text of this article on the Journal's Web site (www.anesthesiology.org).