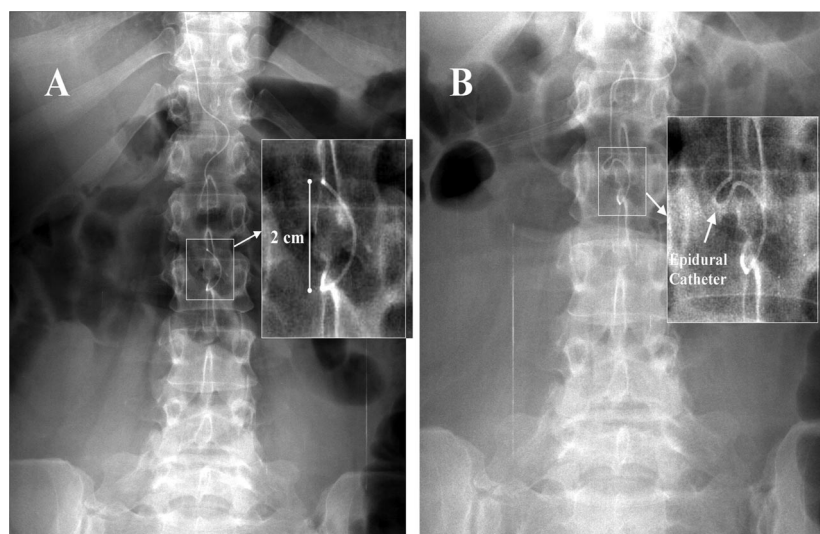


*Hugh C. Hemmings, Jr., M.D., Ph.D., Editor*

## The Case of the Missing Needle

Anup Pamnani, M.D., Panchali Dhar, M.D., Farida Gadalla, M.D.

Weill Cornell Medical College; alp7001@med.cornell.edu



A 41-YR-OLD patient with a lumbar epidural catheter in place presented for a cesarean section for arrested labor. After the procedure, a surgical count revealed that a Polysorb 2-0 suture needle was missing. A subsequent abdominal radiograph (fig. A) showed an opacity in the midline consistent with the size (2 cm tip to base) and curvature of the missing needle. A lateral abdominal film was also obtained but was unrevealing. The obstetrician requested a repeat anesthetic to reexplore the abdomen.

On reevaluation by the anesthesiologists, however, the object was noted to be overlying the radioopaque epidural catheter. The possibility that the opacity might represent an artifact rather than a needle was considered. The diagnostic options to assess the cause of the opacity included injecting radioopaque dye through the catheter, removal of the catheter, and partially withdrawing the catheter to elicit a change in the opacity on reimaging. Partial withdrawal of the catheter was deemed most appropriate because it would allow the catheter to be “redosed” for abdominal exploration. The catheter was withdrawn 1 cm. A subsequent radiograph (fig. B) displayed that the artifact was in fact the epidural catheter (labeled). The missing needle was never found.

This case highlights the limitation of solely using radiography to assess the retained foreign bodies. Surgical needles are the most commonly miscounted items.<sup>1</sup> Although the abdominal radiographs have a high degree of sensitivity in the detection of large retained surgical needles (>25 mm), their utility begins to decline as needle size decreases (<24 mm).<sup>2</sup> Good communication with the radiologist, use of computed tomography imaging, and newer technologies such as radiofrequency identification and bar coding may provide additional information in the assessment of surgical miscount.<sup>3</sup>

### References

1. Egorova NN, Moskowitz A, Gelijns A, Weinberg A, Curty J, Rabin-Fastman B, Kaplan H, Cooper M, Fowler D, Emond JC, Greco G: Managing the prevention of retained surgical instruments. What is the value of counting? *Ann Surg* 2007; 247:8–12
2. Ponrartana S, Coakley FV, Yeh BM, Breiman RS, Qayyum A, Joe BN, Poder L, Lu Y, Gibbs VC, Roberts JP: Accuracy of plain abdominal radiographs in the detection of retained surgical needles in the peritoneal cavity. *Ann Surg* 2008; 247:13–8
3. Whang G, Mogel GT, Tsai J, Palmer SL: Left behind: Unintentional retained surgically placed foreign bodies and how to reduce their incidence. *Am Jour Roent* 2009; 193:S79–89

Presented at the Society for Obstetric Anesthesia and Perinatology Annual Meeting, Washington D.C., May 1–2, 2009.