

# Ultrasound Evaluation of the Sacral Area and Comparison of Sacral Interspinous and Hiatal Approach for Caudal Block in Children

Seo K. Shin, M.D.,\* Jeong Yeon Hong, M.D., Ph.D.,† Won Oak Kim, M.D.,‡ Bon Nyeo Koo, M.D., Ph.D.,‡  
Jee Eun Kim, M.D.,\* Hae Keum Kil, M.D.‡

**Background:** Although caudal block *via* the sacral hiatus is a common regional technique in children, it is sometimes difficult to identify the hiatus. A needle approach *via* the S2–3 interspace can be used as an alternative to the conventional approach. The authors compared the feasibility and clinical characteristics between the S2–3 approach and hiatal approach, in addition to ultrasound study.

**Methods:** Sacral space depth, dural sac end level, and caudal space depth were evaluated using ultrasound with high-frequency linear probe in the lateral decubitus position in 317 anesthetized children (study 1). In another 162 children who underwent ambulatory urological surgeries, success rate, drug spread, and clinical characteristics were compared between the hiatal and S2–3 approaches (study 2).

**Results:** The dural sac end level was S2U (S3M–L5M). The median depth of the sacral space at the S2–3 level was 7.3 mm, whereas the caudal space depth at the hiatus was 2.9 mm. The overall success rate was 96.3% in both groups. The success rates at the first puncture attempt were 96.2% in the S2–3 group and 77.5% in the hiatus group. Drug spread level and clinical characteristics were similar between the two groups.

**Conclusions:** The S2–3 approach can be applied as a useful fallback method to the conventional landmark approach in children, especially in those older than 36 months who present with difficult identification of the sacral hiatus.

SINGLE-SHOT caudal block through the sacral hiatus is the most common regional anesthetic method for infraumbilical surgery in children.<sup>1–3</sup> However, it is sometimes difficult to identify the sacral hiatus and locate the caudal space because of varying anatomical structures or local obesity.<sup>3–5</sup> In these cases, as Busoni described,<sup>3,6</sup> an alternative method for postoperative analgesia such as the transsacral approach may be necessary. The sacrum is composed of five distinct semicartilaginous sacral vertebrae in neonates that gradually ossify and fuse to form the adult sacrum in the third decade of life, which allows for a relatively easy approach through the interspinous space in children.<sup>7,8</sup> If this approach can provide easy accessibility with a low complication rate

and effective anesthetic spread within the epidural space, it may be recommended as a useful alternative to the standard caudal block. Although there have been a few reports that investigated the feasibility of the sacral interspinous approach in children and adults,<sup>3,9,10</sup> there are no reports, to our knowledge, directly comparing the characteristics of the sacral hiatal and interspinous approach in children.

We designed two studies as follows: (1) an ultrasound study to evaluate the sacral spinal structures, including the level of the dural sac end, and (2) a comparative study that examined the two approaches in terms of technical feasibility, drug spread within the extradural space, and clinical characteristics.

## Materials and Methods

This study was approved by the Institutional Review Board of Yonsei University Health System (Seoul, Republic of Korea), and informed consent was obtained from all parents of the children.

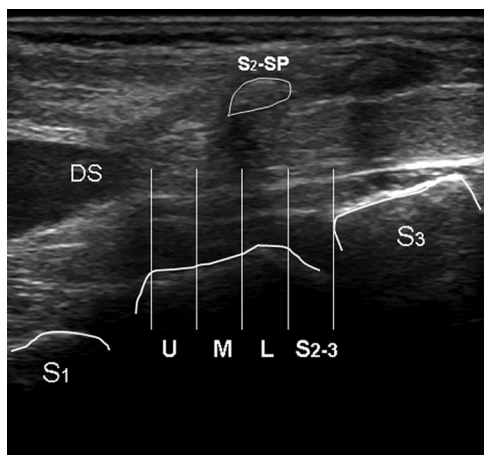
### Study 1

A total of 317 children were included in this study. Children were aged 10 days to 74 months, weighed 2.8–25 kg, and had an American Society of Anesthesiologists physical status of I or II. All children were scheduled to undergo urologic surgery during general anesthesia and required caudal or epidural block for postoperative analgesia. Children with spinal anomalies, coagulation abnormalities, or infectious foci on the back were excluded from the study. No premedication was given. After general anesthesia, patients were placed in the lateral decubitus position with full flexion of the hip joint. Median sagittal or paramedian sagittal images of the sacral area, including the dural sac end, were obtained using a portable ultrasound unit (LOGIQ e; GE Healthcare, Wauwatosa, WI) and an 8- to 13-MHz linear array probe. At the sacral hiatus level, axial images were obtained. The end of the dural sac was defined as the distal apex of the dura. The level of the dural sac end was determined in relation to the vertebral body.<sup>11</sup> Each unit of the vertebral body was divided into three equal portions (upper [U], middle [M], and lower [L] thirds), and the intervertebral space was defined as a separate region (fig. 1). In addition, the dural sac end level was determined by age group. The distance of the skin-sacroccygeal ligament and depth of the sacral/caudal space were measured in the sagittal

\* Resident, Department of Anesthesiology and Pain Medicine, † Clinical Associate Professor, ‡ Professor, Department of Anesthesiology and Pain Medicine, Anesthesia and Pain Research Institute, Yonsei University College of Medicine.

Received from the Department of Anesthesiology and Pain Medicine, Yonsei University College of Medicine, Seoul, Republic of Korea. Submitted for publication February 25, 2009. Accepted for publication August 6, 2009. Support was provided solely from institutional and/or departmental sources. Presented in part at the Annual Meeting of the American Society of Anesthesiologists, Orlando, Florida, October 22, 2008.

Address correspondence to Dr. Kil: Department of Anesthesiology and Pain Medicine, Yonsei University College of Medicine, 250 Seongsanno, Seodaemun-gu, Seoul 120-752, Republic of Korea. hkkil@yuhs.ac. Information on purchasing reprints may be found at [www.anesthesiology.org](http://www.anesthesiology.org) or on the masthead page at the beginning of this issue. ANESTHESIOLOGY's articles are made freely accessible to all readers, for personal use only, 6 months from the cover date of the issue.



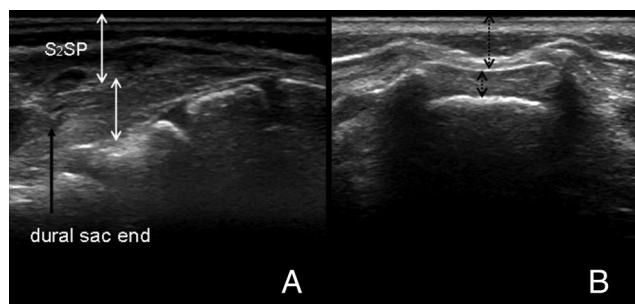
**Fig. 1.** The level of the tip of the dural sac is defined by dividing the vertebral body, including the intervertebral space, into four segments: upper (U), middle (M), and lower (L) thirds, and the intervertebral space. DS = dural sac; S2-3 = intervertebral space of S2-3; S3 = base of the third sacral body; S2-SP = spinous process of S2.

view at the S2-3 level and the axial view at the hiatus level (fig. 2). These values were also determined according to age group.

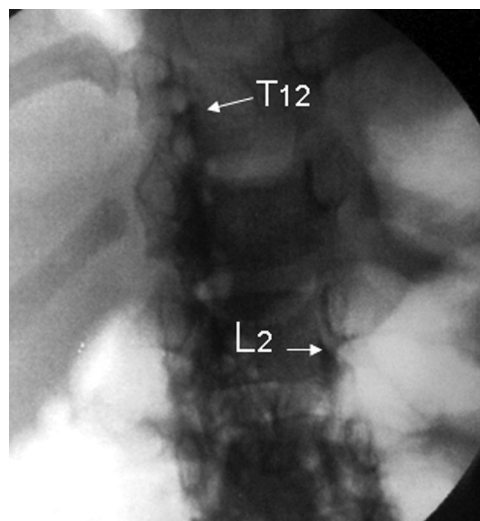
### Study 2

A total of 162 children were included in this study. Children were aged 4–60 months, weighed 7–28 kg, had an American Society of Anesthesiologists physical status of I or II, and were scheduled to undergo elective outpatient urologic surgery during general anesthesia. All children required caudal block for postoperative analgesia. Children with spinal anomalies, coagulation abnormalities, or infection foci on the back were excluded from the study. Also, children with a history of bronchial asthma or drug allergies were excluded to avoid possible allergic reactions to the iodinated radiopaque dye.

Three types of surgeries (perineal, hernioplasty, and orchiopexy) were performed in this study, and the same numbers of children were enrolled for each type of



**Fig. 2.** The distance of skin-sacroccygeal ligament and depth of space at S2-3 level and hiatus level on ultrasound images. (A) Sagittal image of sacral area. White arrows = distance of skin-sacroccygeal ligament and the depth of sacral space. S2-SP = spinous process of S2. (B) Axial image of hiatus level. Black arrows = distance of skin-sacroccygeal ligament and the depth of caudal space.



**Fig. 3.** Asymmetric drug spread was defined if the drug spread showed a difference of two or more segments between left and right side within the extradural space on fluoroscopic image.

surgery. Children were randomly allocated to one of two groups (hiatus or S2-3 group) for each type of surgery by a computer-generated randomization method with SPSS 13.0 (SPSS, Chicago, IL). After general anesthesia with sevoflurane, patients were placed in the left-lateral decubitus position with hip flexion, and the sacral hiatus or S2-3 interspace was identified by anatomical landmarks and ultrasound examination.<sup>3,5,12</sup> Patients who showed dural sac ends below S2-3 on ultrasound were excluded from the study and were defined as failed cases. After aseptic preparation, a 5-cm, 22-gauge, short-beveled needle was inserted directly through the sacral hiatus in the hiatus group and was inserted perpendicularly through the S2-3 interspace in the S2-3 group. If the puncture was unsuccessful by the fourth trial, the case was defined as a failed block.<sup>13</sup> After identifying the sacral space using the loss-of-resistance technique with saline, 0.2% ropivacaine containing iohexol (Omnipaque; GE Healthcare Ireland, Carrigtohill, County Cork, Ireland) was slowly injected at a rate of 1 ml/3 s using the Armitage formula (0.5 ml/kg for perineal surgery, 1.0 ml/kg for hernioplasty, and 1.25 ml/kg for orchiopexy).<sup>14</sup> Patients were then placed in the supine position for fluoroscopy. Fluoroscopic images of the anterior-posterior lumbosacral or thoracosacral area were transferred to the picture archiving and communication system. All punctures were performed by three anesthesiologists and three trainees. Drug spread levels and patterns within the extradural space were retrospectively determined us-

**Table 1.** Demographic Data of the 317 Patients (292 Male, 25 Female) in Study 1

Age, mo	14 (0.3–74)
Weight, kg	10.5 (2.8–25)
Height, cm	77 (44–120)

Values represent median (range).

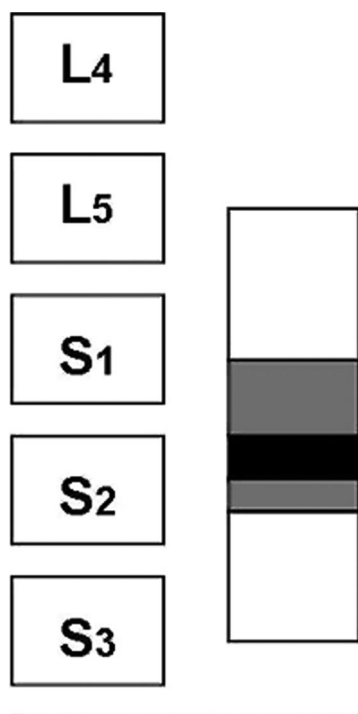


Fig. 4. Level of the dural sac end in relation to the vertebral body. Black bar = median level; gray bar = interquartile range; white bar = full range of distribution.

ing the picture archiving and communication system under the supervision of a radiology specialist. If the drug spread showed a difference of more than two segments between the left and right sides within the extradural space, it was defined as asymmetric spread (fig. 3).

To measure the amount of exposure of radiation, we attached a collecting plate to the thigh of five randomly selected children during fluoroscopy. Success rate, puncture frequency, drug spread level, spread segments per milliliter of drugs, postoperative pain score (face, legs, activity, cry, and consolability; five categories, each scored 0–2), complications, and voiding and discharge times were evaluated in both groups.

### Statistical Analysis

**Study 1.** All data are expressed as median value (range). The dural sac end levels among age groups were compared with the Kruskal–Wallis test. A one-sample *t* test (two-tailed) was used to compare the distance of skin–sacroccygeal ligament and the depth of space at the S2–3 level and hiatus level. The distance and depth of the parameters among age groups were analyzed with one-way analysis of variance.

**Study 2.** The initial sample size of study 2 was calculated using values from a pilot study. Assuming a two-segment difference in drug spread level between the two groups, a two-sided type 1 error of 0.05, a power of 0.80, and an effect size of 0.50, 64 patients in each group were required to find a significant difference in spread level on radiographic images. After considering a drop-out rate of 20%, which was based on the ultrasound results and potential complications, 81 patients were recruited for each group.

The differences in age, weight, voiding and discharge times, pain scores, and number of spread segments between the two groups were analyzed with the Student *t* test. Puncture frequency and asymmetric spread were analyzed with the Pearson chi-square test or Fisher exact test. Data are expressed as median (range) or mean (SD) unless otherwise specified.

All statistical analysis was accomplished with SPSS 13.0, and *P* values less than 0.05 were considered statistically significant.

## Results

### Study 1

Demographic data are listed in table 1. The median level of the dural sac end in relation to the vertebral body was S2U (S3M–L5M) (fig. 4). The dural sac end ascended slightly after 36 months of age to S1–2 (S3M–L5M) (*P* = 0.036) (table 2). Of 317 children, 24 (7.57%) showed dural sac ends below S2–3. The median values of the distance and depth of the parameters are listed in table

Table 2. Characteristics of Spinal Structures in Study 1

	Overall	Age		
		≤ 12 mo (n = 136)	13–36 mo (n = 142)	≥ 37 mo (n = 39)
Dural sac end level	S2U (S3M–L5M)	S2U (S3M–L5M)	S2U (S3M–L5L)	S1–2 (S3M–L5M)*
Distance of skin–SCL, mm†				
S2–3	10.3 (2.9–17.1)	10.2 (2.9–15.9)	10.4 (4.6–17.1)	8.9 (7.7–13.4)
Hiatus	7.0 (2.0–11.0)	7.0 (3.0–11.0)	7.0 (2.0–11.0)	7.1 (4.0–11.0)
Depth of space, mm†				
S2–3	7.3 (2.0–13.0)	6.8 (2.0–11.0)	7.6 (4.0–13.0)	7.5 (4.0–13.0)
Hiatus	2.9 (0.6–8.8)	2.8 (0.6–8.4)	3.0 (1.0–8.8)	3.1 (1.1–4.6)

Values represent median (range).

\* Significant at *P* < 0.05 by Kruskal–Wallis test. † Significant at *P* < 0.05 when one-sample *t* test (two-tailed) was used to compare the mean values between S2–3 and hiatus level.

SCL = sacroccygeal ligament.



**Table 3. Patient Demographics in Study 2**

	Hiatus Group	S2-3 Group
Number	81	81
Age, mo	20.5 (6.0–60.0)	20.0 (4.0–60.0)
Weight, kg	12.0 (7.1–28.0)	11.0 (7.0–26.8)
Height, cm	87.0 (65.0–118.0)	84.5 (63.0–112.0)

Values represent median (range).

2. The median value of the depth of the sacral space at the S2–3 level was significantly wider than the depth of the caudal space at the hiatus level. The distance and depth of the parameters showed a significant difference among age groups in the S2–3 group but not in the hiatus group.

### Study 2

There were no significant differences in demographic data between the two groups (table 3). The overall success rate of block was 96.3% in both groups. Among the punctured cases, the success rate of the first puncture was 96.2% in the S2–3 group and 77.5% in the hiatus group (table 4). Besides the four patients who were excluded after ultrasound examination, two patients in the hiatus group and one in the S2–3 group were excluded from the analysis of characteristics because of failed blockade and missing radiographic images. The numbers of segments occupied with dye per milliliter of drug were not different between the two groups. The degree of drug spread also showed no significant difference between the two groups by dosage according to the type of surgery (fig. 5). The incidence of asymmetric spread was higher in the hiatus group than in the S2–3 group. Pain scores (face, legs, activity, cry, and consolability scale), complication rates, and voiding and discharge times were not different between the two groups (table 5). The amount of radiation detected in the five selected cases was 0.05–0.26 mSv, which was less than the background radiation present in the atmosphere (1–2 mSv).

## Discussion

As the results of study 2 showed, the two groups revealed similar degrees of drug spread within the extradural space, postoperative analgesia, voiding and discharge times, and incidence of side effects.

Most caudal blocks are performed through the sacral hiatus, commonly located at the level of S4–5 in infants and children. Through the sacral hiatus, the needle can easily reach the caudal canal because the sacral hiatus is a fusion defect of the S5 lamina and covered only with skin, subcutaneous fat tissue, and the sacrococcygeal ligament. However, it is sometimes difficult to identify the sacral hiatus because of anatomical variations or plump buttocks. According to a study by Veyckemans *et al.*,<sup>15</sup> the incidence of difficulty in locating the sacral hiatus reached up to 11.2%, especially in children weighing less than 10 kg. Dalens and Hasnaoui<sup>13</sup> reported that the success rate of single-shot caudal block *via* the sacral hiatus was relatively high, up to 96%, in children, but multiple puncture rates also reached as high as 25%. This means that repeated punctures can frequently occur, even after identification of the sacral hiatus. An absent hiatus can also be the reason for failed blocks in approximately 7.7% of patients.<sup>16</sup> The caudal space at the hiatus level is a distal part of the sacral canal, and its depth is variably narrow.<sup>4,14</sup> Therefore, a successful puncture through the hiatus depends on accurate identification of the hiatus and an appropriate needle insertion angle.<sup>4,12,14,15</sup>

In study 1, the median depth of the caudal space at the hiatus level was 2.9 mm (0.6–8.8), which was slightly narrower than in previous studies.<sup>4,14</sup> The median depth of the sacral space at the S2–3 level was 7.3 mm (2.0–13.0), which is comparable to the depth of the mid-lumbar epidural space in adults. Therefore, the margin of space for safe puncture is definitely wider in the S2–3 group than in the hiatus group, although there is a difference in the angle of needle insertion between the two approaches. Furthermore, the S2–3 interspace is easy to identify upon palpation as a reference to the posterior superior iliac spine.<sup>3,9</sup> Considering this, the S2–3 approach has an advantage over the hiatal approach in reducing multiple punctures. In study 2, although the overall success rate was 96.3% in both groups, the success rate of the first attempt was significantly higher in the S2–3 group (96.2%) than in the hiatus group (77.5%). The success rate of the first attempt was also higher compared with previous reports.<sup>9,17,18</sup> However, the first attempt success rate with the hiatal approach was lower than that of our previous study (92.3%).<sup>4</sup> This difference is thought to be due to the determination of the needle angle with prepuncture

**Table 4. Needle Puncture Frequency**

Groups/Frequency*	1	2	3	4	Failed	Dropped Out	Overall Success Rate
Hiatus group (n = 81)	62 (77.5%)	12	3	1	2	1	78/81 (96.3%)
S2–3 group (n = 81)	75 (96.2%)	3	0	0	0	3	78/81 (96.3%)

77.5% and 96.2% represent percentages of cases successful on first attempt of actually punctured cases (not including dropped-out cases).

\*  $P < 0.05$  by Pearson chi-square test.

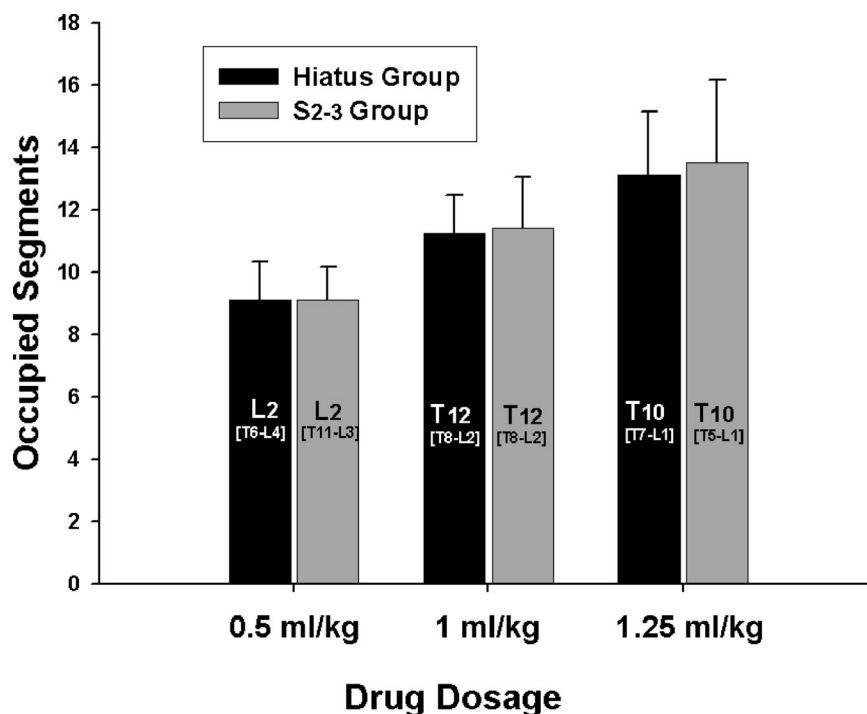


Fig. 5. Drug spread levels by dosage according to the types of surgery in the two groups.

ultrasound and the experience of the practitioners (only two anesthesiologists were involved) in the previous study, thus resulting in a higher first attempt success rate.

In study 2, the small sample rate is a limiting factor for the interpretations of success rate, despite prepuncture ultrasound of the sacral structure.

In the S2-3 approach, a major concern is the risk of dural puncture. Unlike in adults, data on the dural sac end level in children are very limited. It is generally accepted that the dural sac end is commonly located at the S2 level in early childhood. In studies conducted by Counsell *et al.*<sup>19</sup> and Scharf *et al.*<sup>20</sup> using magnetic resonance imaging, the incidences of the dural sac termi-

nating below the S2-3 level in children were reported to be 6.9% and 8.7%, respectively. However, their studies were limited by small study samples (fewer than 30 patients). In study 1, the median level of the dural sac end was S2U (S3M-L5M), and 24 of 317 children (7.57%) showed dural sac ends below S2-3. This result is somewhat similar to that of the studies mentioned above. Regarding these findings, the risk of dural puncture can be assumed to be higher in the S2-3 approach than in the hiatal approach.

In study 1, the median level of dural sac end was S1-2 in children aged 3 years or older (table 2), thus reducing the risk of dural puncture in this age group. Low as it is, the hiatal approach has a reported dural puncture incidence of 0.09–0.5%,<sup>15,21,22</sup> whereas no dural puncture was reported in previous studies on the S2-3 approach.<sup>3,9,17</sup> Considering this, a careful needle approach using the loss-of-resistance technique seems to be an important practical factor in reducing complications. Nonetheless, the incidence of dural puncture can be expected to increase as the number of sacral interspinous block cases increases.

In this study, the drug spread level within the extradural space was determined immediately after drug administration in all patients because extradurally administered radio-opaque dye rapidly disappears from the epidural space. Therefore, the possibility of the late spread of drugs within the extradural space could be considered in practice.

In conclusion, our results showed that the S2-3 approach is relatively easy to perform. The overall success rate and puncture frequency in study 2 supports this. In

Table 5. Characteristics of the Two Groups in Study 2

	Hiatus Group	S2-3 Group
Number	78	77
Segments/ml drug	1.06 ± 0.41	1.14 ± 0.47
Asymmetric spread* (≥ 2 segments)	8	1
FLACC 30 min	2 (0–9)	2 (0–9)
FLACC 2 h	0 (0–3)	0 (0–3)
Voiding time, min	150.3 ± 42.8	145.0 ± 61.8
Discharge time, min	187.5 ± 37.8	198.1 ± 42.2
Adverse effects		
Bleeding	1	0
Urinary retention	4	6
Motor weakness	1	1
Nausea/vomiting	2	2

Values represent number, mean (SD), or median (range). Three failed cases in the hiatus group and four in the S2-3 group (three failed and one missing x-ray image) were excluded from the analysis of the characteristics.

\* Significant at  $P < 0.05$  by Fisher exact test.

FLACC = face, legs, activity, cry, consolability.

addition, fluoroscopic study revealed that immediate spread within the extradural space after drug administration was similar in both groups. We suggest that the S2-3 approach can be applied as a useful fallback method to the conventional landmark approach in children, especially in those older than 36 months who present with difficult identification of sacral hiatus. However, the dural sac may terminate below the S2-3 level in some children, thus requiring careful puncture with a loss-of-resistance technique after ultrasound examination whenever possible.

## References

1. Silvani P, Camporesi A, Agostino MR, Salvo I: Caudal anesthesia in pediatrics: An update. *Minerva Anesthesiol* 2006; 72:453-9
2. Tsui BC, Berde CB: Caudal analgesia and anesthesia techniques in children. *Curr Opin Anaesthesiol* 2005; 18:283-8
3. Busoni P, Sarti A: Sacral intervertebral epidural block. *ANESTHESIOLOGY* 1987; 67:993-5
4. Park JH, Koo BN, Kim JY, Cho JE, Kim WO, Kil HK: Determination of the optimal angle for needle insertion during caudal block in children using ultrasound imaging. *Anaesthesia* 2006; 61:946-9
5. Senoglu N, Senoglu M, Oksuz H, Gumusalan Y, Yuksel KZ, Zencirci B, Ezberci M, Kizilkanat E: Landmarks of the sacral hiatus for caudal epidural block: An anatomical study. *Br J Anaesth* 2005; 95:692-5
6. Quinot JF, Coquelin G: Trans-sacral caudal anesthesia in ambulatory practice in infants: Our experience. *Cah Anesthesiol* 1993; 41:347-8
7. Diel J, Ortiz O, Losada RA, Price DB, Hayt MW, Katz DS: The sacrum: Pathologic spectrum, multimodality imaging, and subspecialty approach. *Radiographics* 2001; 21:83-104
8. Broome DR, Hayman LA, Herrick RC, Braverman RM, Glass RB, Fahr LM: Postnatal maturation of the sacrum and coccyx: MR imaging, helical CT, and conventional radiography. *AJR Am J Roentgenol* 1998; 170:1061-6
9. Kumagai M, Yamashita M: Sacral intervertebral approach for epidural anaesthesia in infants and children: Application of "drip and tube" method. *Anaesth Intensive Care* 1995; 23:469-71
10. Nishiyama T, Hanaoka K, Ochiai Y: The median approach to transsacral epidural block. *Anesth Analg* 2002; 95:1067-70
11. Kim JT, Bahk JH, Sung J: Influence of age and sex on the position of the conus medullaris and Tuffier's line in adults. *ANESTHESIOLOGY* 2003; 99:1359-63
12. Sekiguchi M, Yabuki S, Satoh K, Kikuchi S: An anatomic study of the sacral hiatus: A basis for successful caudal epidural block. *Clin J Pain* 2004; 20:51-4
13. Dalens B, Hasnaoui A: Caudal anesthesia in pediatric surgery: Success rate and adverse effects in 750 consecutive patients. *Anesth Analg* 1989; 68:83-9
14. Adewale L, Dearlove O, Wilson B, Hindle K, Robinson DN: The caudal canal in children: A study using magnetic resonance imaging. *Paediatr Anaesth* 2000; 10:137-41
15. Veyckemans F, Van Obbergh LJ, Gouverneur JM: Lessons from 1100 pediatric caudal blocks in a teaching hospital. *Reg Anesth* 1992; 17:119-25
16. Black MG: Anatomic reasons for caudal anesthesia failure. *Curr Res Anesth Analg* 1949; 28:33-9
17. Dalens B, Chrysostome Y: Intervertebral epidural anaesthesia in paediatric surgery: Success rate and adverse effects in 650 consecutive procedures. *Paediatr Anaesth* 1991; 1:107-17
18. Osaka Y, Yamashita M: Intervertebral epidural anesthesia in 2,050 infants and children using the drip and tube method. *Reg Anesth Pain Med* 2003; 28:103-7
19. Counsell R, Small J, Williams MV: Craniospinal radiotherapy: Where does the thecal sac end? *Radiother Oncol* 1993; 28:180-1
20. Scharf CB, Paulino AC, Goldberg KN: Determination of the inferior border of the thecal sac using magnetic resonance imaging: Implications on radiation therapy treatment planning. *Int J Radiat Oncol Biol Phys* 1998; 41:621-4
21. Uguralp S, Mutus M, Koroglu A, Gurbuz N, Koltuksuz U, Demircan M: Regional anesthesia is a good alternative to general anesthesia in pediatric surgery: Experience in 1,554 children. *J Pediatr Surg* 2002; 37:610-3
22. Dawkins CJ: An analysis of the complications of extradural and caudal block. *Anaesthesia* 1969; 24:554-63