

# Bedside Prediction of Airway Length in Adults and Children

Bong-Jae Lee, M.D.,\* Jae-Woo Yi, M.D.,† Jun Young Chung, M.D.,‡ Dong-Ok Kim, M.D., Ph.D.,§ Jong-Man Kang, M.D.†

**Background:** Malpositioning of the endotracheal tube within the airway leads to serious complications such as endobronchial intubation. Prediction of the correct depth of an endotracheal tube is important and should be individualized. The manubriosternal joint (MSJ) is on the same horizontal plane with the tracheal carina. We compared the straight length from the upper incisor to the MSJ in the fully extended position (incisor-MSJ extension length) with the length from the upper incisor to the carina after intubation with a flexible fiberoptic bronchoscope through the endotracheal tube in the neutral position (incisor-carina neutral length).

**Methods:** One hundred adults and 50 children were studied. Induction of anesthesia was achieved with 1.5 mg/kg propofol and 0.6 mg/kg rocuronium IV. The incisor-MSJ extension length was measured after adequate mask ventilation. After intubation, the endotracheal tube was positioned properly at the upper incisor teeth, and the incisor-carina neutral length was measured with the fiberoptic bronchoscope at the carina.

**Results:** The correlation between the incisor-MSJ extension length and the incisor-carina neutral length is significant ( $P < 0.001$ ) in both adults and children. A formula for the regression line in adults (children) can be obtained as the incisor-carina neutral length (cm) =  $0.868 (1.009) \times$  the incisor-MSJ extension length (cm) +  $4.260 (0.468)$  with a high coefficient of determination;  $r^2 = 0.88 (0.98)$ .

**Conclusions:** The airway length from the upper incisor to the carina in the neutral position can be predicted by the straight length from the upper incisor to the MSJ in the fully extended position.

MALPOSITIONING of the endotracheal tube within the airway leads to serious complications such as endobronchial intubation, which may cause collapse of the non-ventilated lung and barotrauma of the ventilated lung, or vocal cord paralysis and accidental extubation.<sup>1–3</sup> Simple formulas, landmarks, and other methods have been proposed for positioning the endotracheal tube at an adequate depth.<sup>4–7</sup> Prediction of the correct length of an endotracheal tube is important and should be individualized to each patient.

The angle of Louis, the forward prominence formed by the manubriosternal joint (MSJ), is an important landmark in the anatomy of the thorax and on the same horizontal plane with the tracheal carina (fig. 1, A and B).<sup>8</sup> With rigid bronchoscopy, the upper airway and trachea of the

patient in the extended position are aligned in an almost straight line (fig. 2). Therefore, the straight length from the upper incisor to the MSJ in the fully extended position (incisor-MSJ extension length) can be expected to be similar to the real airway length from the upper incisor to the carina. We compared the incisor-MSJ extension length with the length from the upper incisor to the carina after intubation with a flexible fiberoptic bronchoscope through the endotracheal tube in the neutral position (incisor-carina neutral length). In addition, we investigated whether the degree of maximum head extension influences the relationship between the two lengths.

## Materials and Methods

### Participants and Anesthesia

The study was approved by the Institutional Review Board of the Kyung Hee University Hospital (Seoul, Republic of Korea), and written, informed consent was obtained from each adult patient or parent of pediatric patients. One hundred adults (American Society of Anesthesiologists Class 1 or 2) and 50 children presenting for routine elective surgery under general anesthesia were studied between February 2008 and October 2008. Patients with anatomical defects of the face, neck, or upper airway were excluded from the study.

Patients were placed on the operating table with the head in the neutral position. Routine monitors were used. Induction of anesthesia was achieved with 1.5 mg/kg propofol IV. Muscle relaxation was obtained with 0.6 mg/kg rocuronium IV. Anesthesia was maintained with sevoflurane (2–3%).

### Measurements

The fully extended position was obtained by having the patient lie on the flat surface of the operating table and by manually extending the head and neck as much as possible (fig. 1).

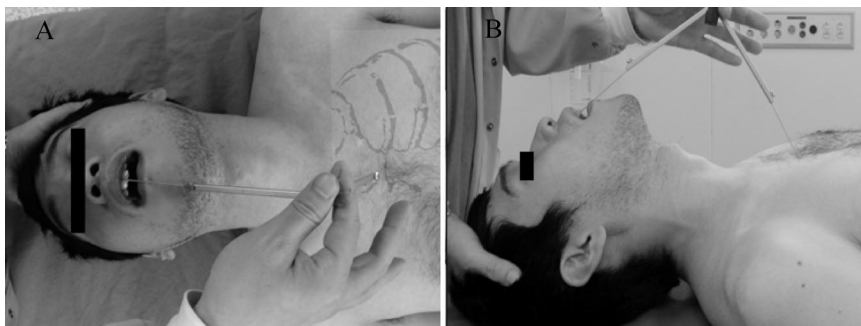
The incisor-MSJ extension length was measured with a specially devised commercial compass after adequate mask ventilation (fig. 1, A and B). The length between both ends of the temporarily fixed commercial compass was measured along the ruler. The degree of maximum head extension was measured indirectly with the eye-ear lines' angle (defined as the angle between the lines from the external ear channel to the superior orbital margin<sup>9</sup> in both neutral and extended positions) (fig. 3). After loss of all four twitches from the train-of-four obtained by ulnar nerve stimulation, a laryngoscopy was performed.

\* Associate Professor, † Assistant Professor, ‡ Fellow, § Professor, Department of Anesthesiology, Kyung Hee University, East-West Neo Medical Center, Seoul, Korea.

Received from the Department of Anesthesiology, Kyung Hee University, East-West Neo Medical Center, Seoul, Korea. Submitted for publication July 16, 2008. Accepted for publication April 29, 2009. Support was provided solely from institutional and/or departmental sources.

Address correspondence to Dr. Kang: Department of Anesthesiology and Pain Medicine, Kyung Hee University, East-West Neo Medical Center, 149 Sangil-dong Gangdong-Gu, Seoul, Korea 134-090. kjm@khnmc.or.kr. Information on purchasing reprints may be found at [www.anesthesiology.org](http://www.anesthesiology.org) or on the masthead page at the beginning of this issue. ANESTHESIOLOGY's articles are made freely accessible to all readers, for personal use only, 6 months from the cover date of the issue.

**Fig. 1.** Estimate of the straight length from upper incisor to the angle of Louis in extended position with specially devised commercial compass in a frontal view (A) and a lateral view (B).



Adult men were intubated with 7.5 mm inner diameter tubes, while 7.0 mm inner diameter tubes were used in adult women patients. An endotracheal tube was chosen using the formula below<sup>10</sup> as a guide for children.

Endotracheal tube size (inner diameter) = Age (yr)/4 + 4.

After intubation, the endotracheal tube was positioned properly at the upper incisor teeth and secured to the upper lip. Neutral position was obtained by having the patient lie on the flat surface of the operating table without head extension or neck flexion.<sup>11</sup> With the head in the neutral position, a fiberoptic bronchoscope (Olympus LF-GP, Olympus Optical Co., Tokyo, Japan) was inserted through a modified right-angle connector (Mallinckrodt Medical, Athlone, Ireland), which allowed bronchoscopic examination during manual ventilation. The incisor-carina neutral length was measured with the fiberoptic bronchoscope through the endotracheal tube at the carina. The bronchoscopist was blind to the incisor-MSJ extension length. The whole procedure of identifying carina, upper incisor, and measuring the length of bronchoscope took only about 10 s. No patient experienced oxygen desaturation.

#### Statistical Analysis

A pilot study of 15 patients, including 4 children, showed a mean (SD) of 23.4 (3.06) and 24.3 (3.09) in the incisor-MSJ extension length and the incisor-carina neutral length, respectively. A sample size 7 was calculated for a Type I error of 0.01 and a power of 0.99 using the PASS 2008 (Trial) Version 08.0.7 Windows version

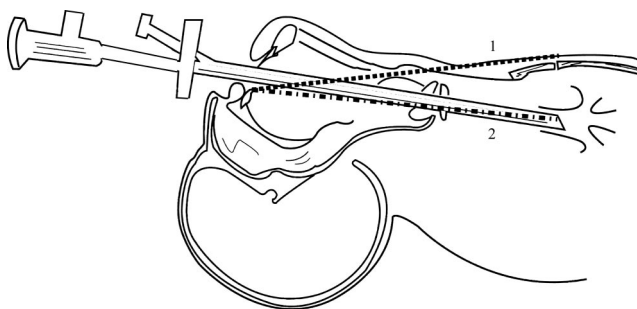
(NCSS, LLC, Kaysville, UT). However, we recruited 100 adults and 50 children for general consistency, based on central limit theory.

Linear regression and correlation were used to analyze the relationships among the measured data using SPSS for Windows version 12.0 (SPSS, Chicago, IL). The degree of agreement of the incisor-MSJ extension length and incisor-carina neutral length was assessed by Bland and Altman method.<sup>12</sup> A *P* value of less than 0.05 was considered to be significantly different.

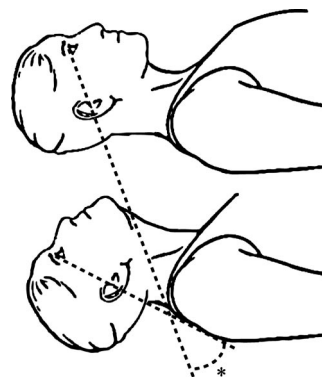
#### Results

The details of the patients studied are given in tables 1 and 2.

The correlation between the incisor-MSJ extension length and the incisor-carina neutral length in adults is significant ( $P < 0.001$ ) with a high coefficient of determination ( $r^2 = 0.88$ ); a regression line was derived (fig. 4A). A formula for this regression line can be obtained as the incisor-carina neutral length (cm) =  $0.868 \times$  the incisor-MSJ extension length (cm) + 4.260. The correlation between the incisor-MSJ extension length and the incisor-carina neutral length in children is significant ( $P < 0.001$ ), with a high coefficient of determination ( $r^2 = 0.98$ ). A regression line was derived (fig. 4B). A formula for this regression line can be obtained as the incisor-carina neutral length (cm) =  $1.009 \times$  the incisor-MSJ extension length (cm) + 0.468.



**Fig. 2.** Rigid bronchoscopy. Straight length from upper incisor to the angle of Louis in extended position (1). Straight length from upper incisor to the carina in extended position (2).



**Fig. 3.** Eye-ear lines' angle. \* The eye-ear lines' angle is the angle between the lines from the external ear channel to the superior orbital margin in both neutral and extended positions.

**Table 1. Adult Patient Characteristics**

	Men (n = 50)	Women (n = 50)
Age (yr)	42 (17–75)	41 (15–76)
Height (cm)	171 (155–187)	158 (143–171)
Weight (kg)	70 (51–94)	57 (41–85)

Values are mean (range).

The difference between the incisor-MSJ extension length and the incisor-carina neutral length is not linearly correlated with eye-ear lines' angle (fig. 4, C and D).

Bland and Altman plots demonstrated a good agreement between the two lengths. The means of the differences between the two lengths were 1.03 cm (95% CI 0.86 ~ 1.20) in adults, and 0.63 cm (95% CI 0.46 ~ 0.79) in children (fig. 5, A and B).

We compared our formula ( $0.868 \times \text{the incisor-MSJ extension length [cm]} + 4.260$ ) with the formula of Cherng *et al.*<sup>13</sup> ( $0.1977 \times \text{height [cm]} - 7.7423$ ) (instead of 12.7423, because those authors estimated the length of the airway from the mouth to 5 cm above the carina) using the data of our adult patients. We regarded the incisor-carina neutral length as the true airway length. Bland and Altman plots demonstrated the difference of the two formulae (fig. 6, A and B).

## Discussion

According to the measured data of the present study, the relationship of the incisor-MSJ extension length and the incisor-carina neutral length is significantly correlated.

There are several categories of estimating the optimal endotracheal tube length in orotracheally intubated patients. The first category is using clinical criteria, including auscultation of bilateral breath sounds, symmetric chest expansion, and palpation of the endotracheal tube cuff in the suprasternal notch.<sup>14,15</sup> However, auscultation of the chest bilaterally and visualization of symmetrical chest expansion cannot be a reliable method for detecting the endobronchial intubation, and the cuff palpation method should not be used to verify location within the trachea.<sup>14–16</sup> The second category is prediction of airway length from mouth or nares to carina using age, height, weight, foot length, or arbitrarily determined length.<sup>1,5,9,13,17</sup> However, these methods do not

seem to have reasonable rationale, may not be always individualized to each patient, and the correlation coefficients are not high.<sup>5</sup> The third category determines how far a certain mark of the endotracheal tube has proceeded beyond the vocal cords.<sup>4,9</sup> However, these methods cannot be applied to vocal cords that cannot be visualized, and the distance between the tube tip and the carina cannot be optimally predicted.<sup>4</sup> The fourth category is postintubation confirmation of endotracheal tube placement by chest radiograph or fiberoptic bronchoscopic examination.<sup>18</sup> These methods are definitive but involve additional costs and efforts. The fifth category is the method made on topographic measurements and has the advantage of individualization and ease of use.<sup>19</sup>

The correlations between predictor and observation were 0.17, 0.28, and 0.63 of r-squared values in adults in the previous articles,<sup>5,13</sup> while 0.88 in this study. The r-squared value between height and tracheal length was 0.59 using our data of adult patients. The r-squared values between age (weight, height, foot length, head circumference) and tracheal length were 0.82 (0.79, 0.85, 0.79, and 0.60) in pediatrics,<sup>9,17</sup> as compared with 0.98 in children of our model. Because of the different study population and methodology among these previous studies, it is difficult to determine superiority of one method to others for prediction of airway length. Using our patient data, however, we found a higher r-squared value and smaller variation in the Bland and Altman plots in our formula using the incisor-MSJ length than those in Cherng *et al.*'s formula<sup>13</sup> using the height, indicating superiority of our prediction formula.

The angle of Louis can be easily palpated near the second rib insertion to the MSJ (fig. 1A). It is stated that the plane of division into upper and lower mediastinum traverses the MSJ and the lower surface of the fourth thoracic vertebra, and that the plane passes horizontally through the sternal angle and also the bifurcation of the trachea.<sup>8,20</sup> The tracheal carina was above the MSJ plane in 9 patients (17.6%), at the plane in 21 patients (41%), and below it in 21 patients (41%).<sup>21</sup>

While performing rigid bronchoscopy, the upper airway and trachea of the patient in extension position are forced into an almost straight line (fig. 2). Therefore, the incisor-MSJ extension length can be expected to be similar to the real airway length (carina to upper incisor).

Flexion of the neck from the neutral position can result in the tip of the endotracheal tube moving as much as 3 cm, with a mean value of 1.9 cm, closer to the carina, while extension can displace the endotracheal tube by as much as 5 cm, with a mean value of 1.9 cm, farther from the carina.<sup>22</sup> The incisor-MSJ extension length may not be equal to the real airway length in the extended position because the real airway course is not straight unless it is forcibly aligned in a straight line by the rigid bronchoscope. We think that the straightened airway length after insertion of the rigid bronchoscope is

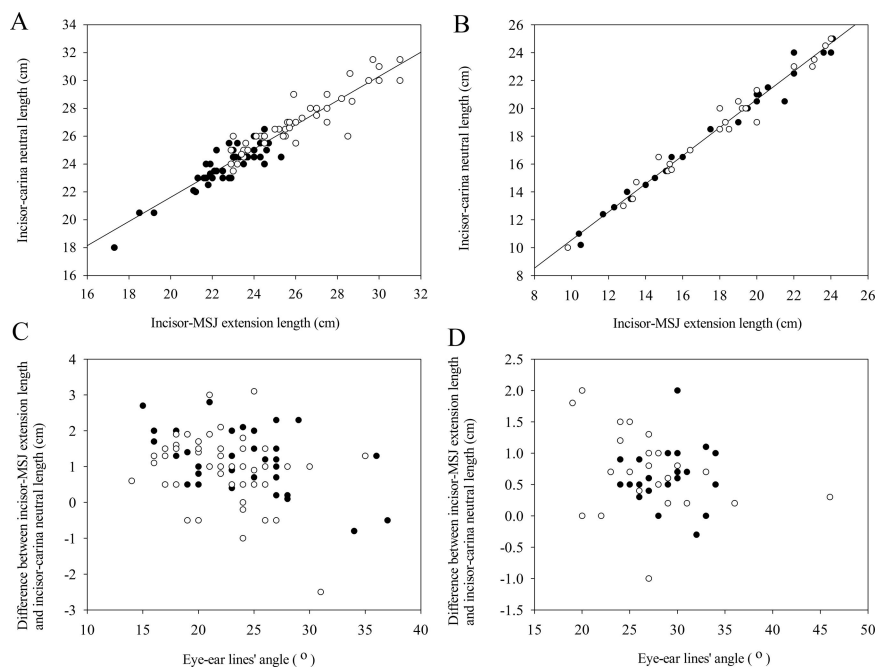
**Table 2. Child Patient Characteristics**

	Boys (n = 25)	Girls (n = 25)
Age (yr)	6.5 (0.7–14.5)	5.9 (0.7–14.2)
Height (cm)	121 (65–170)	116 (68–163)
Weight (kg)	24 (7.5–69)	21 (7.5–63)

Values are mean (range).



**Fig. 4.** (A) and (B): The incisor-carina neutral length (Y axis) is plotted against the incisor-MSJ extension length (X axis) for all 100 adults and 50 children, respectively ( $\circ$  = male;  $\bullet$  = female). The formula of the regression line is  $Y = 0.868 \times X + 4.260$  (solid line), and  $Y = 1.009 \times X + 0.468$  (solid line), respectively. The coefficient of determination ( $r^2$ ) is 0.88 and 0.98, respectively ( $P < 0.001$ ). (C) and (D): The difference between the incisor-carina neutral length and the incisor-MSJ extension length (Y axis) is plotted against the eye-ear lines' angle (X axis) for all 100 adults and 50 children, respectively ( $\circ$  = male;  $\bullet$  = female). The incisor-carina neutral length is the length from the upper incisor to the carina after intubation with a flexible fiberoptic bronchoscope through the endotracheal tube in neutral position. The incisor-MSJ extension length is the straight length from upper incisor to the manubriosternal joint (MSJ) in extended position.



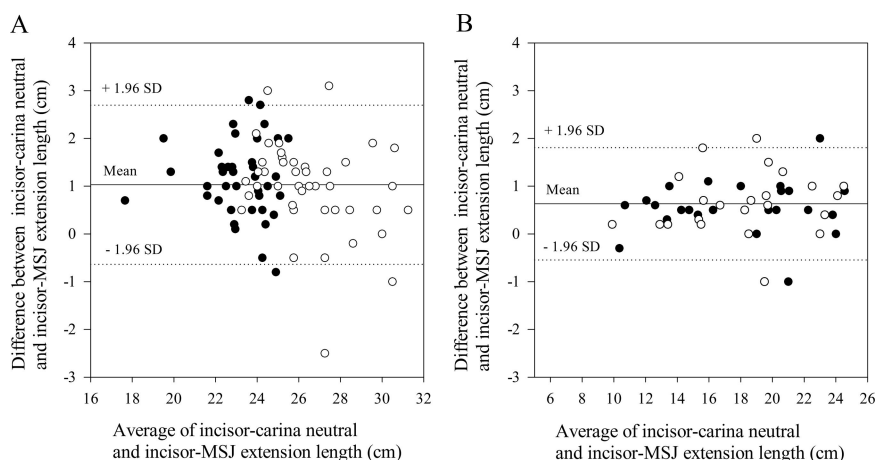
associated with the real airway length, and since the incisor-MSJ extension length may be similar to the straightened airway length after insertion of rigid bronchoscope, incisor-MSJ extension length must have some relation to the real airway length. Moreover, the length measured with a fiberoptic bronchoscope was through the endotracheal tube, and the endotracheal tube itself is not flexible enough to follow the airway path, meaning that the endotracheal tube itself may have straightened the airway path a little bit.

Our method can be applied in the operating room, intensive care unit, emergency room, and out of hospital (e.g., with emergency services) to avoid endobronchial intubation, and may be superior to other methods in that this method gives the whole airway length directly and individually irrespective of sex, age, and height. We suggest that this method may be the first choice of airway length prediction and combined with previous methods.

Although a special compass was used to measure the incisor-MSJ extension length precisely, a ruler or endotracheal tube itself (after straightened by force) could be used easily and rapidly in clinical setting only if it is oriented parallel to the line from the upper incisor to the angle of Louis. Moreover, for ease of clinical use, we suggest adding 1 cm (the mean difference between the two lengths) in adults and 0.6 cm in children to the incisor-MSJ extension length, rather than using the complex formulae.

This study has several limitations. First, this method cannot be applied to patients with limited head extension. Second, the difference between the incisor-MSJ extension length and the incisor-carina neutral length is not always regular. This is caused by the individual difference of the level of the MSJ compared to the carina and the status of the endotracheal tube curvature within the airway in the neutral position. However, this method is very simple and precise, as compared with other methods. Third, unexpectedly, the difference between

**Fig. 5.** (A) and (B): Bland and Altman plots for all 100 adults and 50 children, respectively ( $\circ$  = male;  $\bullet$  = female). The means of the differences between the two lengths were 1.03 cm (95% CI 0.86 ~ 1.20) in adults, and 0.63 cm (95% CI 0.46 ~ 0.79) in children. The incisor-carina neutral length is the length from the upper incisor to the carina after intubation with a flexible fiberoptic bronchoscope through the endotracheal tube in neutral position. The incisor-MSJ extension length is the straight length from upper incisor to the manubriosternal joint (MSJ) in extended position.



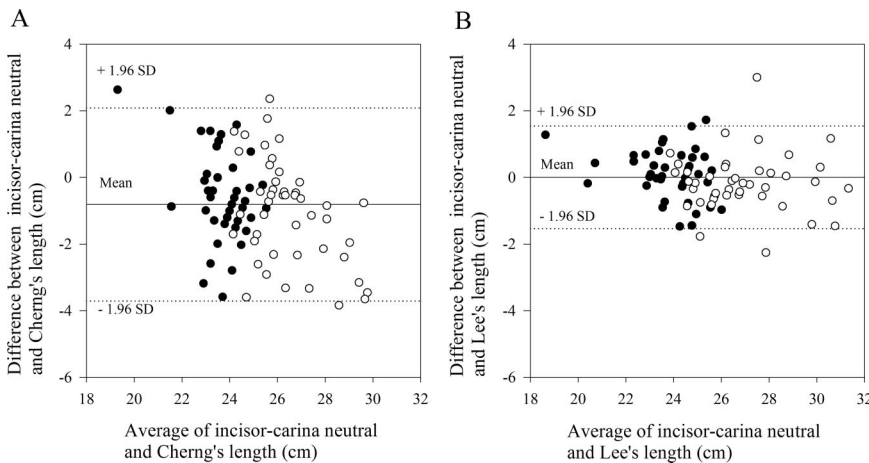


Fig. 6. (A) and (B): Bland and Altman plots for all 100 adults ( $\circ$  = men;  $\bullet$  = women). The means of the differences between the two lengths were  $-0.81$  cm (95% CI  $-1.10 \sim -0.52$ ) with the formula of Cherg *et al.*,<sup>13</sup> and  $0.00$  cm (95% CI  $-0.16 \sim 0.15$ ) with our formula. The incisor-carina neutral length is the length from the upper incisor to the carina after intubation with a flexible fiberoptic bronchoscope through the endotracheal tube in neutral position. Cherg *et al.*'s length =  $0.1977 \times \text{height (cm)} - 7.7423$ . Lee's length =  $0.868 \times \text{the incisor-MSJ extension length (cm)} + 4.260$ . The incisor-MSJ extension length is the straight length from upper incisor to the manubriosternal joint (MSJ) in extended position.

the incisor-MSJ extension length and the incisor-carina neutral length was poorly correlated with the 'eye-ear lines' angle. This may be partly caused by the individual variation of the relationship of the head and cervical vertebrae. Further studies about this are needed. Fourth, we could not include neonates because we did not have an ultrathin fiberoptic bronchoscope.

In conclusion, this study demonstrated that the airway length from the upper incisor to the carina with the head placed in the neutral position can be predicted by the straight length from the upper incisor to the MSJ in the fully extended position.

## References

- Owen RL, Cheney FW: Endobronchial intubation: A preventable complication. *ANESTHESIOLOGY* 1987; 67:255-7
- Zwillich CW, Pierson DJ, Creagh CE, Sutton FD, Schatz E, Petty TL: Complications of assisted ventilation. A prospective study of 354 consecutive episodes. *Am J Med* 1974; 57:161-70
- Cavo JW Jr: True vocal cord paralysis following intubation. *Laryngoscope* 1985; 95:1352-9
- Mehta S: Intubation guide marks for correct tube placement. A clinical study. *Anaesthesia* 1991; 46:306-8
- Eagle CC: The relationship between a person's height and appropriate endotracheal tube length. *Anaesth Intensive Care* 1992; 20:156-60
- Patel N, Mahajan RP, Ellis FR: Estimation of the correct length of tracheal tubes in adults. *Anaesthesia* 1993; 48:74-5
- Freeman JA, Fredricks BJ, Best CJ: Evaluation of a new method for determining tracheal tube length in children. *Anaesthesia* 1995; 50:1050-2
- Williams PL, Bannister LH, Berry MM, Collins P, Dyson M, Dussek JE, Ferguson MW: Gray's Anatomy. The Anatomical Basis of Medicine and Surgery, 38th Edition. Edinburgh, Churchill Livingstone, 1995, pp 1677
- Weiss M, Gerber AC, Dullenkopf A: Appropriate placement of intubation depth marks in a new cuffed paediatric tracheal tube. *Br J Anaesth* 2005; 94:80-7
- Morgan GA, Steward DJ: A pre-formed paediatric orotracheal tube designed based on anatomical measurements. *Can Anaesth Soc J* 1982; 29:9-11
- Adnet F, Borron SW, Dumas JL, Lapostolle F, Cupa M, Lapandry C: Study of the "sniffing position" by magnetic resonance imaging. *ANESTHESIOLOGY* 2001; 94:83-6
- Bland JM, Altman DG: Statistical methods for assessing agreement between two methods of clinical measurement. *Lancet* 1986; 1:307-10
- Cherg CH, Wong CS, Hsu CH, Ho ST: Airway length in adults: Estimation of the optimal endotracheal tube length for orotracheal intubation. *J Clin Anesth* 2002; 14:271-4
- Triner L: A simple maneuver to verify proper positioning of an endotracheal tube. *ANESTHESIOLOGY* 1982; 57:548-9
- Pollard RJ, Lobato EB: Endotracheal tube location verified reliably by cuff palpation. *Anesth Analg* 1995; 81:135-8
- Birmingham PK, Cheney FW, Ward RJ: Esophageal intubation: A review of detection techniques. *Anesth Analg* 1986; 65:886-91
- Embleton ND, Deshpande SA, Scott D, Wright C, Milligan DW: Foot length, an accurate predictor of nasotracheal tube length in neonates. *Arch Dis Child Fetal Neonatal Ed* 2001; 85:F60-4
- Dietrich KA, Strauss RH, Cabalka AK, Zimmerman JJ, Scanlan KA: Use of flexible fiberoptic endoscopy for determination of endotracheal tube position in the pediatric patient. *Crit Care Med* 1988; 16:884-7
- Evron S, Weisenberg M, Harow E, Khazin V, Szmuk P, Gavish D, Ezri T: Proper insertion depth of endotracheal tubes in adults by topographic landmarks measurements. *J Clin Anesth* 2007; 19:15-9
- McMinn RM: Last's Anatomy, Regional and Applied, 9th Edition. Edinburgh, Churchill Livingstone, 1994, pp 254
- Chukwumeka A, Currie L, Ellis H: CT anatomy of the mediastinal structures at the level of the manubriosternal angle. *Clin Anat* 1997; 10:405-8
- Conrardy PA, Goodman LR, Lainge F, Singer MM: Alteration of endotracheal tube position. Flexion and extension of the neck. *Crit Care Med* 1976; 4:7-12