

Four-limb Neurostimulation with Neuroelectrodes Placed in the Lower Cervical Epidural Space

Salim M. Hayek, M.D., Ph.D.,* I. Elias Veizi, M.D., Ph.D.,† Michael Stanton-Hicks, M.B.B.S.‡

SPINAL cord stimulation (SCS) involves electrical stimulation of large afferents ($A\beta$ fibers) in the dorsal columns of the spinal cord by neuroelectrodes placed in the epidural space. Stimulation elicits tingling sensation (paresthesiae) in the corresponding dermatome and inhibits small-diameter nociceptive afferents ($A\delta$ and C fibers), which transmit painful sensations.¹ Stimulation for painful entities involving the upper limbs typically requires cervical placement of neuroelectrodes, whereas stimulation for lower extremity pain entails placing the leads in the low thoracic spine.² Paresthesiae induced by SCS are generally sought over the targeted painful areas,³⁻⁶ though subthreshold stimulation (stimulation below the perception threshold, not felt by the patient as paresthesiae) has recently been reported as effective.^{7,8} Clinical experience and a few case reports suggest the possibility of obtaining stimulation in the lower extremity, in addition to upper extremity stimulation, with neuroelectrodes placed in the cervical epidural space.⁹⁻¹¹ Patients with pain in all four extremities that may be amenable to management with SCS may benefit from such intervention, provided that consistent and reproducible stimulation can be accomplished. The objective of this report is to determine whether it is feasible to consistently achieve stimulation coverage of all limbs with two percutaneous cervical leads placed in the epidural space of the lower cervical spine. In addition, short-term effectiveness of the modality was examined by functional outcomes in patients who proceeded to permanent implantation of cervical neuroelectrodes.

Case Series

Twelve patients from the Cleveland Clinic Pain Management Department and University Hospitals Case Medical Center, Division of Pain

* Chief, Division of Pain Medicine, Department of Anesthesiology, University Hospitals Case Medical Center, Case Western Reserve University; OUTCOMES RESEARCH Consortium, the Cleveland Clinic Foundation. † Research Associate, Division of Pain Medicine, Department of Anesthesiology, University Hospitals Case Medical Center, Case Western Reserve University. ‡ Vice-Chairman of the Anesthesiology Institute, Department of Pain Management, the Cleveland Clinic Foundation.

Received from the Department of Anesthesiology, University Hospital Case Medical Center, Case Western Reserve University, and Department of Pain Management, the Cleveland Clinic Foundation, Cleveland, Ohio. Submitted for publication July 8, 2008. Accepted for publication October 6, 2008. Support was provided solely from institutional and/or departmental sources.

Address correspondence to Dr. Hayek: Division of Pain Medicine, Department of Anesthesiology, University Hospitals of Cleveland, 11100 Euclid Avenue, Cleveland, Ohio 44106. salim.hayek@uhhospitals.org. Information on purchasing reprints may be found at www.anesthesiology.org or on the masthead page at the beginning of this issue. ANESTHESIOLOGY's articles are made freely accessible to all readers, for personal use only, 6 months from the cover date of the issue.

Medicine, Cleveland, Ohio, underwent cervical spinal cord stimulation trial and/or implantation over a 2-year period (2005-2007) for treatment of diffuse limb pain. All patients experienced pain that had not responded to conventional treatment, which included sympathetic and somatic nerve blocks, pharmacologic therapy, and physical therapy. Prestudy screening included psychological evaluation and a negative pregnancy test for women of childbearing age. Enrolled patients were determined to be candidates for cervical spinal cord neurostimulation. There were nine women and three men, ranging in age from 42 to 71 yr, with a median age of 48 yr. Pain was localized to at least one upper and one lower extremity and was often associated with some pain in the shoulders or lower back. Patients who were studied had the following diagnosis: complex regional pain syndrome (CRPS) type I (6 patients), peripheral vascular disease (1 patient), neuropathic pain persisting after cervical laminectomy and lumbar laminectomy (2 patients), chemotherapy-induced neuropathy (1 patient), myelopathy status post cervical fusion (1 patient), and multiple system atrophy (1 patient). Visual analog scale (VAS) score, Pain Disability Index (PDI) score,¹² and mapping of the areas of pain were obtained before the procedure, at the end of the trial period (only VAS score), and at follow-up 1 month after implantation (VAS score and PDI score). SCS was conducted using percutaneous octapolar neuroelectrode leads with 1-mm spacing and 3-mm-long electrodes (Boston Scientific, Valencia, CA). The leads were introduced into the upper thoracic epidural space at T2-T3 using a paraspinous approach with a 14-gauge Tuohy needle during fluoroscopy. The neuroelectrode leads were advanced during fluoroscopic guidance to the lower cervical epidural space, just off midline on each side (fig. 1A). Stimulation was then performed with one cathode and one anode per lead (usually electrode contacts 3 and 5 or 4 and 6). Each lead was then trolled in a cephalad or caudad direction until stimulation of the ipsilateral upper and lower extremities was obtained. The leads were then anchored to the skin during trials and to the supraspinous ligament and fascia during implantations. At the conclusion of the procedure, complex postoperative programming was allowed to proceed in the recovery area, for optimal coverage parameters (fig. 1B). Trials periods ranged between 7 and 14 days, and if successful (50% or better pain relief), permanent implantation was performed at a future date with new leads placed and attached to an implanted rechargeable programmable generator.

Results

Patients underwent trials with dual neuroelectrodes with the lead tip positioned between lower C3 vertebral body and upper portion of C7 vertebral body level. In all, 11 of 12 patients studied experienced paresthesiae in all four extremities (91.6% of patients). Four-limb coverage was not obtained in 1 patient with multiple system atrophy. In 5 patients (45% of the cases), coverage of four extremities was achieved using a single lead with a stimulation frequency of 40 Hz (with one exception at 200 Hz). Pulse width applied ranged between 190 and 870 μ s (median, 470 μ s; $n = 5$; table 1). In the remaining 7 patients (table 2), both right and left leads were used to achieve four-extremity coverage. The stimulation parameters used that

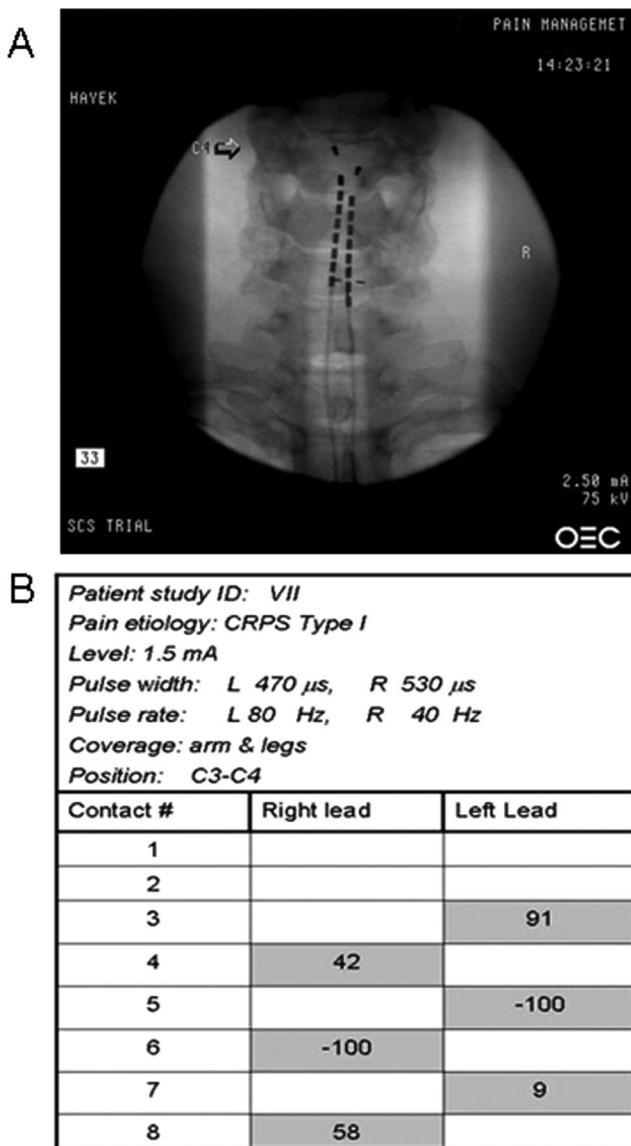


Fig. 1. Cervical placement of dual spinal cord stimulator leads for four-extremity paresthesiae coverage. (A and B) Cervical spinal cord stimulation in a patient with complex regional pain syndrome type I. (A) Radiograph displaying cervical spine with spinal cord stimulator lead tips at C4. (B) Stimulation parameters that achieved four-limb paresthesiae for the patient described. Note that both leads are used, and the current is fractionated through three nonconsecutive contacts (right contacts 4, 6, and 8 and left contacts 3, 5, and 7).

resulted in successful four-limb paresthesiae were (1) frequencies (median values, $n = 7$) of 60 Hz for the right lead and 40 Hz for the left lead and (2) pulse width (median values, $n = 7$) of 550 μ s for the right lead and 530 μ s for the left lead. In 9 cases (81.8%), current was fractionated between more than two contacts of each lead. In 2 cases (18.2%), two nonconsecutive contacts were sufficient to provide excellent four-limb coverage. No distinct electrode array was found common to the successful stimulation of any subject in the 10 cases where current was fractionated. Current was fractionated between consecutive contacts in 58% of the leads regardless of polarity.

This series of patients underwent 12 trials and 7 SCS implants: (1) 5 cervical SCS implants (41.5%) in 3 patients with CRPS, 1 patient with peripheral vascular disease, and 1 patient with persistent radicular pain after cervical and lumbar spine fusion; and (2) 2 low thoracic SCS implants in 1 patient with cervical myelopathy and 1 patient with small fiber neuropathy. The low thoracic SCS implants evidently resulted in lower extremity coverage and were performed purely based on patient choice. Both patients cited that their pain involved predominantly the lower extremities and that they did not feel that the upper extremity discomfort was marked enough to warrant coverage with SCS. Of the 12 patients, 5 did not have permanent implantation because of the perceived lack of adequate pain relief during the SCS trial period.

Long-term clinical outcomes results were not sought in this technical report and as such have not been addressed here. However, there was significant short-term (1-month) relief of pain and improvement in PDI scores in patients who had permanent cervical SCS implantation and who achieved four-limb paresthesiae. At the start of the trial, the mean VAS score was 8.86 ± 0.66 for the 5 patients proceeding to permanent cervical implantation, and at 1 month after implantation, VAS scores dropped to 5.56 ± 0.8 ; this reflects a significant 38% decrease in pain (paired t test, $P < 0.0065$, $n = 5$). Furthermore, PDI scores at the start of the trial ranged from 48 to 68 (the PDI has a maximum score of 70), with a mean value of 64.4. At 1 month after implantation, PDI scores ranged from 32 to 46, with a mean value of 35. This represents a significant (nearly 40%) improvement in function (paired t test, $P < 0.00045$, $n = 5$).

Apart from technical feasibility, conclusions on the efficacy of this modality in particular clinical settings are hindered by the limited number of patients studied and their diverse diagnoses. However, half of the study population was CRPS patients (6 of 12), and in 3 of 6 (50% of the CRPS patients), cervical SCS did provide good four-extremity paresthesiae that resulted in pain relief and permanent implantation. Two of the 3 patients for whom cervical SCS was not effective were Bureau of Workers' Compensation patients with CRPS type I, whereas 1 of the 3 effective trials was in a Bureau of Worker's Compensation patient. A meaningful assessment of the question whether cervical SCS improves long-term clinical outcome in CRPS patients with pain in more than two extremities would require larger numbers and longer clinical follow-up of the patients.

Discussion

The significant finding in this report is that it is possible to elicit consistent four-extremity paresthesiae with electrical neurostimulation of the lower cervical spinal

Table 1. Stimulation Parameters and Electrode Location Used in Patients Who Achieved Four-limb Paresthesia Coverage with Activation of a Single Neuroelectrode

Case	Pain Condition	Lead Tip Location	Stimulation Frequency, P Rate, Hz	Pulse Width, μ s
V	Peripheral vascular disease	C4–C5	40	190
VI	Cervical and lumbar surgery	C4	200	630
VIII	Complex regional pain syndrome	C4	40	410
X	Postlaminectomy syndrome/radiculopathy	C3–C4	40	870
XII	Complex regional pain syndrome	C5–C6	40	470

cord. Our results demonstrate an almost 92% incidence of four-extremity neurostimulation in our cohort of 12 patients with epidurally sited leads placed slightly lateral to the midline sagittal plane of the cervical spinal cord with the tip of neuroelectrode leads lying between the lower portion of C3 to the upper portion of C7. Stimulation parameters used to generate paresthesiae in each of four limbs included relatively longer pulse widths and low frequencies¹⁰ (tables 1 and 2). Patients who received permanent implants continued, in the short-term, to have good four-extremity coverage with improvement in both pain and quality-of-life measures. In a single case of multiple system atrophy, a degenerative disease of multiple sites in the nervous system associated with nerve cell loss, gliosis, and atrophy of the affected region,^{13,14} we were unable to achieve four-limb stimulation.

To correlate the spinal levels of lead position with the stimulating areas, Barolat *et al.*¹⁵ empirically collected data from 106 patients and developed a database to serve as a sensory map of the spinal cord responses to electrical stimulation. The authors did not, however, discuss whether cervical neurostimulation could achieve coverage of all four extremities.¹⁵ In a previous limited study, we reported coverage of all four extremities with stimulation of the cervical spine using octapolar leads with their tips at C4–C7.¹¹ This type of coverage was observed in another study by implanting surgical leads using a retrograde approach at C1–C2. These authors argued that these results were due to the SCS design architecture used because they were unable to achieve four-extremity coverage with a frequency limit of 120 Hz but were successful with electrodes that permitted high frequency stimulation (1,500 Hz). The lead tip location after retrograde insertion was at the C2 level.¹⁶ Vallejo *et*

*al.*⁹ reported that 3 of 5 patients undergoing cervical SCS for upper extremity pain experienced four-extremity coverage while using percutaneous neuroelectrodes with placement of the lead tip at C2–C4 level.

There are several reasonable hypotheses that could explain the paresthesiae coverage of four extremities with medial lead placement of neuroelectrodes in the lower cervical epidural space:

1. The dorsal cerebrospinal fluid thickness may be reduced in this region such that the lead is closer to the spinal cord and paresthesia likelihood is increased due to higher recruitment of lateral dorsal column fibers representing rostral dermatomes and deeper medial fibers representing caudal dermatomes. This would remain to be proven because we are not aware of any study addressing dorsal cerebrospinal fluid thickness and electrode impedance in the cervical segments.
2. There is a discrete topographic location in the cervical spinal cord where the fasciculus gracilis fibers have a favorable orientation for epidural electrical neuromodulation. The dorsal column consists of the fasciculus gracilis, which conducts most of the lower body sensation below T6, and the fasciculus cuneatus, which transmits most of the upper extremity sensation. Attempts at mapping of the dorsal columns at different segmental levels of the human spinal cord^{17,18} have shed insight into which fibers are likely to be activated by electrical stimulation.¹⁹ Important topographic configuration rearrangements occur as the dorsal column tracts ascend along the spinal cord from the lumbar to the cervical spine. As the upper extremity fasciculus cuneatus fibers enter the cord in

Table 2. Stimulation Parameters and Electrode Location Used in Patients Who Achieved Four-limb Paresthesia Coverage with Two Active Neuroelectrodes

Case	Pain Condition	Electrode Tip Location	Stimulation Frequency, Rate, Hz		Pulse Width, μ s	
			Left Lead	Right Lead	Left Lead	Right Lead
I	Cervical fusion/myelopathy	C4–C5	100	30	550	840
II	Small-fiber neuropathy	C4	80	40	410	520
III	Complex regional pain syndrome	C3–C4	30	30	630	480
IV	Complex regional pain syndrome	C5–C6	40	40	190	330
VII	Complex regional pain syndrome	C4–C5	80	40	470	530
IX	Multiple system atrophy (unsuccessful)	C4–C5	80	80	870	870
XI	Chemotherapy induced neuropathic pain	C5–C6	40	40	770	580

large numbers at the cervicothoracic junction, there is mechanical pressure on the fasciculus gracilis fibers, which change position in the cervical segment from parallel to dorsal horns caudally to approximately parallel to the median septum rostrally and closer to midline. These findings not only provide a likely morphometric explanation for the observed four-limb stimulation pattern, but also seem to be in concert with neurophysiologic studies by Whitsel *et al.*²⁰ Using degeneration studies and microelectrode recordings, these investigators found that organization of fibers was dermatomal in the lumbar cord but topographic in the cervical cord, arguing for a specific constant relation of nerve fibers along the cervical cord. This lends support to our hypothesis for a specific anatomical location favorable to four-limb stimulation.

3. Rearrangement of nerve fibers in the cervical region due to the entry of the large cervical bundles is such that large fibers assume a superficial position more amenable to relatively low-frequency electrical neurostimulation. Because of the complexity of the cervical spinal cord structure and the continuous changes in dorsal column fiber positioning along the C7 to C2 level, the density and position of large sensory fibers ($A\beta$) is not as well understood as it is in the lower spinal cord levels up to T10–T11.¹⁹ At this time, comparable morphometric studies that explore the cervical region of spinal cord do not exist.

In conclusion, this limited technical report suggests that placing neuroelectrode leads medially in the cervical epidural space with leads overlying mainly C4–C7 would achieve neurostimulation that covers both the upper and lower extremities. It is plausible that in this anatomical space, the orientation of dorsal column fibers creates a target zone whereby stimulation above perception threshold results in paresthesiae of all four extremities. More detailed studies are needed to address both function and topographic anatomy in the cervical spine to improve our understanding of neurophysiology and SCS mechanisms. Furthermore, it is necessary to examine the long-term outcome of cervical spinal cord stimulation in the context of specific disease entities involving all four extremities and to establish appropriate treatment criteria.

The authors thank Thomas Yearwood, M.D., Ph.D. (Pain Management Specialist, Comprehensive Pain and Rehabilitation, Daphne, Alabama), and Marshall Devor, Ph.D. (Professor, Department of Cell and Animal Biology, Institute of Life Sciences and Center for Research on Pain, Hebrew University of Jerusalem, Jerusalem, Israel), for helpful discussions.

References

1. Melzack R, Wall PD: Pain mechanisms: A new theory. *Science* 1965; 150: 971–9
2. Forouzanfar T, Kemler MA, Weber WE, Kessels AG, van Kleef M: Spinal cord stimulation in complex regional pain syndrome: Cervical and lumbar devices are comparably effective. *Br J Anaesth* 2004; 92:348–53
3. Sanchez-Ledesma MJ, Garcia-March G, Diaz-Cascajo P, Gomez-Moreta J, Broseta J: Spinal cord stimulation in deafferentation pain. *Stereotact Funct Neurosurg* 1989; 53:40–5
4. Petrakis IE, Sciacca V: Spinal cord stimulation in critical limb ischemia of the lower extremities: Our experience. *J Neurosurg Sci* 1999; 43:285–93
5. Lind G, Meyerson BA, Winter J, Linderth B: Implantation of laminotomy electrodes for spinal cord stimulation in spinal anesthesia with intraoperative dorsal column activation. *Neurosurgery* 2003; 53:1150–3
6. Allegrini M, Arachi G, Barbieri M, Paulin L, Bettaglio R, Bonetti G, Demartini L, Violini A, Braschi A, Bonezzi C: Prospective study of the success and efficacy of spinal cord stimulation. *Minerva Anestesiol* 2004; 70:117–24
7. Eddicks S, Maier-Hauff K, Schenk M, Muller A, Baumann G, Theres H: Thoracic spinal cord stimulation improves functional status and relieves symptoms in patients with refractory angina pectoris: The first placebo-controlled randomized study. *Heart* 2007; 93:585–90
8. Benyamin R, Kramer J, Vallejo R: A case of spinal cord stimulation in Raynaud's phenomenon: Can subthreshold sensory stimulation have an effect? *Pain Physician* 2007; 10:473–8
9. Vallejo R, Kramer J, Benyamin R: Neuromodulation of the cervical spinal cord in the treatment of chronic intractable neck and upper extremity pain: A case series and review of the literature. *Pain Physician* 2007; 10:305–11
10. Hagen JE, Bennett DS: Request for additional pertinent information regarding 4 extremity stimulation coverage from C2 spinal cord stimulation lead placement. *Pain Physician* 2007; 10:515–6
11. Hayek SM: Four extremity spinal cord stimulation using lower cervical epidural octapolar neuroelectrodes (abstract). *ANESTHESIOLOGY* 2006; 105:A1577
12. Tait RC, Pollard CA, Margolis RB, Duckro PN, Krause SJ: The Pain Disability Index: Psychometric and validity data. *Arch Phys Med Rehabil* 1987; 68:438–41
13. Litvan I, Goetz CG, Jankovic J, Wenning GK, Booth V, Bartko JJ, McKee A, Jellinger K, Lai EC, Brandel JP, Verny M, Chaudhuri KR, Pearce RK, Agid Y: What is the accuracy of the clinical diagnosis of multiple system atrophy? A clinicopathologic study. *Arch Neurol* 1997; 54:937–44
14. Wenning GK, Colosimo C, Geser F, Poewe W: Multiple system atrophy. *Lancet Neurol* 2004; 3:93–103
15. Barolat G, Massaro F, He J, Zeme S, Ketcik B: Mapping of sensory responses to epidural stimulation of the intraspinal neural structures in man. *J Neurosurg* 1993; 78:233–9
16. Hagen JE, Bennett DS: Successful treatment of 4-extremity complex regional pain syndrome type 1 with dual octapolar percutaneous leads and closely spaced electrodes. Poster presented at: 7th Congress of the International Neuromodulation Society, Rome, Italy, June 13, 2005
17. Smith MC, Deacon P: Topographical anatomy of the posterior columns of the spinal cord in man: The long ascending fibres. *Brain* 1984; 107:671–98
18. Nathan PW, Smith MC, Deacon P: The corticospinal tracts in man: Course and location of fibres at different segmental levels. *Brain* 1990; 113:303–24
19. Feirabend HK, Choufoer H, Ploeger S, Holsheimer J, van Gool JD: Morphometry of human superficial dorsal and dorsolateral column fibres: Significance to spinal cord stimulation. *Brain* 2002; 125:1137–49
20. Whitsel BL, Petrucelli LM, Sapiro G, Ha H: Fiber sorting in the fasciculus gracilis of squirrel monkeys. *Exp Neurol* 1970; 29:227–42