

Electrocardiographic ST-segment Depression: Confirm, Deny, or Artifact?

To the Editor:—We read the excellent article by Patel and Souter¹ regarding equipment-related electrocardiographic artifacts. We wish to remind readers of ANESTHESIOLOGY that the electrocardiographic monitor itself can also introduce artifacts, e.g., ST-segment depression, in the example described below and documented in figure 1.

An asymptomatic 86-yr-old man was scheduled to undergo cataract extraction during monitored anesthesia care. Upon starting electrocardiographic monitoring, an approximately 2.0-mm ST-segment depression was noted (Philips Component Monitoring System, software version C.1; Bothell, WA). A strip chart recording “confirmed” the ST-segment depression (top trace, fig. 1). However, the patient denied chest pain and was asymptomatic; therefore, an artifact was suspected. Upon investigation, the electrocardiographic monitor was found to be set in filter mode. In diagnostic mode, there was no significant ST-segment depression (bottom trace, fig. 1).

Low-frequency filtering can stabilize baseline drift but can also distort ST segments.² A frequency response of 0.5–40 Hz is considered adequate for routine monitoring, but a frequency response of 0.05–100 Hz is needed for true diagnostic electrocardiographic interpretation.³ The Philips filter mode has a 0.5-Hz filter cutoff, and the diagnostic mode uses a 0.05-Hz filter cutoff (personal verbal communication, John J. Wang, M.S., Principal Scientist, Philips Healthcare, Andover, MA, December 2005). The effect of the different electrocardiograph modes on baseline drift can also be seen in figure 1.

One clue that an apparent ST-segment depression may be an artifact is if a properly adjusted ST-segment analyzer displays a value inconsistent with the electrocardiographic trace. This is because the ST-segment module analyzes the less filtered diagnostic mode electrocardiograph; it can still be accurate even if the electrocardiographic monitor is set to filter mode (personal verbal communication, John J. Wang, M.S., December 2005).

In Reply:—We thank Dr. Wong for his kind comments and interest in our article¹ and were interested to read the details of his case. We agree that the low-pass filter attenuates high-frequency components of the electrocardiograph (such as sharp R waves) and a high-pass filter can cause ST-segment distortion.² We would also offer the observation that filters used within the monitor may cause artifactual ST-segment elevation, simulating infarction, as well as mimicking depression.³

However, we would also not want to create a false sense of assurance, and would advocate that such ischemic changes should be taken seriously on the first instance, even in asymptomatic patients. The incidence of silent ischemia is sufficiently high, particularly in diabetic patients, to create appropriate concern in circumstances of observed ST-segment changes.

However, we suggest that simple measures such as looking for confirmatory changes in other leads, checking electrode placement, and confirming the appropriate mode on the monitor should be undertaken before initiating any drastic diagnostic or therapeutic interventions. This is analogous to the logic of auscultatory confirmation of rate change, as suggested by Dr. Wong.

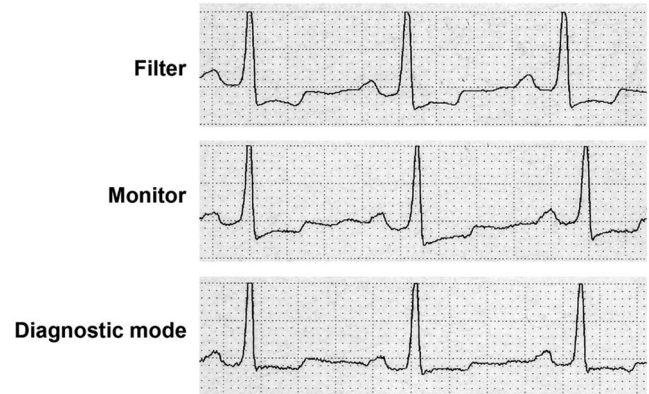


Fig. 1. Electrocardiograms of same patient in different electrocardiographic monitor modes. Each trace was obtained approximately 1 min apart.

David H. Wong, Pharm.D., M.D., Long Beach Veterans Affairs Medical Center, Long Beach, California, and University of California at Irvine, Orange, California. david.wong@med.va.gov

References

1. Patel SI, Souter MJ: Equipment-related electrocardiographic artifacts. ANESTHESIOLOGY 2008; 108:138–48
2. Leung JM, Voskanian A, Bellow WH, Pastor D: Automated electrocardiograph ST segment trending monitors: Accuracy in detecting myocardial ischemia. Anesth Analg 1998; 87:4–10
3. Weinfurt PT: Electrocardiographic monitoring: An overview. J Clin Monit 1990; 6:132–8

(Accepted for publication April 21, 2008.)

We would also point out that monitors may differ in their sensitivity and specificity for detecting and displaying ST-segment changes, and within the same monitor, the difference between computerized on-line analysis and printout may be significant.⁴

Santosh I. Patel, M.D., F.R.C.A.,* Michael J. Souter, M.B., Ch.B., F.R.C.A. *Trafford General Hospital, Urmston, Manchester, United Kingdom. santpatel@gmail.com

References

1. Patel SI, Souter MJ: Equipment-related electrocardiographic artifacts. ANESTHESIOLOGY 2008; 108:138–48
2. Gregg RE, Zhou SH, Lindauer JM, Helfenbein ED, Giuliano KK: What is inside the electrocardiograph? J Electrocardiol 2008; 41:8–14
3. Burri H, Sunthron H, Shah D: Simulation of anteroseptal myocardial infarction by electrocardiographic filters. J Electrocardiol 2006; 39:253–8
4. Yang H: Intraoperative automated ST segment analysis: A reliable black box? Can J Anaesth 1996; 43:1041–51

(Accepted for publication April 21, 2008.)