

Chronic Back Pain Secondary to a Calcified Epidural Blood Patch

Dafna Willner, M.D.,* Charles Weissman, M.D.,† Micha Y. Shamir, M.D.*

EPIDURAL blood patch (EBP) is a commonly performed procedure to alleviate post-dural puncture headache (PDPH). Although very effective, EBP is not free of serious complications. This case is the first report of an EBP that, rather than being absorbed, organized to form a chronic spinal epidural hematoma (SEH), resulting in radicular symptoms. Furthermore, this is also the first report of an SEH undergoing ossification, a phenomenon known to occur with cranial epidural hematomas.

Case Report

A 39-yr-old, healthy woman, G5P4Ab0LC4, was admitted to the delivery room of another hospital in active labor at term. During her previous three deliveries, she received epidural analgesia without any difficulty or complications. The patient had no history of back pain or migraine headaches. In the lateral decubitus position, a 20-gauge epidural catheter was inserted through an 18-gauge Tuohy needle. During insertion of the epidural needle, the patient felt a distinct sensation of membrane puncture followed by a postural headache and tinnitus, without nausea or vomiting. No paresthesia or pain was present upon catheter insertion. The patient received a test dose of local anesthetic, yielding almost immediate loss of sensation to spinal dermatome level T4, with motor paralysis and shortness of breath. The catheter was left in the subarachnoid space, and the patient delivered a healthy baby within the hour. The headache was treated with analgesics and hydration, with partial alleviation of symptoms. On the first postdelivery day, the catheter was removed and the patient was discharged to her home. She returned the following day to the emergency room because of exacerbation of symptoms. The patient did not have fever or focal neurologic deficits. A diagnosis of PDPH was made, and an EBP was performed. In the sitting position, at the L3-L4 intervertebral space, the epidural space was located, and autologous blood was injected *via* a Tuohy needle until substantial back pressure was felt (total 20 ml). The headache and tinnitus subsided, and the patient was released to her home after a few hours.

During the next few hours, the pressure in the patient's back had changed to radicular back pain. The severity of the radicular symptoms worsened over 2-3 days and reached its maximal magnitude as a severe (visual analog scale score of 8), incapacitating, burning/stabbing pain in her back, radiating to her right leg. Her general physician prescribed analgesics, traditional physiotherapy, chiropractic therapy, Alexander training, and acupuncture, without improvement. Only a year after delivery was she referred for an orthopedic consultation at our hospi-

tal. The orthopedic surgeon referred her for magnetic resonance imaging, which demonstrated a 1.3-cm round lesion compressing the spinal nerve roots at the right neural foramina of L3-L4 and L4-L5 (fig. 1). Surgical exploration during general anesthesia revealed an ossifying organized epidural hematoma at L3-L5. This finding coincided with the anatomical location at which the EBP was performed. Microscopically, the tissue was composed of young bone and osteoid, many osteoblasts and osteoclasts, and vascular stroma. Microbiologic study showed numerous erythrocytes with few polymorphonuclear cells on Gram stain. There was no bacterial growth. Sixty-day patient follow-up showed full recovery.

Discussion

Post-dural puncture headache, first reported in 1898, is a complication of dural puncture during neuroaxial anesthesia or diagnostic lumbar puncture. The incidence after spinal anesthesia is 0.2-24% and up to 30% after lumbar puncture.¹ Incidence increases with needle diameter and differs with needle design.² The typical presentation is of a fronto-occipital headache accompanied by nausea, dizziness, and/or visual disturbances. Typically, the symptoms are exacerbated in the upright position and are relieved when the patient lies down.³ In 90% of cases, symptoms resolve spontaneously within 10 days. Initial treatment is conservative, including non-steroidal antiinflammatory drugs, paracetamol, and bed rest.² Two causal hypotheses exist to explain PDPH: (1) downward traction of intracranial structures secondary to cerebrospinal fluid (CSF) leakage through a hole in the dura and (2) the Monroe-Kellie hypothesis: the sum of volumes of the brain, CSF, and intracranial blood is constant.⁴ Therefore, venodilation compensates for the decrease in CSF volume and causes migraine-like headaches.

In the case of a severe headache unresponsive to conservative therapy, an EBP is recommended. First introduced in 1960 by Gormley, an EBP is the accepted standard treatment of PDPH, carrying 70-98% success rate when conservative treatment fails.^{1,5} Blood is injected into the epidural space at the same level as the dural puncture until the patient reports pressure or worsening headache or 15-20 ml has been injected.⁶ Epidural blood increases the CSF pressure by forming a mass effect and stimulates cerebral vasoconstriction. At the same time, a fibrin clot is formed and seals the dural rent, allowing CSF volume to normalize. This generally results in an immediate improvement in symptoms. Magnetic resonance imaging studies confirmed that the mass effect of an EBP resolves over 7 h.⁶⁻⁷ It is therefore generally accepted that the injection of blood to the

* Attending Anesthesiologist and Clinical Instructor of Anesthesiology, † Professor of Anesthesiology, Professor of Internal Medicine, and Chairman, Department of Anesthesia and Critical Care Medicine.

Received from the Department of Anesthesia and Critical Care Medicine, Hadassah-Hebrew University Medical Center, Jerusalem, Israel. Submitted for publication September 20, 2007. Accepted for publication November 8, 2007. Support was provided solely from institutional and/or departmental sources.

Address correspondence to Dr. Shamir: Department of Anesthesia and Critical Care Medicine, Hadassah-Hebrew University Medical Center, P.O. Box 12000, Jerusalem 91120, Israel. shamir61@gmail.com. Information on purchasing reprints may be found at www.anesthesiology.org or on the masthead page at the beginning of this issue. ANESTHESIOLOGY's articles are made freely accessible to all readers, for personal use only, 6 months from the cover date of the issue.

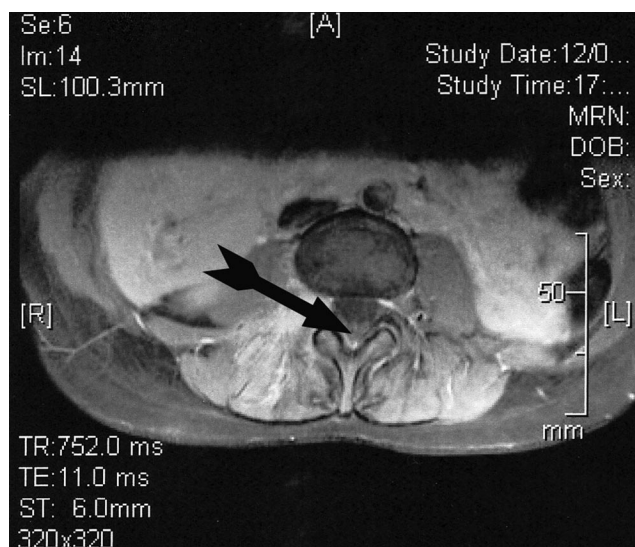


Fig. 1. Transverse view spinal magnetic resonance image. Arrow points to a 1.3-cm rounded epidural lesion at the right neural foramen of L3-L4 with enhancement of the paraspinal muscles posteriorly and the right pedicle of L3-L4.

epidural space does not result in an iatrogenic epidural hematoma.

Complications of the procedure are few, generally mild and transient. The most common complication of EBP is immediate or late back pain.⁸ In a long-term follow-up study, 35% of patients reported back pain that subsided within 48 h.⁹ This may result from the leakage of blood into the intervertebral ligaments and subcutaneous fat.⁷ Rare complications include lower back pain with radicular pain, spinal subdural hematoma, spinal subdural epiarachnoid hematoma (complication of a novel technique involving intentional puncture of the dura), intrathecal hematoma and arachnoiditis, and two cases of neurologic deterioration after EBP to patients with increased intracranial pressure.¹⁰⁻¹⁵

Spinal epidural hematoma is an uncommon entity. Forty percent to 50% of reported cases of SEH are spontaneous, without any identifiable cause. Traumatic SEH is less common than spontaneous lesions, and causes include vertebral fractures, obstetric birth trauma, lumbar punctures, postsurgical bleeding, missile injuries, and epidural anesthesia.¹⁶ To our knowledge, this is the first reported case of an EBP that organized to form a solid spinal epidural mass that caused *chronic* radicular symptoms.

Ossified and/or calcified cranial epidural hematomas have been reported as isolated cases in the literature.¹⁷ Nevertheless, they were all cranial. There are no reported cases in the literature of an SEH that ossified. Therefore, the patient described here is the first report of an SEH that underwent ossification causing neurologic symptoms. Calcification might develop as early as 4 weeks after a traumatic cranial epidural hematoma and is believed to begin on the dural aspect of the hematoma.

It is hypothesized that because the dura originates from the endosteum, it actively evokes extradural ossification of the adjacent hematoma.^{18,19} Another theory is that damaged vascularized tissues such as bone and dura provoke and initiate tissue responses such as inflammation, repair, and remodeling, resulting in osseous transformation. The development of radicular symptoms might be indirect evidence to a local inflammatory process that also contributed to the ossification. The natural sequence of healing is more rapid in children than in adults and might explain the fact that there are more reports of ossified cranial epidural hematomas in children.¹⁷

In the current case, the blood of a mother soon after giving birth was injected into the epidural space. One can thus speculate that this blood, still containing fetal cells, implanted stem cells and/or growth factors in the epidural space. There are clues that umbilical cord blood might contain nonhematopoietic stem cells. At least one study isolated fibroblast-like cells with osteogenic potential in the human umbilical cord blood.²⁰ Perhaps such cells initiated ossification of the maternal blood in the epidural space rather than being absorbed.

There is no question that EBP, a common procedure with few reported complications, is the treatment of choice for severe PDPH when conservative therapy fails. However, this case should remind anesthesiologists that EBP is an invasive procedure with the potential for morbidity. The development of persistent and progressive back pain or neurologic symptoms in patients after EBP should alert general practitioners and clinicians, because immediate orthopedic investigation of these symptoms may prevent permanent problems.

References

1. Turnbull DK, Shepherd DB: Post-dural puncture headache: pathogenesis, prevention and treatment. *Br J Anaesth* 2003; 91:718-29
2. Gaiser R: Postdural puncture headache. *Curr Opin Anaesthesiol* 2006; 19:249-53
3. Evans RW, Armon C, Frohman EM, Goodin DS: Assessment: prevention of post-lumbar puncture headaches: Report of the therapeutics and technology assessment subcommittee of the American Academy of Neurology. *Neurology* 2000; 55:909-14
4. Grant R, Condon B, Hart I, Teasdale GM: Changes in intracranial CSF volume after lumbar puncture and their relationship to post-LP headache. *J Neurol Neurosurg Psychiatry* 1991; 54:440-2
5. Gormley JB: Treatment of post-spinal headache. *ANESTHESIOLOGY* 1960; 21: 565-6
6. Crawford JS: Experiences with epidural blood patch. *Anaesthesia* 1980; 35:513-5
7. Beards SC, Jackson A, Griffiths EL, Horsman L: Magnetic resonance imaging of extradural blood patches: Appearance from 30 min to 18 h. *Br J Anaesth* 1993; 71:182-8
8. Paech M: Epidural blood patch: Myths and legends. *Can J Anesth* 2005; 52:R12
9. Abouleish E, Vega S, Blendinger I, Tio TO: Long-term follow-up of epidural blood patch. *Anesth Analg* 1975; 54:459-63
10. Cornwall RD, Dolan WM: Case history: Complications following epidural "blood patch" for postlumbar-puncture headache. *Anesth Analg* 1973; 52:67-72
11. Tekkok IH, Carter DA, Brinker R: Spinal subdural haematoma as a complication of immediate epidural blood patch. *Can J Anesth* 1996; 43: 306-9
12. Reynolds AF, Hameroff SR, Blitt CD, Roberts WL: Spinal subdural epiarach-

noid hematoma: A complication of a novel epidural blood patch technique. *Anesth Analg* 1980; 59:702-3

13. Aldrete JA, Brown TL: Intrathecal hematoma and arachnoiditis after prophylactic blood patch through a catheter. *Anesth Analg* 1997; 84:233-4

14. Sperry RJ, Gartrell A, Johnson JO: Epidural blood patch can cause acute neurologic deterioration. *ANESTHESIOLOGY* 1995; 82:303-5

15. Beers RA, Cambareri JJ, Rodziewicz GS: Acute deterioration of mental status following epidural blood patch. *Anesth Analg* 1993; 76:1147-9

16. Hsieh CT, Chiang YH, Tang CT, Sun JM, Ju DT: Delayed traumatic thoracic spinal epidural hematoma: A case report and literature review. *Am J Emerg Med* 2007; 25:69-71

17. Erdogan B, Sen O, Bal N, Cekinmez M, Altinors N: Rapidly calcifying and ossifying epidural hematoma. *Pediatr Neurosurg* 2003; 39:208-11

18. Sillero RO, Zanini MA, Gabarra RC: Large chronic epidural hematoma with calcification: A case report [published on-line ahead of print June 1, 2007]. *J Trauma* 2007

19. Nagane M, Oyama H, Shibui S, Nomura K, Nakanishi Y, Kamiya M: Ossified and calcified epidural hematoma incidentally found 40 years after head injury: Case report. *Surg Neurol* 1994; 42:65-9

20. Rosada C, Junstesen C, Melsvik D, Ebbesen P, Kassem M: The human umbilical cord blood: A potential source for osteoblast progenitor cells. *Calcif Tissue Int* 2003; 72:135-42