

Lumbosacral Epiduroscopy Complicated by Intravascular Injection

James E. Heavner, D.V.M., Ph.D.,* David E. Wyatt, B.S.,† Hemmo A. Bosscher, M.D.‡

INTRAVASCULAR injection, either intraarterial or intravenous, is an undesired event that can occur during attempted epidural injections through needles and catheters. When it occurs, it is attributed to entry of the needle or catheter into a blood vessel. There are no reports in the literature of this being observed during epiduroscopy. We report two cases of intravascular appearance of radiopaque contrast material on fluoroscopy during injection through the working channel of an epiduroscope that we believe cannot be explained by entry of the epiduroscope tip into an epidural blood vessel. No previous reports of intravascular injections during epiduroscopy were found.

Lumbosacral epiduroscopy is a relatively new technique used in the diagnosis and treatment of low back pain and/or radiculopathy involving the lower extremities. All available epiduroscopes transmit light to illuminate the epidural space and transmit images from the space back to an observer. Other features include a working channel through which saline, radiopaque contrast material, and drugs can be injected and instruments can be introduced, and a mechanism for steering the tip of the epiduroscope. The round tip of the flexible epiduroscope used for the cases reported here (Storz Epiduroscope, Karl Storz, Tuttlingen, Germany) is 2.8 mm in diameter, and the end is flat. The end has a 1-mm opening for the working channel plus a lens for light delivery and one for transmission of optical images. Epiduroscopes usually are inserted *via* access established through the sacral hiatus and advanced cephalad to areas of interest (usually not beyond L2). Fluoroscopy is used intermittently during epiduroscopy. Saline is infused to expand the epidural space and wash away extravascular blood and tissue debris to facilitate visual inspection. After a site of pathology is found and examined, treatment is begun, which usually consists of hyaluronidase injection and application of hydrostatic and/or mechanical forces to remove barriers to fluid flow, and local anesthetic and corticosteroid injection. Before and during treatment, radiopaque contrast material usually is

injected to confirm that injected fluids (1) do not go intravascular and (2) distribute as intended in the epidural space and/or through a targeted intervertebral foramen.

Case Reports

Case 1

A 73-yr-old man with a history of spinal fusion of the fourth and fifth lumbar and first sacral vertebrae presented with back pain located primarily over the lumbar region, with radiation to the left posterior thigh and calf, and left and right foot. The pain was described as constant, dull, and aching. In addition to the lumbosacral vertebral fusion 8 yr before presentation, the patient underwent fusion of the fifth, sixth, and seventh cervical vertebrae 1 yr before presentation. Other medical history included prostatic cancer, for which a transurethral prostatectomy was performed, and residual neoplastic disease in the bladder and metastasis to the right kidney, for which excision of the tumor in the bladder and a right nephrectomy were performed, respectively. The patient also had a cholecystectomy.

Physical examination was unremarkable, with the exception of bilateral sensory deficits over the S1 distribution of the lower extremities. No pain on palpation was elicited, and range of motion in the lower extremities was full. Bilateral leg raise, bilateral Kemp testing, and bilateral Fabere testing were negative. Magnetic resonance images of the lumbar spine from the previous year showed postlaminectomy changes with collapse of the disc space height at L3-L4 and L4-L5, with foraminal compromise noted in the latter region. Failed back surgery syndrome was diagnosed, and the patient was scheduled to undergo epiduroscopy.

Epidural access was established *via* the sacral hiatus, and the epiduroscope was passed cephalad through the posterior epidural space aided by fluoroscopy. Dense fibrosis throughout the lumbosacral region displaced epidural fat, and there was proliferation of blood vessels (fig. 1A). The epiduroscope was advanced through scar tissue to the cephalad border of L4, to the right of the midline (fig. 1B). No blood vessels with a diameter as large as the epiduroscope tip were seen, nor was an intravascular view observed *via* the epiduroscope. Radiopaque contrast (iohexol 240, 5 ml) was injected through the working channel of the epiduroscope during continuous anteroposterior fluoroscopy. During injection, contrast immediately appeared intravascularly, flowing in an oblique lateral and caudal direction beginning at the L3-L4 interspace and then caudally, parallel to the spine (fig. 1C). It flowed through the right fourth lumbar vein to the ascending lumbar vein into the common iliac vein. The contrast in the veins completely disappeared within 3 s. The epiduroscope was repositioned caudally (approximately 5 mm), and contrast injection was repeated; none appeared intravascularly. We proceeded with the injection of 1,500 U hyaluronidase; 5 ml ropivacaine, 0.2%; and 80 mg methylprednisolone. Then the epiduroscope was removed. The patient was stable during and after the procedure, and no complications from the injections were noted.

Case 2

A 51-yr-old man with a history of three-level lumbosacral fusion (L4-L5-S1) presented with the chief symptom of worsening low back

* Professor, Departments of Anesthesiology and Physiology, ‡ Clinical Assistant Professor, Department of Anesthesiology, † Fourth-year Medical Student, Texas Tech University School of Medicine.

Received from the Department of Anesthesiology, Texas Tech University School of Medicine, Lubbock, Texas. Submitted for publication February 9, 2007. Accepted for publication March 15, 2007. Support was provided solely from institutional and/or departmental sources.

Address correspondence to Dr. Heavner: Anesthesiology, 3601 4th Street, Lubbock, Texas 79430. james.heavner@ttuhsc.edu. Information on purchasing reprints may be found at www.anesthesiology.org or on the masthead page at the beginning of this issue. ANESTHESIOLOGY's articles are made freely accessible to all readers, for personal use only, 6 months from the cover date of the issue.

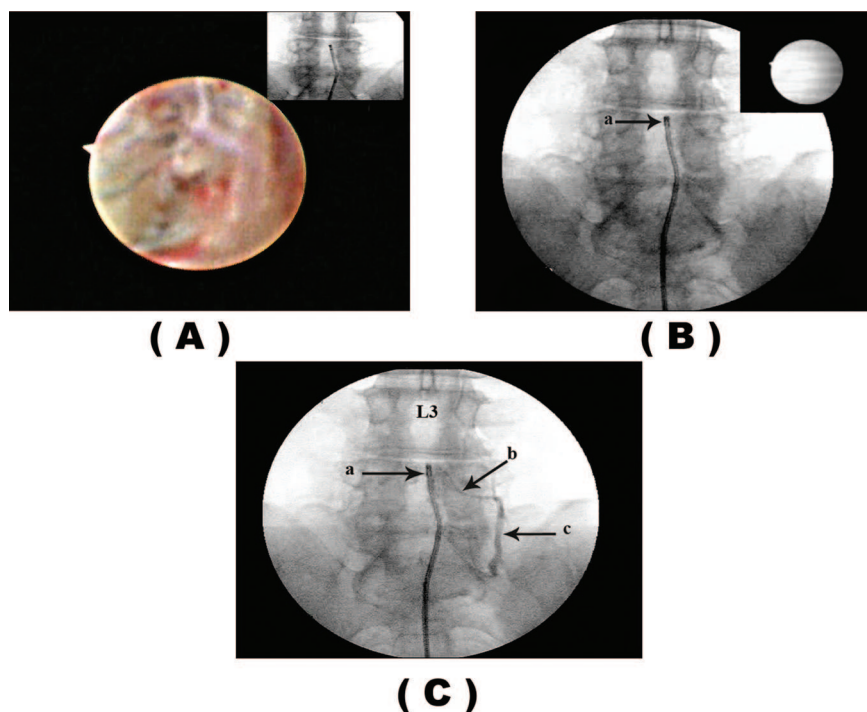


Fig. 1. An epiduroscopic view is the primary image and a fluoroscopic view is the secondary (A) or *vice versa* (B). Only the fluoroscopic view is shown in C. (A) Epiduroscopic view of the injection site. There is a preponderance of dense fibrous tissue infiltrated with blood vessels. (B) Just before iohexol injection. Epiduroscope tip (a) is just at the cephalad border of L4, to the right of midline. (C) Fluoroscopic view during iohexol injection through the working channel of the epiduroscope. The contrast spread from the injection site (a) into the fourth lumbar vein (b) and the ascending lumbar vein (c).

pain. He stated that his pain began after back surgery approximately 8 yr before presentation. The pain gradually increased during this interval and was now located over his lower lumbar region with bilateral radiation to his posterolateral thighs, calves, and feet. The pain was described as sharp and aching, with 9/10 intensity. He also reported bilateral lower extremity weakness. The patient reported no previous medical or surgical history other than his lumbar fusion. Physical examination was unremarkable except for pain elicitation upon palpation over the posterior region of the third and fourth lumbar vertebrae. Bilateral straight leg raise and bilateral Kemp tests were positive. Sensory modalities, muscular strength, and range of motion tests were all within normal limits. Magnetic resonance images of the lumbar spine revealed evidence of degenerative disc disease, with central disc

herniation at L3–L4 and facet arthropathy, with secondary mild spinal stenosis. A diagnosis of failed back surgery was made, and the patient was scheduled to undergo epiduroscopy.

Access to the epidural space was obtained *via* the sacral hiatus, and the epiduroscope was passed cephalad through the posterior epidural space with fluoroscopic assistance. Epiduroscopic visualization revealed bilateral moderate to severe fibrosis at L4–L5. Epidural fat was normal except for areas of displacement by fibrosis (fig. 2A). Increased vascularity was noted. The epiduroscope was advanced through scar tissue to L4–L5, and the tip was positioned near the right L4–L5 intervertebral foramen (fig. 2B). No blood vessels with a diameter as large as the epiduroscope tip were seen, nor was an intravascular view observed *via* the epiduroscope. During injection of iohexol 240 (8 ml)

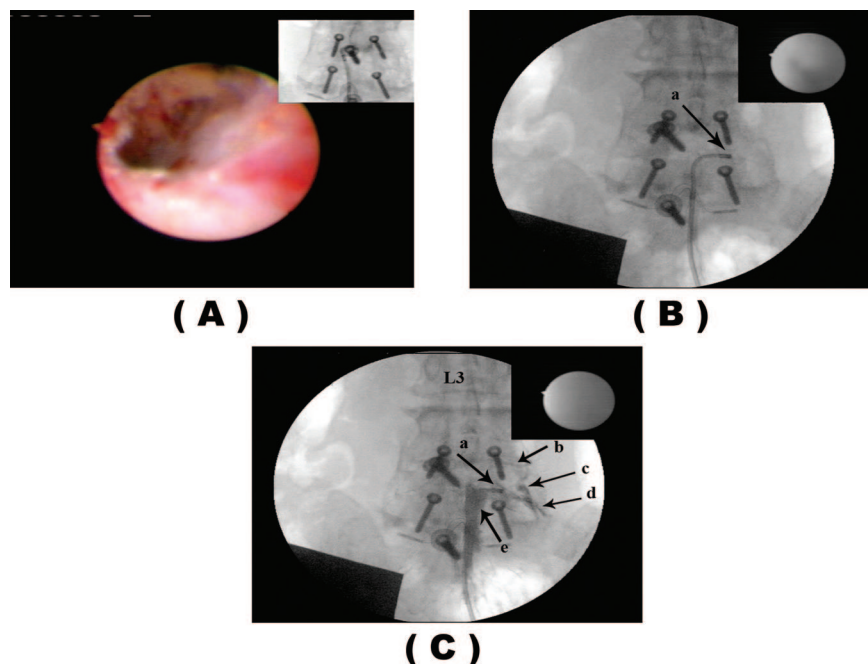


Fig. 2. An epiduroscopic view is the primary image and a fibroscopic view is the secondary image (A) or *vice versa* (B and C). (A) Epiduroscopic view of the epidural space in the vicinity of the injection site. Dense fibrous tissue infiltrated with blood vessels and some extravascular blood are seen. The tunnel was made by passage of the epiduroscope. (B) Just before iohexol injection. The tip of the epiduroscope (a) is at the entry of the right L4–L5 intervertebral foramen. (C) During iohexol injection. Contrast spread from the injection site (a) into the fourth lumbar vein (b) and the ascending lumbar vein (c), along the L4 nerve (d) and into the ipsilateral epidural space (e).

through the working channel of the epiduroscope, immediate spread of contrast into the ipsilateral epidural space and through the right L4–L5 intervertebral foramen along the L4 nerve as well as vascular entry (fig. 2C) was observed on fluoroscopy. Contrast was observed flowing from the right fourth lumbar vein into the ascending lumbar vein, where it flowed both caudad and cephalad. The contrast in the veins disappeared within approximately 3 s. The tip of the epiduroscope was withdrawn approximately 5 mm, and contrast was injected again. None of the contrast appeared intravascular. Hyaluronidase (1,500 U) and then 10 ml ropivacaine, 0.2%, and 80 mg methylprednisolone were injected, and the epiduroscope was removed. The patient was stable during the procedure and afterward. No adverse reactions were noted.

Discussion

These cases raise two critical questions: (1) Did the contrast enter the venous system or the arterial or lymphatic system? (2) How did the contrast get intravascular?

We believe the contrast entered the venous system. Evidence for this is the observed direction, speed, and path of flow. The flow was away from the epidural space following anatomically defined venous drainage of the space.¹ If the entry was into the arterial system, flow would have been directed centrally into smaller vessels, not peripherally into larger vessels. The rate of contrast washout was much more rapid than would have occurred if the contrast had entered the lymph system.

The most likely explanation for intravascular entry of contrast material in the two cases reported here is that (1) the wall of a vein was torn, (2) the opening was kept patent by fibrous attachments to the vessel wall, and (3) low resistance alternatives to intravenous flow were inaccessible because the vessel was embedded in dense fibrous tissue. Requirements for venous entry to occur include a portal for entry and a favorable pressure gradient. Route of flow is determined by the relative resistance of available pathways to flow. In our cases, pressure driving fluid flow was supplied by a thumb pressing the plunger of a 10-ml syringe containing radiopaque contrast. Contrast injected in this way usually disperses within the epidural space, producing an epidurogram. As demonstrated by Hogan² in fresh cadavers, fluid injected epidurally does not distribute uniformly. We believe that in our cases, changes secondary to underlying disease and changes secondary to surgery, *i.e.*, dense fibrosis infiltrated with blood vessels, obliterated pathways with lower resistance to flow than offered by the vessels, or changed relative resistances. Repositioning the tip of the epiduroscope directed contrast to a route with lower resistance than the vascular route. We are accustomed to observing changes in contrast distribution after small changes in the position of the epiduroscope tip.

Numerous studies have described how pressure in the

epidural space increases as fluid is infused. Pressures well above venous pressure can easily be achieved, depending on volume injected, rate of injection, rate of fluid exit from the space, and compliance of the epidural space. If the pressure gradient between outside and inside the vein exceeds a critical amount, the vein will collapse, and no flow occurs in the vein.

Normally, radiopaque material does not cross the walls of blood vessels, and thus, in our case, the most probable route of intravascular entry was through a tear in a vein. We often observe torn vessels and extravascular blood when we do epiduroscopy. Usually, however, contrast does not enter the vessels because alternative lower resistance pathways are available. Routes with lower resistance to flow obviously were not present in the vicinity of the epiduroscope tip in our first case and were only partially available in case 2 (partial spread into the epidural space and through the neuroforamen).

Jaffe *et al.*³ also reported evidence that substances intended for epidural placement can go intravascular instead. They detected the presence of venous microbubble emboli in the systemic circulation within 15 s after epidural air injection. This occurred despite measures taken to ensure that the catheter through which the air was injected was not placed intravascularly.³ Simultaneous epidural and intravascular entry of radiopaque contrast material, as observed in our second case, has been reported previously by Smuck *et al.*⁴ They observed that simultaneous entry is twice as likely to occur as is intravascular injection alone during transforaminal lumbosacral epidural injections.

To minimize the risk of complications due to epidural hemorrhage during epiduroscopy, we follow the American Society of Regional Anesthesia and Pain Medicine Guidelines for Neuraxial Procedures.⁵ We also view the epiduroscopic image during manipulation of the epiduroscope and avoid contact with blood vessels if possible. Nevertheless, some vessels may be damaged, as we believe happened in the cases we report. To our knowledge, no complications due to epidural hemorrhage related to epiduroscopy have been reported.

The risks associated with intraarterial and intravenous injections during attempted epidural injections are well known. We minimize the risk by (1) always injecting radiopaque contrast material under fluoroscopic observation to detect intravascular entry before injecting other fluids and (2) avoiding blood vessels by continuously observing the epiduroscopic view. We have not knowingly entered an epidural vessel. We rely on our knowledge of the endoscopic appearance of the inside of vessels in other locations as a reference to identify epidural vessel entry should it occur during epiduroscopy. Based on the configuration and size of the tip of the epiduroscope we use relative to the size of blood vessels we encounter, we

believe it is unlikely that a blood vessel would be entered during epiduroscopy.

We conclude that direct vascular entry of substances during attempted epidural injections can occur without the delivery device (needle, catheter, epiduroscope) in the vessel.

The authors thank Erin Haley, Adam Ross (Student Assistants, Department of Anesthesiology, Texas Tech University School of Medicine, Lubbock, Texas), and Mark Welborn, B.A. (Unit Coordinator, Classroom Support, Texas Tech University Health Sciences Center), for technical assistance in the preparation of the manuscript.

Anesthesiology 2007; 107:350–3

Copyright © 2007, the American Society of Anesthesiologists, Inc. Lippincott Williams & Wilkins, Inc.

Delayed Onset of Malignant Hyperthermia without Creatine Kinase Elevation in a Geriatric, Ryanodine Receptor Type 1 Gene Compound Heterozygous Patient

Jordan L. Newmark, M.S.-IV,* Maria Voelkel, B.A.,† Barbara W. Brandom, M.D.,‡ John Wu, Ph.D.§

MALIGNANT hyperthermia (MH) is a dominantly inherited pharmacogenetic disorder of skeletal muscle that predisposes individuals to a potentially fatal reaction (a fulminant episode) on exposure to volatile anesthetics and/or succinylcholine.¹ Fulminant MH episodes apparently result from a rapid, sustained increase in myoplasmic calcium (Ca^{2+}). Molecular genetic analysis has identified mutations in the ryanodine receptor type 1 gene (*RYR1*) that codes for the Ca^{2+} release channel in muscle sarcoplasmic reticulum in many MH-susceptible people. Mutations in *RYR1* are the most frequent genetic abnormality that has been associated with MH. However, the MH syndrome is known to be heterogeneous, and the clinical presentation of MH is highly variable. The hallmarks of a life-threatening MH episode are tachycardia, hypercarbia, acidosis, hyperkalemia, muscle rigidity, hyperthermia, and rhabdomyolysis.² Muscle membrane damage leads to release of intracellular muscle constituents such as myoglobin, potassium, creatine kinase (CK), and lactate dehydrogenase into the blood. MH is often described in young patients, but we report a slow-onset intraoperative episode in a geriatric patient without an increase in CK. This episode was confirmed as MH by

References

1. Williams PL, Warwick R, Dyson M, Bannister LH: Gray's Anatomy, 36th edition. London, Churchill Livingstone, 1980, p 755
2. Hogan Q: Distribution of solution in the epidural space: examination by cryomicrotome section. *Reg Anesth Pain Med* 2002; 27:150–6
3. Jaffe RA, Siegel LC, Schnitger I, Porpst JW, Brock-Utne G: Epidural air injection assessed by transesophageal echocardiography. *Reg Anesth* 1995; 20:152–5
4. Smuck M, Fuller BJ, Yoder B, Huerta J: Incidence of simultaneous epidural and vascular injection during lumbosacral transforaminal epidural injections. *Spine J* 2007; 7:79–82
5. Horlocker TT, Wedel DJ, Benzon H, Brown DL, Enneking FK, Heit JA, Mulroy MF, Rosenquist RW, Rowlingson J, Tryba M, Yuan CS: Regional anesthesia in the anticoagulated patient: Defining the risks (the second ASRA Consensus Conference on Neuraxial Anesthesia and Anticoagulation). *Reg Anesth Pain Med* 2003; 28:172–97

the finding of two *RYR1* mutations known to be causative of this syndrome.

Case Report

A 73-yr-old, 70-kg man with American Society of Anesthesiologists physical status III presented for laparoscopic and open resection of a rectal tumor, colostomy, and lysis of adhesions. His medical history included hypertension, gastroesophageal reflux disease, osteoarthritis, deep vein thrombosis, and pulmonary embolism. The patient reported no serious complications associated with four intravenous general and three spinal anesthetics. He had never received volatile inhalational anesthetic agents. He reported frequent fevers without infection after surgery and annual influenza vaccinations, as well as delayed awakening from general anesthesia and painful muscle spasms after hip replacement.

Medications at time of surgery included diltiazem, lisinopril, metoprolol, famotidine, neomycin, erythromycin, and warfarin stopped 8 days previously and heparin stopped the night before surgery. The patient performed manual farm labor and reported no heat sensitivity, chronic muscle aches, pain, or weakness.

A preoperative family history obtained from the patient did not reveal anesthesia or surgical complications. He had five offspring, all of whom were healthy.

Before induction of anesthesia, standard monitors were applied: electrocardiogram (leads II and V5), noninvasive blood pressure cuff, and pulse oximeter. After induction of general anesthesia, capnography (ETCO_2), peripheral nerve stimulation, an esophageal temperature probe (T_{es}), and a Bispectral Index monitor were used. A BAIR Hugger (Arizant Healthcare, Eden Prairie, MN) delivered air at 43°C to the upper body and lower extremities of the patient.

Induction of anesthesia was achieved with 1 mg midazolam (0.014 mg/kg) and 100 mg propofol (1.4 mg/kg). Rocuronium, 50 mg (0.71 mg/kg), was given to facilitate tracheal intubation, accomplished without complication. Anesthesia continued with isoflurane (end-tidal 0.43–1.0 vol%) and intermittent doses of fentanyl, rocuronium, and hydromorphone. The patient's heart rate was controlled with metoprolol. Ventilation parameters included minute ventilation of 5.2 l/min, with tidal volume of 650 ml, respiratory rate of 8 breaths/min, and peak airway pressure of approximately 30 cm H_2O . Before surgical

* Medical Student, Temple University, Philadelphia, Pennsylvania. † Research Assistant, Department of Anesthesiology, § Assistant Professor, Department of Obstetrics and Gynecology, Uniformed Services University of the Health Sciences, Bethesda, Maryland. ‡ Professor, Department of Anesthesiology, University of Pittsburgh.

Received from the Department of Anesthesiology, University of Pittsburgh, Pittsburgh, Pennsylvania. Submitted for publication January 23, 2007. Accepted for publication April 9, 2007. Support was provided solely from institutional and/or departmental sources.

Address correspondence to Dr. Brandom: Children's Hospital of Pittsburgh, 3705 Fifth Avenue at DeSoto Street, Room 7446, Pittsburgh, Pennsylvania 15213. brandombw@anes.upmc.edu. Information on purchasing reprints may be found at www.anesthesiology.org or on the masthead page at the beginning of this issue. ANESTHESIOLOGY's articles are made freely accessible to all readers, for personal use only, 6 months from the cover date of the issue.