

Takotsubo Cardiomyopathy after General Anesthesia

To the Editor:—I enjoyed reading the case report about Takotsubo cardiomyopathy after general anesthesia by Gavish *et al.* in the September 2006 issue of ANESTHESIOLOGY.¹ It is noteworthy that another case report of postoperative Takotsubo-like left ventricular dysfunction that occurred in France was published in the same month in the September 2006 issue of *Anesthesia & Analgesia*² and was accompanied by an editorial that also emphasized the importance to anesthesiologists of this recently recognized form of transient reversible left ventricular dysfunction.³ It should be noted that there has been at least one previous case of postoperative transient apical ballooning syndrome in a white female reported by Ramakrishna *et al.*⁴

It is interesting to ponder why these case reports are appearing now. I suspect it relates to the old adage that “we only see what we look for.”

In Reply:—We thank Dr. Hessel for the important comments and his ability to quote another report, by Ramakrishna *et al.*,¹ of perioperative stress-induced apical ballooning (Takotsubo cardiomyopathy). The authors presented a case of a 35-yr-old woman who underwent hepatectomy and developed apical ballooning syndrome in the postoperative period.

The articles by Lentschener *et al.*² and Gavish *et al.*³ emphasize the role of the anesthesiologist in early diagnosis and treatment of the perioperative apical ballooning syndrome.

We agree with the old adage quoted by Dr. Hessel that “we only see what we look for” as an explanation for the fact that perioperative apical ballooning was reported only recently. Furthermore, as emphasized by the famous Irish dramatist, literary critic, and social spokesman George Bernard Shaw in 1906, ideas frequently recur in the history of medicine,⁴ with many of them being “reinvented” periodically. In fact, as we commented in our case report,³ a previous description of perioperative apical ballooning was published by Mizutani and Okada⁵ in the Japanese literature.

Supposedly, along their professional career, anesthesia practitioners might miss cases of apical ballooning or misinterpret them as myocardial ischemia. Therefore, we consider that the main message of our

Eugene A. Hessel II, M.D., University of Kentucky College of Medicine, Lexington, Kentucky. ehessel@uky.edu

References

1. Gavish D, Rozenman Y, Hafner R, Bartov E, Ezri T: Takotsubo cardiomyopathy after general anesthesia for eye surgery. ANESTHESIOLOGY 2006; 105:621-3
2. Lentschener C, Vignaux O, Spaulding C, Bonnichon P, Legmann P, Ozier Y: Early Postoperative *Tako-Tsubo*-like left ventricular dysfunction: Transient left ventricular apical ballooning syndrome. Anesth Analg 2006; 103:580-2
3. Hessel EA: The brain and the heart (editorial). Anesth Analg 2006; 103:522-6
4. Ramakrishna G, Ravi BS, Chandrasekaran K: Apical Ballooning syndrome in a postoperative patient with normal microvascular perfusion by myocardial contrast echocardiography. Echocardiography 2005; 22:606-10

(Accepted for publication January 17, 2007.)

 β -Blockade Abolishes Anesthetic Preconditioning: Impact on Clinical Applicability

To the Editor:—We read with interest the recent article by Dr. Lange *et al.*,¹ who reported that β -blockade with esmolol abolished the cardioprotective effect of anesthetic preconditioning with 1 minimum alveolar concentration sevoflurane or desflurane but not that elicited by ischemic preconditioning in a rabbit *in vivo* cardiac ischemia-reperfusion model. As interesting and important as these findings may be for the further elucidation of the signaling process involved in these powerful cardioprotective mechanisms, they certainly also add to the debate of whether anesthetic preconditioning will ever become a

case report is to enhance the readers' awareness about the potential for occurrence of Takotsubo syndrome in the perioperative period.

Tiberiu Ezri, M.D.,* Doron Gavish, M.D., Polina Klaiman, M.D., Michael Kriwisky, M.D., Yoseph Rozenman, M.D., Robert Hafner, M.D., Elisha Bartov, M.D. *Wolfson Medical Center, Holon, Israel. tezri@netvision.net.il

References

1. Ramakrishna G, Ravi BS, Chandrasekaran K: Apical ballooning syndrome in a postoperative patient with normal microvascular perfusion by myocardial contrast echocardiography. Echocardiography 2005; 22:606-10
2. Lentschener C, Vignaux O, Spaulding C, Bonnichon P, Legmann P, Ozier Y: Early postoperative *Tako-Tsubo*-like left ventricular dysfunction: Transient left ventricular apical ballooning syndrome. Anesth Analg 2006; 103:580-2
3. Gavish D, Rozenman Y, Hafner R, Bartov E, Ezri T: Takotsubo cardiomyopathy after general anesthesia for eye surgery. ANESTHESIOLOGY 2006; 105:621-3
4. Shaw GB: The doctor's dilemma: Act I.
5. Mizutani K, Okada M: A case of intraoperative repeated coronary artery spasm with ST-segment depression [in Japanese]. Masui 2002; 51:1114-6

(Accepted for publication January 17, 2007.)

science research³ and the much milder results in recent clinical studies.^{4,5} As such, we would be interested in how the authors interpret the relevance of their findings to the clinical practice of anesthesia.

Matthias L. Riess, M.D., Ph.D.,* David F. Stowe, M.D., Ph.D.
*Medical College of Wisconsin, Milwaukee, Wisconsin.
mriess@mcw.edu

References

1. Lange M, Smul TM, Blomeyer CA, Redel A, Klotz KN, Roewer N, Kehl F: Role of the β_1 -adrenergic pathway in anesthetic and ischemic preconditioning against myocardial infarction in the rabbit heart *in vivo*. *ANESTHESIOLOGY* 2006; 105:503-10
2. Riess ML, Stowe DF, Wartier DC: Cardiac pharmacological preconditioning

with volatile anesthetics: From bench to bedside? *Am J Physiol Heart Circ Physiol* 2004; 286:H1603-7

3. Bienengraeber MW, Weihrauch D, Kersten JR, Pagel PS, Wartier DC: Cardioprotection by volatile anesthetics. *Vasc Pharmacol* 2005; 42:243-52

4. Julier K, da Silva R, Garcia C, Bestmann L, Frascarolo P, Zollinger A, Chassot PG, Schmid ER, Turina MI, von Segesser LK, Pasch T, Spahn DR, Zaugg M: Preconditioning by sevoflurane decreases biochemical markers for myocardial and renal dysfunction in coronary artery bypass graft surgery: A double-blinded, placebo-controlled, multicenter study. *ANESTHESIOLOGY* 2003; 98:1315-27

5. De Hert SG, Van der Linden PJ, Cromheecke S, Meeus R, Nelis A, Van Reeth V, ten Broecke PW, De Blier IG, Stockman BA, Rodrigus IE: Cardioprotective properties of sevoflurane in patients undergoing coronary surgery with cardiopulmonary bypass are related to the modalities of its administration. *ANESTHESIOLOGY* 2004; 101:299-310

(Accepted for publication January 23, 2007.)

Anesthesiology 2007; 106:1062

Copyright © 2007, the American Society of Anesthesiologists, Inc. Lippincott Williams & Wilkins, Inc.

In Reply:—We thank Drs. Riess and Stowe for their interest in our study on β_1 -adrenergic signaling in anesthetic preconditioning¹ and for their question of how we would interpret the relevance of the experimental findings to clinical practice. Although results from experimental investigations should be interpreted with caution as to their clinical relevance, we do believe that β -blockers indeed might hamper beneficial effects of anesthetic preconditioning. Experimental data from our laboratory in addition demonstrate that the clinically widely used β_1 -selective blocker metoprolol dose-dependently abrogates desflurane-induced preconditioning.² A recent meta-analysis of clinical studies of cardioprotection by volatile anesthetics in coronary artery bypass graft surgery confirmed a sustained reduction of postoperative cardiac troponin I release in patients receiving volatile anesthetics.³ However, the results of this study do also suggest a possible interaction between β -blocker prophylaxis and anesthetic preconditioning. The use of β -blockers was disproportioned: Patients receiving volatile anesthetics had a 28% lower incidence of β -blocker use compared with patients receiving intravenous anesthetics. This leads us to the conjecture that no beneficial effects of volatile anesthetics would have been found had β -blocker use been equally distributed. Therefore, we share the concern of Drs. Riess and Stowe insofar as in clinical practice, apart from

constraints such as age, hyperglycemia, and diabetes,⁴ cardiovascular comedication might attenuate beneficial effects of volatile anesthetics.

Markus Lange, M.D., Andreas Redel, M.D., Norbert Roewer, M.D., Ph.D., Franz Kehl, M.D., Ph.D., D.E.A.A.* *Bayerische Julius-Maximilians-Universität, Würzburg, Germany. franz.kehl@mail.uni-wuerzburg.de

References

1. Lange M, Smul TM, Blomeyer CA, Redel A, Klotz KN, Roewer N, Kehl F: Role of the β_1 -adrenergic pathway in anesthetic and ischemic preconditioning against myocardial infarction in the rabbit heart *in vivo*. *ANESTHESIOLOGY* 2006; 105:503-10

2. Lange M, Smul T, Redel A, Roewer N, Kehl F: Coadministration of desflurane and metoprolol blocks anesthetic-induced preconditioning and cardioprotective effects of beta adrenergic blockade in the rabbit heart *in vivo* (abstract). *ANESTHESIOLOGY* 2005; 103:A469

3. Yu CH, Beattie WS: The effects of volatile anesthetics on cardiac ischemic complications and mortality in CABG: A meta-analysis. *Can J Anaesth* 2006; 53:906-18

4. Kehl F, Krolkowski JG, Mraovic B, Pagel PS, Wartier DC, Kersten JR: Hyperglycemia prevents isoflurane-induced preconditioning against myocardial infarction. *ANESTHESIOLOGY* 2002; 96:183-8

(Accepted for publication January 23, 2007.)

Anesthesiology 2007; 106:1062-3

Copyright © 2007, the American Society of Anesthesiologists, Inc. Lippincott Williams & Wilkins, Inc.

Ganglion Impar Injection Techniques for Coccydynia (Coccyx Pain) and Pelvic Pain

To the Editor:—I read with great interest the article by Ho *et al.*¹ titled “An Alternative Approach to Ganglion Impar Neurolysis under Computed Tomography Guidance for Recurrent Vulva Cancer.”

As the authors pointed out, there are a variety of approaches for injections of the ganglion impar (ganglion Walther), typically injected in the treatment of coccydynia and various pelvic pain syndromes. The authors described an “alternative” approach to the ganglion impar, initially for local anesthetic block and subsequently followed by neurolysis with 100% alcohol. The authors described using computed tomography guidance while bilaterally inserting 22-gauge, 5-inch spinal needles from both the right and left lateral sacral regions, eventually to meet at the midline just anterior to the sacrococcygeal junction (essentially where the ganglion impar is located).

Compared with a previously described approach of simply passing a smaller, shorter needle through the sacrococcygeal junction, the authors opined that their alternative approach avoided the risks of infection, bleeding, and needle breakage. I respectfully beg to differ.

Although I have personally performed the sacrococcygeal approach to ganglion impar injections for many years and have published on this topic,^{2,3} I have never heard of a documented case (neither in clinical practice nor reported within the medical literature) where this approach was associated with a substantial risk for any of those three complications, as long as fluoroscopic guidance was used. The sacrococcygeal approach often takes less than 5 or 10 min, and because it is the most direct approach to the ganglion impar, it usually only requires needle penetration of less than 1 inch (compared with 10 inches of total needle length according to the alternative technique described by the authors). Meanwhile, it intuitively seems likely that the authors’ alternative approach is associated with higher (not lower) risks of each of the three items that they paradoxically named as advantages. Specifically, because the risks of infection and bleeding increase with an increased number of procedures (incident dependent risk), using two (bilateral) needle injection sites instead of one would be expected to double the risk of these complications. The name

impar literally means solitary or unpaired; the ganglion impar is duly named because it is a solitary, midline sympathetic nervous system ganglion, unlike all of the other sympathetic ganglia in the body, which are paired (bilateral). Therefore, because image guidance and contrast are used to confirm appropriate placement, even with this "alternative" technique, the use of two (bilateral) needles instead of one seems unnecessarily redundant. Also, with the 10-fold increase in the length of needle inserted by their technique (compared with the sacrococcygeal approach), it seems likely that the authors have substantially increased the likelihood of inadvertent vascular puncture throughout the tract along the way. Other authors have published that longer (not shorter) needles may be associated with needle breakage during ganglion impar injections. In addition, the attempts to control sacrococcygeal placement of such long needle lengths bilaterally, as seen in the article's computed tomography image, raises serious concerns that less experienced clinicians would be at substantial risk for inadvertently perforating into the peritoneal cavity (rather than staying in the retroperitoneal space, where the ganglion impar is situated), with resultant risks for peritonitis and rectal puncture.

Anesthesiology 2007; 106:1063

Copyright © 2007, the American Society of Anesthesiologists, Inc. Lippincott Williams & Wilkins, Inc.

In Reply:—I thank Dr. Foye for his comments and his interest in my report.¹ I adopted a computed tomography-guided approach to the ganglion impar to allow us to accurately localize the target and find the shortest and least traumatic pathway to the target for injection of neurolytic agent.

The risks of infection, bleeding, and needle breakage are potentially lower because needles pass through low-resistance soft tissues and may therefore be less traumatic. I agree with Dr. Foye that a single needle injection may be just as effective as bilateral needle injection because the ganglion impar is a solitary ganglion.

In conclusion, I am of course happy to hear that this individual case worked out well for this particular patient. But I would caution other spinal proceduralists against attempting the alternative approach described by the authors, particularly because the sacrococcygeal approach is much less invasive, intuitively safer, and clinically effective in most cases.

Patrick M. Foye, M.D., University of Medicine and Dentistry of New Jersey, Newark, New Jersey. patrick.foye@umdnj.edu

References

1. Ho KY, Nagi PA, Gray L, Huh BK: An alternative approach to ganglion impar neurolysis under computed tomography guidance for recurrent vulva cancer. *ANESTHESIOLOGY* 2006; 105:861-2
2. Foye PM, Buttaci CJ, Stitik TP, Yonclas PP: Successful injection for coccyx pain. *Am J Phys Med Rehabil* 2006; 85:783-4
3. Buttaci CJ, Foye PM, Stitik TP: Coccydynia successfully treated with ganglion impar blocks: A case series. *Am J Phys Med Rehabil* 2005; 84:218

(Accepted for publication January 31, 2007.)

Kok-Yuen Ho, M.B.B.S., M.Med., Duke University Medical Center, Durham, North Carolina. hokokyuen@yahoo.com.sg

Reference

1. Ho KY, Nagi PA, Gray L, Huh BK: An alternative approach to ganglion impar neurolysis under computed tomography guidance for recurrent vulva cancer. *ANESTHESIOLOGY* 2006; 105:861-2

(Accepted for publication January 31, 2007.)

Anesthesiology 2007; 106:1063-4

Copyright © 2007, the American Society of Anesthesiologists, Inc. Lippincott Williams & Wilkins, Inc.

Oxycodone's Mechanism of Action and Potency Differences after Spinal and Systemic Routes of Administration

To the Editor:—We read with interest the article by Lemberg *et al.*¹ titled "Antinociception by Spinal and Systemic Oxycodone: Why Does the Route Make a Difference?" that was published in the October 2006 issue of *ANESTHESIOLOGY*. In the following paragraphs, we highlight significant limitations confounding their conclusions.

Although there has been a large increase in the prescribing of the opioid analgesic oxycodone for clinical pain management in the past decade, the differences in the pharmacology of oxycodone relative to the prototypic μ -opioid agonist morphine are less well known. For example, although an analgesic potency ratio for oxycodone to morphine of 1.5 was reported in patients after intravenous administration for postoperative pain management,² the affinity of oxycodone for the μ -opioid receptor is much lower (approximately 40-fold) than that of morphine in radioligand binding studies performed with rat brain homogenate, as well as with membranes prepared from cultured CHO

cells expressing the human μ -opioid receptor (hMOR1).^{3,4} In addition, the potency of oxycodone compared with morphine is considerably lower after spinal administration in rats (approximately 14-fold) and humans (approximately 8-fold).^{5,6} We have also shown that after intracerebroventricular administration in rats, the potency of oxycodone is approximately 44% that of morphine⁷ and that intracerebroventricular oxycodone antinociception is blocked by the κ -selective opioid antagonist nor-binaltorphimine (nor-BNI).⁸

The recent article by Lemberg *et al.*¹ reported that in addition to producing only weak naloxone-reversible antinociception after intrathecal administration to Sprague-Dawley rats, G-protein activation induced by oxycodone in the dorsal horn of the spinal cord was lower compared with that of morphine and oxycodone's O-demethylated metabolite, oxymorphone. In addition, the authors present data purporting to show that oxycodone's antinociceptive effects after subcutaneous administration were blocked by naloxone, but not by nor-BNI. They conclude that the reduced potency of oxycodone after intrathecal administration in rats is related to its low efficacy and potency for G protein-mediated μ -opioid receptor activation, and that an active metabolite such as oxymorphone that is not formed in the central nervous system may account for the differences in oxycodone's antinociceptive effects after subcutaneous and intrathecal administration.

The University of Queensland has licensed intellectual property of QRx Pharma Pty. Ltd., of which Dr. Smith is an inventor. Under university policy, Dr. Smith will receive a portion of the income received by the University of Queensland from QRx in the event of successful commercialization. Also, Dr. Smith's laboratory has undertaken contract research and she has acted as an occasional consultant for QRx Pharma.

Anesthesiology, V 106, No 5, May 2007

However, there are a number of problems with the authors' interpretation of their data, and their results¹ do not justify the conclusions drawn. In previous human studies, circulating oxycodone concentrations remained very low (< 1.2 ng/ml) after systemic and oral modes of administration.⁹⁻¹² Recent studies of oxycodone's pharmacokinetics and metabolism after oral administration in humans found that oxycodone was metabolized predominantly to noroxycodone, with area under the curve ratios for oxycodone:noroxycodone and oxycodone:oxycodone of 1.19 and 0.04, respectively.⁴ Similarly, we have shown that circulating oxycodone levels also remain very low (< 2.1 ng/ml) in rats after subcutaneous administration of oxycodone.¹³ In addition, studies in human CYP2D6-extensive metabolizers showed that oxycodone's pharmacodynamic effects were not significantly altered after blockade of CYP2D6-mediated O-demethylation of oxycodone to oxycodone by quindine,¹² further discounting the possible contribution of metabolically derived oxycodone to the analgesic effects of systemically administered oxycodone.

Furthermore, there are serious methodologic problems with the study involving nor-BNI in the article by Lemberg *et al.*¹ that confound their data interpretation. In previously published dose-response studies, suppression of the antinociceptive effects of the κ -selective opioid agonist, U69,593, by nor-BNI was shown to be maximal after intracerebroventricular administration in rodents, when nor-BNI was administered 24 h before U69,593.¹⁴ Likewise, in other studies, subcutaneous nor-BNI at 5 and 20 mg/kg blocked the antinociceptive effects of the κ -selective opioid agonist U-50,488H in rodents only when nor-BNI was administered at least 2 h before U-50,488H.¹⁵ Furthermore, in the same study, Endoh *et al.*¹⁵ showed that at 30 min after subcutaneous administration, nor-BNI behaves as a μ -antagonist rather than a κ -antagonist. Because nor-BNI was administered 30 min before oxycodone in the study by Lemberg *et al.*¹ and a positive control such as U69,593 or U-50,488H was not included in their study design, the authors' conclusion that nor-BNI did not block the antinociceptive effects of oxycodone is not justified. Moreover, the assertion by Lemberg *et al.* that oxycodone's antinociceptive effects are mediated by μ - rather than κ -opioid receptors is not correct.

Although the reason for oxycodone's low potency after spinal routes of administration remains unclear, it is highly unlikely that oxycodone or some other active metabolite can account for this, as the authors speculate. Rather, it is our view that the findings by Lemberg *et al.*¹ further demonstrate that the antinociceptive effects of oxycodone and morphine are mediated by distinctly different mechanisms and that oxycodone is not a μ -opioid agonist.

Anesthesiology 2007; 106:1064-5

Copyright © 2007, the American Society of Anesthesiologists, Inc. Lippincott Williams & Wilkins, Inc.

In Reply:—Thank you for the opportunity to comment on the letter by Smith *et al.* and to clarify some recurring misconceptions regarding the pharmacology of oxycodone.

Oxycodone is a potent opioid, comparable to morphine, when given systemically. However, as Smith *et al.* also write, oxycodone has a significantly lower affinity for the μ -opioid receptor compared with morphine. This has been shown in several studies.^{1,2} Indeed, the results of our own recent study³ further support the findings that oxycodone has a significantly lower potency compared with morphine when administered directly to the central nervous system in rats.^{4,5}

Smith *et al.* challenge our study and those by many others by arguing that the antinociceptive effect of oxycodone is mediated through the κ -opioid receptor. The previous *in vivo* studies clearly demonstrate that oxycodone is a μ -opioid receptor agonist.^{1,2,6,7} In these studies, the affinity of oxycodone for the κ -opioid receptor is remarkably lower than for the μ -opioid receptor.^{2,6} To the best of our knowledge, not a single *in vitro* study (binding- or G-protein activation) showing κ -opioid receptor agonism of oxycodone has been published.

Maree T. Smith, Ph.D.,* Stephen R. Edwards, M.Sc., Carsten K. Nielsen, Ph.D.* School of Pharmacy, University of Queensland, Brisbane, Australia. m.smith@pharmacy.uq.edu.au

References

- Lemberg KK, Kontinen VK, Siislonen AO, Viljakka KM, Kauhaluoma JT, Korpi ER, Kalso EA: Antinociception by spinal and systemic oxycodone: Why does the route make a difference? *In vitro* and *in vivo* studies in rats. *ANESTHESIOLOGY* 2006; 105:801-12
- Kalso E, Poyhia R, Onnela P, Linko K, Tigerstedt I, Tammiro T: Intravenous morphine and oxycodone for pain after abdominal surgery. *Acta Anesthesiol Scand* 1991; 35:642-6
- Chen ZR, Irvine RJ, Somogyi AA, Bochner F: Mu receptor binding of some commonly used opioids and their metabolites. *Life Sci* 1991; 48:2165-71
- Lalovic B, Kharasch E, Hoffer C, Risper L, Liu-Chen LY, Shen DD: Pharmacokinetics and pharmacodynamics of oral oxycodone in healthy human subjects: Role of circulating active metabolites. *Clin Pharmacol Ther* 2006; 79:461-79
- Poyhia R, Kalso EA: Antinociceptive effects and central nervous system depression caused by oxycodone and morphine in rats. *Pharmacol Toxicol* 1992; 70:125-30
- Backlund M, Lindgren L, Kajimoto Y, Rosenberg PH: Comparison of epidural morphine and oxycodone for pain after abdominal surgery. *J Clin Anesth* 1997; 9:30-5
- Leow KP, Smith MT: The antinociceptive potencies of oxycodone, noroxycodone and morphine after intracerebroventricular administration to rats. *Life Sci* 1994; 54:1229-36
- Ross FB, Smith MT: The intrinsic antinociceptive effects of oxycodone appear to be κ -opioid receptor mediated. *Pain* 1997; 73:151-7
- Poyhia R, Olkkola KT, Seppala T, Kalso E: The pharmacokinetics of oxycodone after intravenous injection in adults. *Br J Clin Pharmacol* 1991; 32:516-8
- Poyhia R, Seppala T, Olkkola KT, Kalso E: The pharmacokinetics and metabolism of oxycodone after intramuscular and oral administration to healthy subjects. *Br J Clin Pharmacol* 1992; 33:617-21
- Kaiko RF, Benziger DP, Fitzmartin RD, Burke BE, Reder RF, Goldenheim PD: Pharmacokinetic-pharmacodynamic relationships of controlled-release oxycodone. *Clin Pharmacol Ther* 1996; 59:52-61
- Heiskanen T, Olkkola KT, Kalso E: Effects of blocking CYP2D6 on the pharmacokinetics and pharmacodynamics of oxycodone. *Clin Pharmacol Ther* 1998; 64:603-11
- Huang L, Edwards SR, Smith MT: Comparison of the pharmacokinetics of oxycodone and noroxycodone in male Dark Agouti and Sprague Dawley rats: Influence of streptozotocin-induced diabetes. *Pharm Res* 2005; 22:1489-98
- Horan P, Taylor J, Yamamura HI, Porreca F: Extremely long-lasting antagonistic actions of nor-binaltorphimine (nor-BNI) in the mouse tail-flick test. *J Pharmacol Exp Ther* 1992; 260:1237-43
- Endoh T, Matsuura H, Tanaka C, Nagase H: Nor-binaltorphimine: A potent and selective κ -opioid receptor antagonist with long-lasting activity *in vivo*. *Arch Int Pharmacodyn* 1992; 316:30-42

(Accepted for publication January 31, 2007.)

Beardsley *et al.*⁸ studied the pharmacology of oxycodone in mice, rats, and rhesus monkeys. In an excellent article, they reported that oxycodone had potent antinociceptive effects in the mouse parapylnquinone writhing, hot-plate, and tail-flick assays acting as a μ -opioid receptor agonist. The selective opioid receptor antagonists were studied in the mice tail-flick test. The antinociceptive effect of oxycodone (subcutaneous administration) was only blocked by the selective μ -opioid receptor antagonist β -funaltrexamine (intracerebroventricular administration). The selective κ - and δ -opioid receptor antagonists nor-binaltorphimine (administered subcutaneously 2 h before the agonist) and naltrindole (subcutaneous administration) were not able to block the antinociceptive effect of oxycodone.⁸ Beardsley *et al.* wrote, "The results have shown that oxycodone is a robust antinociceptive agent, with an abuse liability profile consistent with full μ -opioid receptor agonists."⁸ Oxycodone completely suppressed signs of withdrawal in morphine-dependent rhesus monkeys. In the previous studies, the selective κ -opioid receptor agonists did not suppress signs of morphine withdrawal.^{9,10} Beardsley *et al.*⁸ also demonstrated that even very high

doses of oxycodone did not induce behavior (salivation or diuresis) indicative of κ -opioid like activity. Therefore, high-quality classic pharmacology experiments clearly show that oxycodone is a μ -opioid receptor agonist, not a κ -opioid receptor agonist.

Smith *et al.* agree that oxymorphone is a potent μ -opioid receptor agonist.¹¹ In our recent study,³ nor-binaltorphimine (administered 30 min before study drugs) was not able to antagonize the antinociceptive effect of oxymorphone or oxycodone. Should nor-binaltorphimine behave as a μ -opioid receptor antagonist when given 30 min before the study drugs, as suggested by Smith *et al.*, the antinociceptive effect of oxymorphone should have been significantly attenuated. The antinociceptive effect of oxymorphone, like that of oxycodone, was prevented only by naloxone, not by nor-binaltorphimine.

In our recent study,³ oxycodone showed weaker activation of the spinal μ -opioid receptors compared with morphine. The mechanisms behind this difference are interesting and will be studied further. In the brain, oxycodone activated the μ -opioid receptors, albeit to a lesser extent than morphine. The reason why oxycodone produces more potent antinociception compared with morphine after systemic administration remains to be clarified. Smith *et al.* argue that we are suggesting that the analgesic effects of systemic oxycodone are due to oxymorphone. This is not what we concluded. We suggested that the metabolites may have a role in oxycodone-induced analgesia. We agree that the circulating concentrations of oxymorphone after systemic administration of oxycodone are low, as we¹²⁻¹⁴ and others¹⁵ have shown. Because systemic oxycodone causes potent μ -opioid receptor agonist effects while being a weak μ -opioid receptor agonist with insignificant binding to other opioid receptors, pharmacokinetic explanations must be considered. One possibility is that the access of either oxycodone itself and/or some of its active metabolites to the central nervous system are more effective compared with that of morphine. There are a number of oxycodone metabolites produced in oxidative and reductive reactions that have not been studied *in vivo*. Oxymorphone, on the other hand, is an interesting spinal analgesic, and it has recently been launched as an oral analgesic, too.

Oxycodone binds to the μ -opioid receptor and activates the μ -opioid receptor, whereas it does not bind to the κ -opioid receptor and does not activate the κ -opioid receptor. Importantly, in human beings, oxycodone behaves as a μ -opioid receptor agonist producing analgesia, euphoria, dependence, and other typical μ -opioid effects. Oxycodone does not cause psychotomimetic effects, dysphoria, diuresis, or other effects typical for a κ -opioid agonist. Several aspects of oxycodone pharmacology still need to be studied. However, it is obvious that oxycodone is a μ -opioid receptor agonist, not a κ -opioid receptor agonist.

Kim K. Lemberg, D.D.S.,* Esa R. Korpi, M.D., Ph.D., Antti O. Siiskonen, M.Sc., Jari T. Yli-Kauhaluoma, Ph.D., Vesa K. Kontinen, M.D., Ph.D., Kaarin M. Viljakka, M.D., Eija A. Kalso, M.D., Ph.D. *University of Helsinki, Helsinki, Finland. kim.lemberg@helsinki.fi

References

1. Chen ZR, Irvine RJ, Somogyi AA, Bochner F: Mu receptor binding of some commonly used opioids and their metabolites. *Life Sci* 1991; 48:2165-71
2. Lalovic B, Kharasch E, Hoffer C, Risler L, Liu-Chen L-Y, Shen DD: Pharmacokinetics and pharmacodynamics of oral oxycodone in healthy human subjects: Role of circulating active metabolites. *Clin Pharmacol Ther* 2006; 79:461-79
3. Lemberg KK, Kontinen VK, Siiskonen AO, Viljakka KM, Yli-Kauhaluoma JT, Korpi ER, Kalso EA: Antinociception by spinal and systemic oxycodone: Why does the route make a difference? *In vitro* and *in vivo* studies in rats. *ANESTHESIOLOGY* 2006; 105:801-12
4. Poyhia R, Kalso EA: Antinociceptive effects and central nervous system depression caused by oxycodone and morphine in rats. *Pharmacol Toxicol* 1992; 70:125-30
5. Leow KP, Smith MT: The antinociceptive potencies of oxycodone, noroxycodone and morphine after intracerebroventricular administration to rats. *Life Sci* 1994; 54:1229-36
6. Monory K, Greiner E, Sartania N, Sallai L, Pouille Y, Schmidhammer H, Hanoune J, Borsodi A: Opioid binding profiles of new hydrazone, oxime, carbazone and semicarbazone derivatives of 14-alkoxymorphinans. *Life Sci* 1999; 64:2011-20
7. Thompson CM, Wojno H, Greiner E, May EL, Rice KC, Selley DE: Activation of G-proteins by morphine and codeine congeners: insights to the relevance of O- and N-demethylated metabolites at mu- and delta-opioid receptors. *J Pharmacol Exp Ther* 2004; 308:547-54
8. Beardsley PM, Aceto MD, Cook CD, Bowman ER, Newman JL, Harris LS: Discriminative stimulus, reinforcing, physical dependence, and antinociceptive effects of oxycodone in mice, rats, and rhesus monkeys. *Exp Clin Psychopharmacol* 2004; 12:163-72
9. Fukagawa Y, Katz JL, Suzuki T: Effects of a selective kappa-opioid agonist, U-50,488H, on morphine dependence in rats. *Eur J Pharmacol* 1989; 170:47-51
10. Gmerek DE, Woods JH: Kappa receptor mediated opioid dependence in rhesus monkeys. *Life Sci* 1986; 39:987-92
11. Ross FB, Smith MT: The intrinsic antinociceptive effects of oxycodone appear to be kappa-opioid receptor mediated. *Pain* 1997; 73:151-7
12. Poyhia R, Olkkola KT, Seppala T, Kalso E: The pharmacokinetics of oxycodone after intravenous injection in adults. *Br J Clin Pharmacol* 1991; 32:516-8
13. Poyhia R, Seppala T, Olkkola KT, Kalso E: The pharmacokinetics and metabolism of oxycodone after intramuscular and oral administration to healthy subjects. *Br J Clin Pharmacol* 1992; 33:617-21
14. Heiskanen T, Olkkola KT, Kalso E: Effects of blocking CYP2D6 on the pharmacokinetics and pharmacodynamics of oxycodone. *Clin Pharmacol Ther* 1998; 64:603-11
15. Kaiko RF, Benziger DP, Fitzmartin RD, Burke BE, Reder RF, Goldenheim PD: Pharmacokinetic-pharmacodynamic relationships of controlled-release oxycodone. *Clin Pharmacol Ther* 1996; 59:52-61

(Accepted for publication January 31, 2007.)

Lower Tidal Volumes and Positive End-expiratory Pressure Prevents Alveolar Coagulation in Patients without Lung Injury

To the Editor:—I read with interest the excellent article by Choi *et al.*¹ about the preventive role of mechanical ventilation, with lower tidal volumes plus positive end-expiratory pressure (PEEP), on alveolar coagulation. They demonstrated that mechanical ventilation with lower tidal volumes and PEEP (10 cm H₂O) decreases the procoagulant activity in the lungs of even otherwise healthy surgical patients. The observed procoagulant activity change was explained by mechanical ventilation with high tidal volume and no PEEP. In previous studies,

the same researchers and others showed that there were similar pulmonary hemostasis disturbances in patients with adult respiratory distress syndrome and pneumonia. Although much is unknown about the topic, the authors gave a detailed discussion as to whether this procoagulant activity is a possible sign of repair or a further trigger of proinflammatory process in the lung.

If we exclude this important work by Choi *et al.*, the recent literature provides conflicting evidence on the role of high-tidal volume with no PEEP in causing ventilator-associated lung injury in healthy human lungs.²⁻⁴ Possibly because of the short amount of time that mechanical ventilation is provided during general anesthesia, it was hard to see any clinical effects of potential lung stretch in relatively

The above letter was sent to the authors of the referenced report. The authors did not feel that a response was required. —Michael M. Todd, M.D., Handling Editor

healthy human lungs. Another explanation would be that high-tidal-volume ventilation alone is not a sufficient trigger to cause lung injury in healthy human lungs. Two recent articles from Wrigge *et al.*^{4,5} support the latter explanation. Accepting this, one can hypothesize that mechanical ventilation with high tidal volumes without PEEP does not initiate any tissue injury that can be monitored by proinflammatory cytokine response.

However, when we take the article by Choi *et al.* into account and further consider the bidirectional relation between coagulation and inflammation in pathogenesis of vascular disease as well summarized previously by Levi *et al.*,⁶ we realize that there are different questions to be asked and various hypotheses to be made to fully understand the mechanism of ventilator-associated lung injury in previously healthy subjects. For example, what might be the absolute first trigger to initiate stretch injury in the lungs? As in the vascular pathophysiology, is it the direct stretch of mononuclear cells (in this case alveolar macrophages) that triggers the proinflammatory or procoagulant pathways? Is it a set of proinflammatory cytokines originating from the alveolar macrophages (or even epithelial cells) triggering the procoagulant process in the lungs? Can such processes be triggered by lung cellular stretch through the activation of integrin-mitogen-activated protein kinase-interleukin-8 pathway, which would lead to further chemokine responses?^{7,8} Or do any of the toll-like receptors play a triggering role in initiating transcriptional processes through nuclear factor κ B to deliver proinflammatory pathways including tumor necrosis factor α or interleukin 1β ? Can it be that high-tidal-volume, no-PEEP ventilation cancels the alveolar integrity and stability of alveolar macrophages maintained by transforming growth factor β ?⁹

The sequence of triggers would bring the real mechanisms behind the ventilator-associated lung injury and associated lung injury. Therefore, it is extremely important to understand the sequence of triggers and potential pathways. At this point, if Choi *et al.* performed any other tests in the bronchoalveolar lavage samples, such as proinflammatory cytokines, chemokines, or any transcriptional pathway agents, simultaneously with their procoagulant tests, it would be valuable to

share such data for further development of new hypotheses to test the bidirectional relation between coagulation and inflammation.

Ozan Akça, M.D., University of Louisville, Louisville, Kentucky.
ozan.akca@louisville.edu

The author thanks Nancy Alsip, Ph.D. (University of Louisville, Louisville, Kentucky), for editorial assistance.

References

1. Choi G, Wolthuis EK, Bresser P, Levi M, van der Poll T, Dzoljic M, Vroom MB, Schultz MJ: Mechanical ventilation with lower tidal volumes and positive end-expiratory pressure prevents alveolar coagulation in patients without lung injury. *ANESTHESIOLOGY* 2006; 105:689-95
2. Gajic O, Dara SI, Mendez JL, Adesanya AO, Festic E, Caples SM, Rana R, St Sauver JL, Lymp JF, Afessa B, Hubmayr RD: Ventilator-associated lung injury in patients without acute lung injury at the onset of mechanical ventilation. *Crit Care Med* 2004; 32:1817-24
3. Bregeon F, Roch A, Delpierre S, Ghigo E, Autillo-Touati A, Kajikawa O, Martin TR, Pugin J, Portugal H, Auffray JP, Jammes Y: Conventional mechanical ventilation of healthy lungs induced pro-inflammatory cytokine gene transcription. *Respir Physiol Neurobiol* 2002; 132:191-203
4. Wrigge H, Uhlig U, Zinserling J, Behrends-Callen E, Ottersbach G, Fischer M, Uhlig S, Putensen C: The effects of different ventilatory settings on pulmonary and systemic inflammatory responses during major surgery. *Anesth Analg* 2004; 98:775-81
5. Wrigge H, Uhlig U, Baumgarten G, Menzenbach J, Zinserling J, Ernst M, Dromann D, Welz A, Uhlig S, Putensen C: Mechanical ventilation strategies and inflammatory responses to cardiac surgery: A prospective randomized clinical trial. *Intensive Care Med* 2005; 31:1379-87
6. Levi M, van der Poll T, Buller HR: Bidirectional relation between inflammation and coagulation. *Circulation* 2004; 109:2698-704
7. Goodman RB, Pugin J, Lee JS, Matthay MA: Cytokine-mediated inflammation in acute lung injury. *Cytokine Growth Factor Rev* 2003; 14:523-35
8. Pugin J: Molecular mechanisms of lung cell activation induced by cyclic stretch. *Crit Care Med* 2003; 31:S200-6
9. Pittet JF, Griffiths MJ, Geiser T, Kaminski N, Dalton SL, Huang X, Brown LA, Gotwals PJ, Koteliansky VE, Matthay MA, Sheppard D: TGF-beta is a critical mediator of acute lung injury. *J Clin Invest* 2001; 107:1537-44

(Accepted for publication February 8, 2007.)

Anesthesiology 2007; 106:1066-7

Copyright © 2007, the American Society of Anesthesiologists, Inc. Lippincott Williams & Wilkins, Inc.

An Unusual Cause of Leak in a Silicone Endotracheal Tube Secured by the SecureEasy[®] Endotracheal Tube Holder in the Trauma Intensive Care Unit

To the Editor:—The *LMA-Fastrach*[™] (LMA North America, San Diego, CA) has been used in patients with a difficult airway, including those with an unstable cervical spine.^{1,2} We report a case of a successful intubation *via* the *LMA-Fastrach*[™] in a patient with severe ankylosing spondylitis and an unstable C5-C6 fracture dislocation with subsequent leak around the silicone, dedicated endotracheal tube (ETT), resulting in desaturation.

The 40-yr-old male patient was awake, alert, and spontaneously breathing at the time of admission. During the course of his evaluation, his breathing became progressively laborious, and tracheal intubation was requested by the trauma team. After multiple failed attempts at awake nasal and oral fiberoptic intubation and awake direct laryngoscopy, tracheal intubation was performed blindly *via* a size 4 *LMA-Fastrach*[™] after intravenous administration of 17 mg etomidate by the


trauma team. The patient was transferred to the trauma intensive care unit, where the 7.0-mm-ID, silicone, dedicated ETT was secured at 26 cm at the lips with a SecureEasy[®] ETT holder (Smiths Medical, Dublin, OH). Four hours after the initial intubation, mechanical tidal volumes were noted to decrease slowly (200-300 ml/breath). The presumed diagnosis was a cuff leak; deflation and reinflation of the pilot balloon with 3-5 ml air attested to the integrity of the cuff. The breathing circuit was also checked and found to be intact. The leak eventually resolved. However, the problem recurred and persisted the following days in an inconsistent pattern and at variable intervals. ETT exchange was contemplated but not attempted in light of the initial difficult intubation. The patient subsequently underwent both anterior and posterior fusions of the cervical spine with halo traction placement; no intraoperative leaks were noted. On admission day 9, however, increasing leakage and episodes of desaturation led to the decision to perform a tracheostomy. In the operating room, careful listening determined the leak to be at the level of the 15-mm male connector. Application of electrical tape to the proximal end of the ETT corrected the problem.

After insertion of a No. 8 Shiley[®] tracheostomy tube (Tyco Healthcare, Mansfield, MA), the ETT was removed, and close examination

Support was provided solely from institutional and/or departmental sources.

The above letter was sent to The Laryngeal Mask Company for reply. The manufacturer did not feel that a response was required. After numerous failed attempts to acquire a reply to this letter from Smiths Medical, it is being published without a response. —Michael M. Todd, M.D., Handling Editor

Fig. 1. The holes in the silicone endotracheal tube seem to line up with the prongs on the SecureEasy® ETT holder (Smiths Medical, Dublin, OH).



revealed several holes at the proximal end of the ETT that lined up with the metal prongs of the SecureEasy® device (fig. 1). The ETT cuff was found to be intact. It was also noted that the 15-mm connector was from a 6.5-mm-ID ETT.

The *LMA-Fastrach*™ manufacturer was contacted and informed of the events. After reviewing all relevant information and photographs, the manufacturer of the *LMA-Fastrach*™ stated that the problem we encountered had never been previously reported to LMA North America (as of October 2005). Several factors seem to have contributed to the leak in the ETT. The soft medical grade silicone of the dedicated ETT supplied with the *LMA-Fastrach*™ can be torn or perforated by prolonged contact with sharp or pointed objects. The respiratory care department at our institution has used the SecureEasy® for some time without incident. We assume that the metal prongs do not perforate or otherwise damage the standard polyvinylchloride ETT. Moreover, tension exerted on the soft silicone ETT by inadequately supported ventilator tubing could have stretched open the small perforations and may have accounted for the inconsistent nature of the leak. Finally, the

leak was further compounded by the inadvertent use of an incorrectly sized 15-mm male ETT connector.

In conclusion, our unique case raises concerns about the long-term use of the silicone ETT packaged with the *LMA-Fastrach*™ in the critical care unit in conjunction with the SecureEasy® ETT holder.

Xuan Au-Truong, M.D., David Lang, D.O., Christopher S. Wise, M.D., Reza Voosoughi, M.D., Ninos J. Joseph, B.S.* Advocate Illinois Masonic Medical Center, Chicago, Illinois. ninos-j.joseph@advocatehealth.com

References

1. Agarwal M, Kawatra R, Dali JS: Intubation in unstable cervical spine: ILMA or Macintosh laryngoscope? (abstract). *Can J Anaesth* 2004; 51:A27
2. Sener EB, Sarihasan B, Ustun E, Kocamanoglu S, Kelsaka E, Tur A: Awake tracheal intubation through the intubating laryngeal mask airway in a patient with halo traction. *Can J Anaesth* 2002;49:610-3

(Accepted for publication October 11, 2006.)

Coronary Artery Stent Placement Immediately before Noncardiac Surgery: A Potential Risk?

To the Editor:—Percutaneous coronary intervention (PCI), angioplasty with stenting, is commonly used for treatment of symptomatic coronary artery disease. The introduction of stents has reduced the incidence of restenosis, one of the major drawbacks of coronary angioplasty, and has proved to be an alternative treatment for bypass surgery. This strategy may be attractive compared with bypass surgery in patients scheduled to undergo general surgery, because the delay of the index surgical procedure is prevented. However, initially, stent placement causes complete denudation of the arterial endothelial surface, and stent struts may damage the media or penetrate into the lipid core, inducing inflammatory and coagulation activity. These factors temporarily increase the risk of in-stent thrombosis until a neointima has been formed. Fortunately, the introduction of dual antiplatelet therapy (aspirin and clopidogrel) has overcome this complication and reduced the rate of in-stent thrombosis to less than 1%.

Dr. Schouten is supported by an unrestricted research grant from the Netherlands Organization of Health Research and Development, The Hague, The Netherlands, and an unrestricted research grant from Lijf & Leven Foundation, Rotterdam, The Netherlands.

However, recent stent placement might be potentially harmful for patients undergoing noncardiac surgery. Surgery increases the thrombosis risk due to a perioperative stress response including sympathetic activation promoting shear stress on arterial plaques, enhanced vascular reactivity conducive to vasospasm, reduced fibrinolytic activity, platelet activation, and hypercoagulability. In addition, while the surgical patient is in a hypercoagulable state, dual antiplatelet therapy is often interrupted because of the fear for excessive bleeding complications during surgery.

This double-edged sword of coronary stenting and prevention of cardiac complications on one hand and an excess of bleeding risk on the other remains a controversial issue in perioperative management. Therefore, we have reviewed the currently available evidence on stent-related complications in the perioperative period in which timing of surgery and antiplatelet strategy seems to play a pivotal role.

A systematic electronic search of published reports on Medline was undertaken to identify studies published between January 1995 and October 2006 in English language that reported on perioperative cardiac outcome after noncardiac surgery in patients with a history of PCI with stenting. To identify eligible studies, the follow-

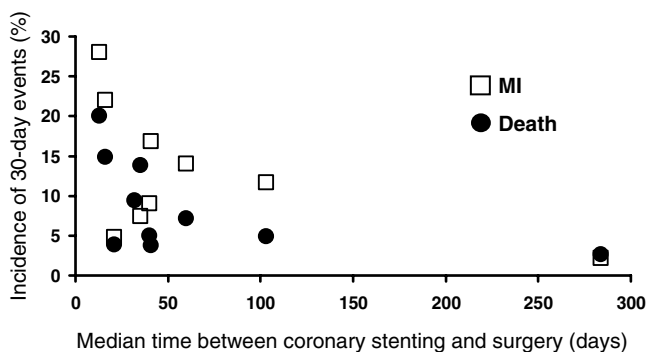


Fig. 1. Incidence of perioperative complications in studies with different median times between percutaneous transluminal coronary angioplasty plus stenting and noncardiac surgery.^{1–10} MI = myocardial infarction.

ing Medical Subject Heading terms, or a combination of these, were used: *stent, myocardial revascularization, surgery, postoperative complications, mortality, myocardial infarction, and perioperative care*. Furthermore, we examined the reference lists of identified articles and published recommendations for perioperative cardiac risk management. Eventually, a total of 10 relevant studies were identified.^{1–10} Pertinent data from the selected studies were extracted independently by two investigators.

The 10 studies encompass a total of 980 patients who underwent noncardiac surgery after coronary stent placement. The median time from PCI to noncardiac surgery ranged from 13 to 284 days. The majority of reports included bare metal stent use, and only 2 recent studies reported the outcome of drug-eluting stents.^{8,10} Perioperative myocardial infarction and death were common complications, with myocardial infarction rates ranging from 2% to 28% and death ranging from 3% to 20% (fig. 1). Studies with a short median interval between PCI and noncardiac surgery reported higher cardiac complication rates as compared with reports with a longer median time interval. Importantly, when studies with a longer median interval between PCI and noncardiac surgery were evaluated in more detail, patients with early surgery experienced more cardiac events than those with late surgery (table 1). Discontinuation of antiplatelet therapy is an important factor in this respect. Unfortunately, not all studies provided data on the number of patients that stopped antiplatelet therapy before surgery. However, if data were available, there was a clear trend toward a higher incidence of perioperative events after stopping antiplatelet therapy. In the report of Kaluza *et al.*,¹ 6 of 8 patients who died in the perioperative period were without antiplatelet therapy. The same trend was found by Sharma *et al.*³; 86% of patients who discontinued antiplatelet therapy died perioperatively *versus* only 5% in the group of patients who continued antiplatelet therapy. Recently, we confirmed this finding in a study of 192 patients. In particular, in patients with early noncardiac surgery, there was a marked difference in major adverse cardiac events (30% *vs.* 0%, respectively, for patients who stopped and continued antiplatelet therapy).¹⁰

The minimal period in which antiplatelet therapy should be prescribed before noncardiac surgery is ill-defined. A period of 4 weeks seems to be too short, as shown by the study of Brichon *et al.*⁵ In a group of 20 patients, 2 experienced perioperative in-stent thrombosis, suggesting that a prolonged period of antiplatelet therapy may be required. A period of 6 weeks is supported by the results of the studies of Wilson *et al.*⁴ and Reddy *et al.*² In a group of 79 patients undergoing noncardiac surgery after an interval of 6 weeks, no major cardiac events occurred. These results were questioned by the study of Vicenzi *et al.*⁷ In 56 patients who underwent noncardiac surgery more than 90 days after PCI, the cardiac event rate was as high as 34% within 3 months after surgery.⁷ However, it

Table 1. Incidence of Perioperative Events in Noncardiac Surgery after Coronary Stent Placement

Study	Time to Surgery	n	Mortality, %	Myocardial Infarction, %
Wilson <i>et al.</i> ⁴	< 6 weeks	168	4	6
	> 6 weeks	39	0	0
Kaluza <i>et al.</i> ¹	< 2 weeks	25	32	28
	> 2 weeks	15	0	0
Sharma <i>et al.</i> ³	< 3 weeks	27	26	22
	> 3 weeks	20	5	10
Reddy <i>et al.</i> ²	< 6 weeks	16	25	38
	> 6 weeks	40	0	0
Brichon <i>et al.</i> ⁵	< 3 months	32	3	9
Godet <i>et al.</i> ⁹	5–8 weeks	78	5	9
Schouten <i>et al.</i> ¹⁰	Early*	30	13	13
	Late*	162	2	0.6
Leibowitz <i>et al.</i> ⁶	< 2 weeks	29	24	7
	> 2 weeks	65	9	8
Vicenzi <i>et al.</i> ⁷	< 35 days	22		72†
	35–90 days	25		44†
	> 90 days	56		34†

The study of Ward *et al.*⁸ is not included in this table because they did not report the incidence of adverse events separately for percutaneous coronary intervention-plus-stent procedures.

* Early surgery was defined as within 1 month after bare metal stenting, within 3 months after sirolimus drug-eluting stenting, and within 6 months after paclitaxel drug-eluting stenting. † Not only perioperative events but also events less than 3 months within surgery are included. Events were defined as cardiac death, myocardial infarction, repeated percutaneous coronary interventions, congestive heart failure, unstable angina, significant arrhythmias, and myocardial cell injury.

should be taken into account that in a number of patients, antiplatelet therapy was stopped 3 days before noncardiac surgery, which may be related to adverse outcome. Ferrari *et al.*¹¹ showed that stopping antiplatelet therapy, even after a long period since stenting (mean time between stenting and withdrawal 15.5 ± 6.5 months), was a significant risk factor for adverse cardiac events.

In conclusion, the current available literature suggests that noncardiac surgery after PCI with stenting should be delayed at least 6 weeks, and dual antiplatelet therapy is associated with improved outcome.

Olaf Schouten, M.D., Jeroen J. Bax, M.D., Ph.D., Johan Damen, M.D., Ph.D., Don Poldermans, M.D., Ph.D.* *Erasmus Medical Center, Rotterdam, The Netherlands. d.poldermans@erasmusmc.nl

References

- Kaluza GL, Joseph J, Lee JR, Raizner ME, Raizner AE: Catastrophic outcomes of noncardiac surgery soon after coronary stenting. *J Am Coll Cardiol* 2000; 35:1288–94
- Reddy PR, Vaitkus PT: Risks of noncardiac surgery after coronary stenting. *Am J Cardiol* 2005; 95:755–7
- Sharma AK, Ajani AE, Hamwi SM, Maniar P, Lakhani SV, Waksman R, Lindsay J: Major noncardiac surgery following coronary stenting: When is it safe to operate? *Catheter Cardiovasc Interv* 2004; 63:141–5
- Wilson SH, Fasseas P, Orford JL, Lennon RJ, Horlocker T, Charnoff NE, Melby S, Berger PB: Clinical outcome of patients undergoing non-cardiac surgery in the two months following coronary stenting. *J Am Coll Cardiol* 2003; 42: 234–40
- Brichon PY, Boitet P, Dujon A, Mouroux J, Peillon C, Riquet M, Velly JF, Ris HB: Perioperative in-stent thrombosis after lung resection performed within 3 months of coronary stenting. *Eur J Cardiothorac Surg* 2006; 30:793–6
- Leibowitz D, Cohen M, Planer D, Mosseri M, Rott D, Lotan C, Weiss AT: Comparison of cardiovascular risk of noncardiac surgery following coronary angioplasty with *versus* without stenting. *Am J Cardiol* 2006; 97:1188–91
- Vicenzi MN, Meislitz T, Heitzinger B, Halaj M, Fleisher LA, Metzler H: Coronary artery stenting and non-cardiac surgery: A prospective outcome study. *Br J Anaesth* 2006; 96:686–93

8. Ward HB, Kelly RF, Thottapurathu L, Moritz TE, Larsen GC, Pierpont G, Santilli S, Goldman S, Krupski WC, Littooy F, Reda DJ, McFalls EO: Coronary artery bypass grafting is superior to percutaneous coronary intervention in prevention of perioperative myocardial infarctions during subsequent vascular surgery. *Ann Thorac Surg* 2006; 82:795-800

9. Godet G, Riou B, Bertrand M, Fléron MH, Goarin JP, Montalescot G, Coriat P: Does preoperative coronary angioplasty improve perioperative cardiac outcome? *ANESTHESIOLOGY* 2005; 102:739-46

10. Schouten O, Van Domburg RT, Bax JJ, de Jaegere PJ, Dunkelgrun M,

Feringa HH, Hoeks SE, Poldermans D: Noncardiac surgery after coronary stenting: Early surgery and interruption of antiplatelet therapy are associated with an increase in major adverse cardiac events. *J Am Coll Cardiol* 2007; 49:122-4

11. Ferrari E, Benhamou M, Cerboni P, Marcel B: Coronary syndromes following aspirin withdrawal: A special risk for late stent thrombosis. *J Am Coll Cardiol* 2005; 45:456-9

(Accepted for publication December 19, 2006.)

Anesthesiology 2007; 106:1069-70

Copyright © 2007, the American Society of Anesthesiologists, Inc. Lippincott Williams & Wilkins, Inc.

A New Twist in Approaching Difficult Tracheal Intubation. Description of an Economic, Easy, and Effective Way: The Σ Way

To the Editor:—After direct laryngoscopy, tracheal intubation has been reported to be awkward in 2.5% and difficult in 1.8% of cases.¹ Change of blade type or length, the backward upward rightward pressure (BURP) maneuver,² and optimal external laryngeal manipulation³ have shown to significantly improve the degree of visualization of the larynx. However, there are some cases in which intubation remains difficult. In these cases, a semirigid stylet can be used to alter the curvature of the tube to facilitate intubation. Anesthesiologists usually employ the so-called hockey stick configuration to direct the tube toward the airway when the larynx is not readily visible (e.g., Cormack and Lehane grade 3 or 4). However, although withdrawal of the stylet causes the tip of the endotracheal tube to move anteriorly, thus facilitating intubation,⁴ there are still some cases in which intubation is impossible. This could be due not only to a particularly reduced interincisor distance or a particularly marked prognathism or retrognathism, but also to the impossibility to flex the cervical spine or extend the atlanto-occipital joint completely up to the sniffing position. In many of the aforesaid situations, alignment of the mouth, larynx and pharynx axes could be almost impossible. In such cases, even if partial insertion of the tube is achieved by means of hockey stick configuration of the tube, its rectilinear part may hit the superior dental arch, thus preventing the anesthesiologist from directing and finally advancing its distal tip through the vocal cords.

In all of these cases, and generally in every situation where intubation is difficult, we have found a new way of shaping the tube with the stylet (fig. 1) that is particularly easy and effective. The tube is shaped in a way that resembles the Greek letter Σ , with two curves, the distal one being more pronounced. The difference with the traditional hockey stick configuration is evident: With this new method, the endotracheal tube is shaped according to three main axes (a, b, and c), whereas in the traditional way, there are only two axes. In addition, with this new configuration, the tube can safely be shaped in such a way that its distal part (axis c) can be even longer compared with the traditional way, because it is almost impossible for its proximal part to hit the superior dental arch (see next paragraph).

Correct placement of the endotracheal tube is possible after only four simple phases. Under direct laryngoscopy, the tube is initially inserted into the patient's oral cavity with axis a parallel to his body surface (phase I). At the end of this phase, the distal part of the tube follows the tongue profile, and axis c coincides with the mouth axis. The tube is then rotated backward (in the sagittal plane) by 45°–60° (phase II). The tube now fits perfectly to the profile of tongue and laryngopharynx: In fact, axis c is now aligned with the pharynx axis, whereas axis b coincides with the mouth axis. Finally, there should be a combined movement of further backward rotation (10°–15°) and an advance of the endotracheal tube (phase III). This

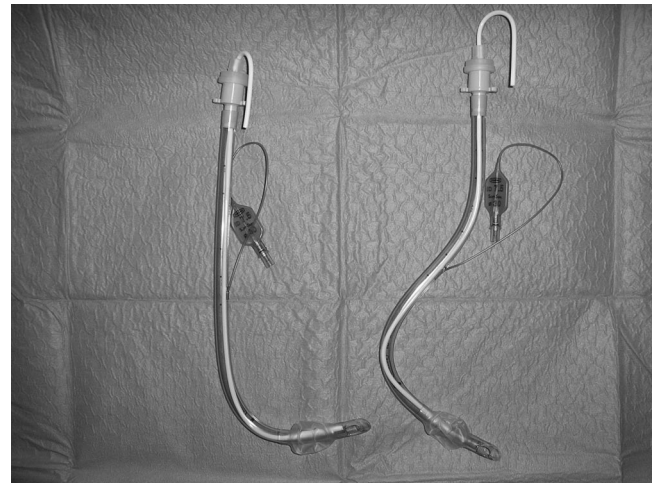


Fig. 1. The traditional “hockey stick” configuration (left) compared with the new way of shaping the tube (right). The difference between these two configurations is evident: Whereas the first tube is shaped according to two main axes, the second one takes advantage of three different axes.

last phase is allowed by the proximal curve of the tube, which prevents it from hitting the superior dental arch. Moreover, the combined movement of rotation-advance not only aligns axis c with the larynx axis, but also permits the distal tip of the tube to pass through the vocal cords.

At this time, the tube is almost in the right position. It is sufficient to hold it firmly in place while an assistant (or the anesthesiologist) removes the stylet (phase IV). A minimum, further advance of the tube may be necessary. One possible question the reader might ask is whether it is easy or difficult to remove the stylet. In our experience, if medical gel or spray lubricant is used, the force that must be applied to remove the stylet is comparable to the force applied when a traditional tube configuration is used.

This technique has many peculiarities and advantages over other commonly used extraglottic and supraglottic devices: Not only does it allow anesthesiologists to intubate blindly when there is a poor laryngeal view (e.g., Cormack and Lehane grade 3 or 4, blood/secretions in the pharynx), thus securing the airway, but it is also adjustable to different patients, because the anesthesiologist can decide to shape and angle the tube as preferred, according to his or her needs. In addition, this technique allows us to intubate patients who otherwise could not be intubated with the traditional hockey stick configuration, and, in our experience, systematic use of this simple method could result in minimal use of more complex and more expensive devices.

Support was provided solely from institutional and/or departmental sources.

We started using this technique more than 20 yr ago, when many of the modern devices for the management of difficult airways had not been invented. It is therefore an old technique, but it may still be the first choice when a fiberoptic bronchoscope or any other airway management device is not immediately available, and a life-saving option when a particular contingent situation (*e.g.*, in the emergency room) does not allow the anesthesiologist to take time to deal with more complex instrumentation and techniques.

Luca La Colla, M.S.,* Giorgio La Colla, M.D., Davide Poli, M.D., Andrea Albertin, M.D. *IRCCS San Raffaele, Milan, Italy. l.lacolla@studenti.hsr.it

References

1. Rose DK, Cohen MM: The airway: Problems and predictions in 18,500 patients. *Can J Anesth* 1994; 41:372-83
2. Takahata O, Kubota M, Mamiya K, Akama Y, Nozaka T, Matsumoto H, Ogawa H: The efficacy of the "BURP" maneuver during a difficult laryngoscopy. *Anesth Analg* 1997; 84:419-21
3. Benumof JL, Cooper SD: Quantitative improvement in laryngoscopic view by optimal external laryngeal manipulation. *J Clin Anesth* 1996; 8:136-40
4. Stix MS, Mancini E: How a rigid stylet can make an endotracheal tube move (letter). *Anesth Analg* 2000; 90:1008

(Accepted for publication January 5, 2007.)