

## Late Thrombosis of a Drug-eluting Stent Presenting in the Perioperative Period

Duncan G. de Souza, M.D.,\* Victor C. Baum, M.D.,† Natalie M. Ballert, M.D.‡

DRUG-ELUTING stents (DES) represent the latest percutaneous coronary intervention (PCI) designed to deal with the problem of in-stent restenosis. These stents are impregnated with a drug (sirolimus or paclitaxel) that retards the neointimal proliferation that leads to restenosis. The thrombogenic profile of DES differs from that of bare metal stents. Postprocedure dual antiplatelet therapy (clopidogrel and aspirin) is required for all types of stents. The recommended duration is 1 month for bare metal stents, 3 months for sirolimus DES, and 6 months for paclitaxel DES.<sup>1</sup> Patients are then maintained on lifelong aspirin. Stent thrombosis is described as acute, subacute, or late (> 30 days). An emerging phenomenon is the observation that DES may carry a higher risk of late stent thrombosis. We report a case of perioperative very late stent thrombosis occurring in a patient with a DES.

### Case Report

A 69-yr-old male patient was scheduled to undergo hand-assisted laparoscopic nephroureterectomy for a proximal ureteral tumor. He had coronary artery disease with two paclitaxel DES (Taxus, Boston Scientific Natick, MA) placed 29 months previously. Dual antiplatelet therapy with clopidogrel and aspirin was maintained for 1 yr, after which clopidogrel was stopped and the patient continued to take aspirin. Preoperative assessment showed him to be angina free, with good effort tolerance and no symptoms of congestive heart failure. Consequently, no preoperative cardiac testing was performed. Preoperative medications included metoprolol and atorvastatin, which were taken on the day of surgery. At the request of the surgeon, aspirin was stopped 10 days preoperatively.

Anesthesia induction and maintenance were uneventful. Surgery took 5 h, during which time the patient maintained stable hemodynamics without tachycardia. Blood loss was minimal. The trachea was successfully extubated, and the patient was taken to the postanesthesia care unit. The blood pressure and heart rate remained within normal limits.  $\beta$ -Blockers were not given intraoperatively or in the postanesthesia

care unit. After 70 min in the postanesthesia care unit, the bedside nurse noticed ST-segment changes on the monitor. Blood pressure and heart rate were normal, and the patient did not report any chest pain. During preparation for an urgent electrocardiogram, the rhythm deteriorated into ventricular tachycardia without a palpable pulse. The patient was immediately electrically cardioverted. He required a total of four shocks to convert to sinus rhythm. The patient continued to have nonsustained runs of ventricular tachycardia. He was given 2 g magnesium sulfate and 150 mg amiodarone. His blood pressure was 70/40 mmHg. The electrocardiogram demonstrated deep ST-segment depressions across the anterior precordial leads, suggestive of posterior myocardial infarction. With cardiogenic shock secondary to presumed myocardial infarction and an unstable cardiac rhythm, a decision was made to secure the airway and emergently proceed to the cardiac catheterization laboratory. Coronary angiography revealed acute thrombosis at the site of his paclitaxel DES in the proximal circumflex artery (fig. 1). The paclitaxel DES in the left anterior descending artery was patent. Balloon angioplasty restored vessel patency (fig. 2).

### Discussion

The development of DES has ushered in a new era in PCI due to the significantly lower rate of in-stent restenosis<sup>2,3</sup> and no apparent increase in risk. After US Food and Drug Administration approval in April 2003, DES have rapidly become the stent of choice for the approximately 1 million PCI performed each year in the United States. It is clear that interruption of dual antiplatelet therapy is known to carry a high risk of stent thrombosis with significant mortality.<sup>4</sup> Therefore, if possible, surgery should be delayed to allow completion of the recommended course of dual antiplatelet therapy. When preoperative cardiac testing reveals a need for PCI, the appropriate choice of stent is dictated by the urgency of the planned surgery.<sup>5</sup>

Recently, there has been gathering evidence that late stent thrombosis may be occurring at a higher rate in DES.<sup>6,7</sup> Late stent thrombosis in bare metal stents is extremely rare in the absence of intracoronary radiation. The risk of late stent thrombosis with bare metal stents lessens over time, presumably due to endothelialization of the stent. However, the risk of late stent thrombosis in DES seems to persist and is associated with a high mortality rate. Predictors of stent thrombosis include premature cessation of antiplatelet therapy, bifurcation lesions, renal failure, and low ejection fraction.<sup>6</sup> In September 2006, the Food and Drug Administration released a statement saying that they are "aware of a small but significant increase in the rate of death and myocardial infarction possibly due to stent thrombosis in patients treated with DES . . . At this time the Food and Drug Adminis-

This article is accompanied by an Editorial View. Please see: Kersten JR, Fleisher LA: Drug-eluting coronary stents: What are the risks? ANESTHESIOLOGY 2007; 106:898-900.

\* Assistant Professor, † Professor, Departments of Anesthesiology and Pediatrics, ‡ Resident, Department of Anesthesiology, University of Virginia Health System.

Received from the Department of Anesthesiology, University of Virginia Health System, Charlottesville, Virginia. Submitted for publication November 13, 2006. Accepted for publication December 29, 2006. Support was provided solely from institutional and/or departmental sources.

Address correspondence to Dr. de Souza: University of Virginia Health System, Department of Anesthesiology, P.O. Box 800710, Charlottesville, Virginia 22908-0710. dgd6n@virginia.edu. Individual article reprints may be purchased through the Journal Web site, [www.anesthesiology.org](http://www.anesthesiology.org).

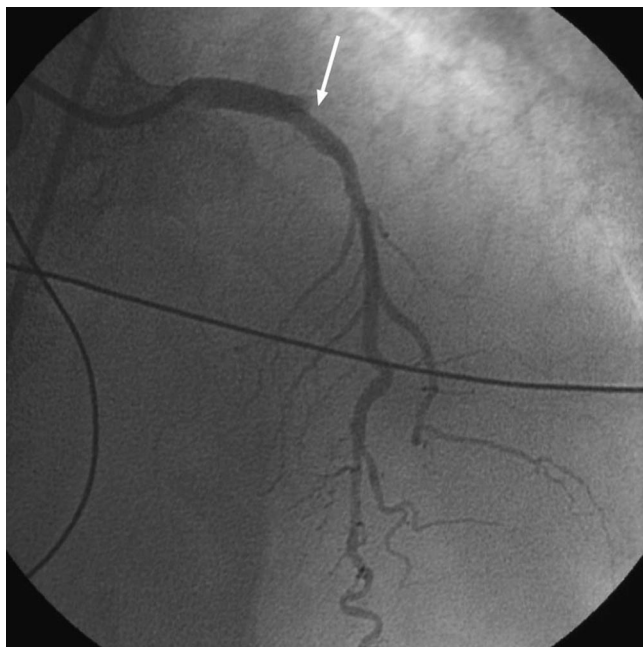


Fig. 1. Coronary angiography showing acute thrombosis (white arrow) in the proximal circumflex artery at the site of the drug-eluting stent.

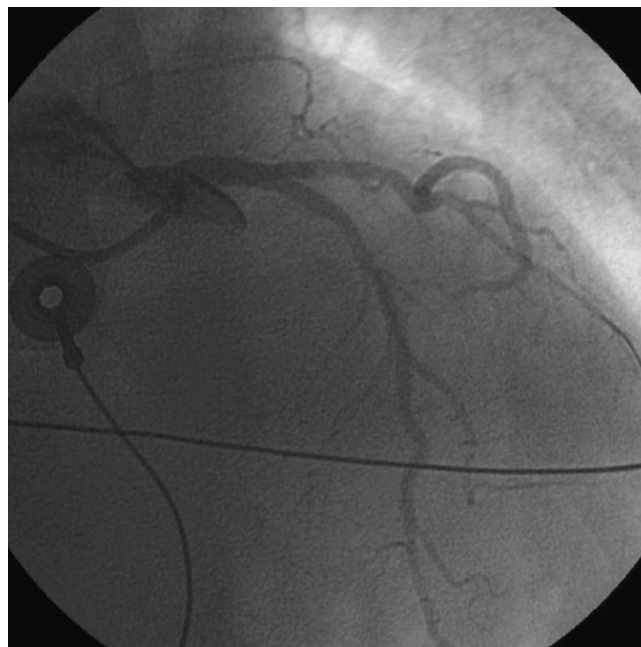


Fig. 2. Balloon angioplasty has restored vessel patency.

tration believes that coronary DES remain safe and effective when used for approved indications . . .”<sup>§</sup>

The trials<sup>2,3</sup> that established the efficacy of DES *versus* bare metal stents in the reduction of restenosis were confined to low-risk lesions. The reality of clinical practice is that a large number of PCI with DES occurs as off-label use in patients with high-risk lesions (lesion type or patient comorbidity) where the incidence of stent thrombosis is believed to be higher and the reduction in the rate of restenosis is attenuated.

Against this backdrop, the implications for the perioperative period are significant. Our patient was 29 months removed from DES placement and 17 months removed from stopping clopidogrel. Recommendations to continue clopidogrel for 12 months after DES placement<sup>8</sup> would not have impacted our patient, who had completed 1 yr of dual antiplatelet therapy. McFadden *et al.*<sup>9</sup> reported four cases of late stent thrombosis (average 12 months) after stopping aspirin. Three of the cases occurred when aspirin was stopped preoperatively.

More than 3 million patients in the United States have DES, and many of them will present for surgery after having completed dual antiplatelet therapy. Therefore, we believe that our patient represents a common clinical scenario of underappreciated risk. Guidelines for perioperative management after completion of dual antiplatelet therapy do not exist at this time. The combination of stopping aspirin and the prothrombotic state induced by surgery likely caused stent thrombosis. Our

case demonstrates that patients with DES are not free from risk after they have completed their regimen of dual antiplatelet therapy. On the contrary, the risk of stent thrombosis persists and can lead to major perioperative morbidity. We urge physicians caring for such patients to exercise extreme caution when considering stopping aspirin preoperatively, and we eagerly await guidelines for the treatment of DES patients in the perioperative period.

(Since the acceptance of this case report for publication, the following document has been released: Grines CL, Bonow RO, Casey DE Jr, Gardner TJ, Lockhart PB, Moliterno DJ, O’Gara P, Whitlow P: Prevention of premature discontinuation of dual antiplatelet therapy in patients with coronary artery stents: A science advisory from the American Heart Association, American College of Cardiology, Society of Cardiovascular Angiography and Interventions, American College of Surgeons and American Dental Association, with representation from the American College of Physicians. *Circulation* 2007; 115:813–8)

## References

1. Smith SC, Feldman TE, Hirshfeld JW, Jacobs AK, Kern MJ, King SB III, Morrison DA, O’Neill WW, Schaff HV, Whitlow PL, Williams DO, Antman EM, Smith SC Jr, Adams CD, Anderson JL, Faxon DP, Fuster V, Halperin JL, Hiratzka LF, Hunt SA, Jacobs AK, Nishimura R, Ornato JP, Page RL, Riegel B: ACC/AHA Task Force on Practice Guidelines and ACC/AHA/SCAI 2005 guideline update for percutaneous coronary intervention: A report of the ACC/AHA Task Force Practice Guidelines. *Circulation* 2006; 113:e166–286
2. Moses JW, Leon MB, Popma JJ, Fitzgerald PJ, Holmes DR, O’Shaughnessy C, Caputo RP, Kereiakes DJ, Williams DO, Teirstein PS, Jaeger JL, Kuntz RE, SIRIUS Investigators: Sirolimus-eluting stents *versus* standard stents in patients with stenosis in a native coronary artery *N Engl J Med* 2003; 349:1315–23
3. Stone GW, Ellis SG, Cox DA, Hermiller J, O’Shaughnessy C, Mann JT, Turco

§ US Food and Drug Administration Statement on Coronary Drug-Eluting Stents. Available at: <http://www.fda.gov/cdrh/news/091406.html>. Accessed September 14, 2006.

M, Caputo R, Bergin P, Greenberg J, Popma JJ, Russell ME, TAXUS-IV Investigators: A polymer-based paclitaxel-eluting stent in patients with coronary artery disease. *N Engl J Med* 2004; 350:221-31

4. Kaluza GL, Joseph J, Lee JR, Raizner ME, Raizner AE: Catastrophic outcomes of noncardiac surgery soon after coronary stenting. *J Am Coll Cardiol* 2000; 25:1288-94

5. Satler LF: Recommendations regarding stent selection in relation to the timing of noncardiac surgery postpercutaneous coronary intervention. *Catheter Cardiovasc Interv* 2004; 63:146-7

6. Iakovou I, Schmidt T, Bonizzi E, Ge L, Sangiorgi GM, Stankovic G, Airolidi F, Chieffo A, Montorfano M, Carlino M, Michev I, Corvaja N, Briguori C, Gerckens U, Grube E, Colombo A: Incidence, predictors and outcome of thrombosis after successful implantation of drug-eluting stents. *JAMA* 2005; 293:2126-30

7. Pfisterer M, Brunner-La Roca HP, Buser PT, Rickenbacher P, Hunziker P,

Mueller C, Jeger R, Bader F, Osswald S, Kaiser C: Late clinical events after clopidogrel discontinuation may limit the benefits of drug-eluting stents. *J Am Coll Cardiol* 2006; 48:2584-91

8. Silber S, Albertsson P, Aviles FF, Camici PG, Colombo A, Hamm C, Jorgensen E, Marco J, Nordrehaug JE, Ruzyllo W, Urban P, Stone GW, Wijns W, Task Force for Percutaneous Coronary Interventions of the European Society of Cardiology: Guidelines for percutaneous coronary interventions. The Task Force for Percutaneous Coronary Interventions of the European Society of Cardiology. *Eur Heart J* 2005; 26:804-47

9. McFadden EP, Stabile E, Regar E, Cheneau E, Ong ATL, Kinnaird T, Suddath WO, Weissman NJ, Torguson R, Kent KM, Pichard AD, Satler LF, Waksman R, Serruys PW: Late thrombosis in drug-eluting coronary stents after discontinuation of antiplatelet therapy. *Lancet* 2004; 364:1519-21

Anesthesiology 2007; 106:1059-60

Copyright © 2007, the American Society of Anesthesiologists, Inc. Lippincott Williams & Wilkins, Inc.

## Etomidate-induced Pacemaker-mediated Ventricular Tachycardia

Michael D. Altose, M.D., Ph.D.,\* Elias León-Ruiz, M.D.†

ETOMIDATE is a hypnotic drug used for both induction and maintenance of anesthesia. An induction dose typically has little effect on cardiovascular performance, and its rapid onset, quick recovery, and maintenance of blood pressure make etomidate a good choice for ambulatory external cardioversion.<sup>1,2</sup> Some consider this drug to be the agent of choice in patients who may become hemodynamically unstable.<sup>3,4</sup> One of the most common side effects of etomidate is transient skeletal muscle movements, particularly myoclonus.<sup>1-5</sup> Although arrhythmias are rarely encountered with etomidate, we present a case of etomidate-induced pacemaker-mediated ventricular tachycardia.

### Case Report

A 27-yr-old woman presented for cardioversion during general anesthesia. Her medical history was remarkable for multiple congenital heart defects, including subaortic stenosis, coarctation of the aorta, ventricular septal defect, and anomalous return of the left superior vena cava to the coronary sinus. Previous surgeries included repair of coarctation of the aorta and pulmonary artery banding (in infancy); repair of ventricular septal defect, subaortic resection, and tricuspid valvuloplasty (age 7 yr); and aortic valve replacement with a St. Jude valve (age 14 yr). The patient underwent pacemaker placement at age 7 yr due to postsurgical complete heart block, with several subsequent revisions. She presented in atrial fibrillation that had been unresponsive to previous attempts at electrical direct current cardioversion. Her medications were lisinopril, furosemide, warfarin, and digoxin. There were no known allergies and no history of adverse reaction to anes-

thetic agents. Vital signs and serum electrolytes were within normal limits, and the electrocardiogram showed atrial fibrillation with normal ventricle capture at a rate of 70 beats/min (fig. 1).

Before the procedure, the pacemaker (Prodigy Model DR 7860; Medtronic Inc, Minneapolis, MN) was found to be operating normally with ventricular pacing at 70 beats/min in a rate-responsive mode. The responsive function was then disabled. After preoxygenating the patient with 100% O<sub>2</sub> by facemask, she was given 10 mg intravenous etomidate and cardioversion (200 J) was attempted, without success. Severe myoclonic activity was observed immediately. When it was confirmed that the patient was still properly anesthetized, cardioversion was attempted a second time, but the atrial fibrillation could not be resolved. At this point, the cardiology team decided to make no further attempts at cardioversion, and the procedure was terminated. When the responsive function on the pacemaker was restored, the patient's electrocardiogram immediately showed pacemaker-mediated ventricular tachycardia with a rate of 140 beats/min (fig. 2). After the responsive function was disabled again, the electrocardiogram resolved to the patient's preprocedure rhythm at a rate of 70 beats/min. The patient was observed closely until there were no traces of myoclonic activity; then, the pacemaker was restored to its precardioversion settings once again, without any further disturbances in rhythm. The patient was subsequently noted to be feeling well and talking comfortably.

### Discussion

Although tachycardia, bradycardia, and other arrhythmias have occasionally been observed during induction and maintenance of anesthesia, there have been no published reports of etomidate-induced arrhythmias in patients with pacemakers. However, it is well known that adaptive-rate devices that sense vibration, impedance changes, or the QT interval may be triggered by mechanical or physiologic interference, leading to inappropriate high-rate pacing. This sensor-driven pacemaker-mediated tachycardia can be precipitated by such mechanical factors as direct pressure on the device (e.g., prone position), bone hammers and saws, or even a bumpy ride in a stretcher or hospital bed.<sup>6</sup> Postoperative shivering could also trigger this phenomenon.<sup>7</sup>

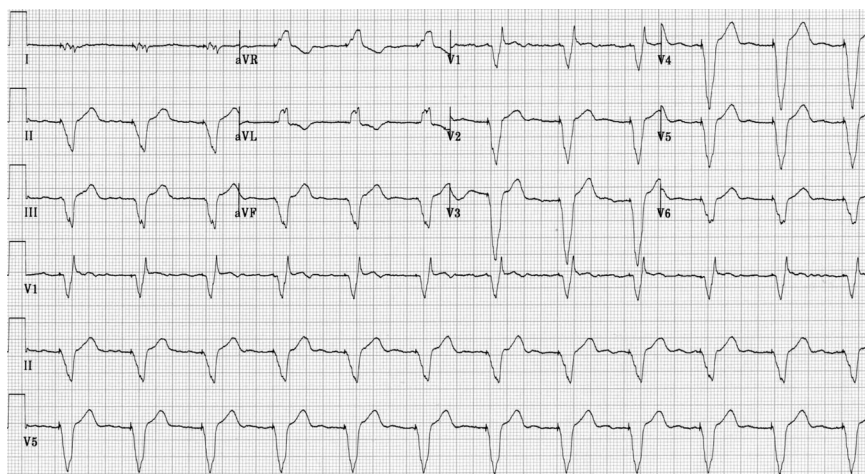
The most frequent adverse reaction associated with

\* Resident, † Assistant Professor.

Received from the Department of Anesthesiology and Perioperative Medicine, University Hospitals Case Medical Center, Cleveland, Ohio. Submitted for publication November 30, 2006. Accepted for publication January 10, 2007. Support was provided solely from institutional and/or departmental sources. Presented as a poster at the 10th International Congress of Cardiothoracic and Vascular Anesthesia with Industrial Exhibits, Prague, Czech Republic, August 27, 2006.

Address correspondence to Dr. Altose: Department of Anesthesiology and Perioperative Medicine, University Hospitals Case Medical Center, 11100 Euclid Avenue, Cleveland, Ohio 44106. michaelaltose@yahoo.com. Individual article reprints may be purchased through the Journal Web site, www.anesthesiology.org.





**Fig. 1.** The patient's baseline electrocardiogram showed atrial fibrillation with normal ventricle capture by the pacemaker at a rate of 70 beats/min.

use of intravenous etomidate (other than brief venous pain on injection) is transient skeletal muscle movements, including myoclonus. In our case, it is likely that the etomidate caused the patient's myoclonic activity, which then triggered the pacemaker's responsive function, leading to a ventricular paced rate of 140 beats/min, which is by definition ventricular tachycardia.

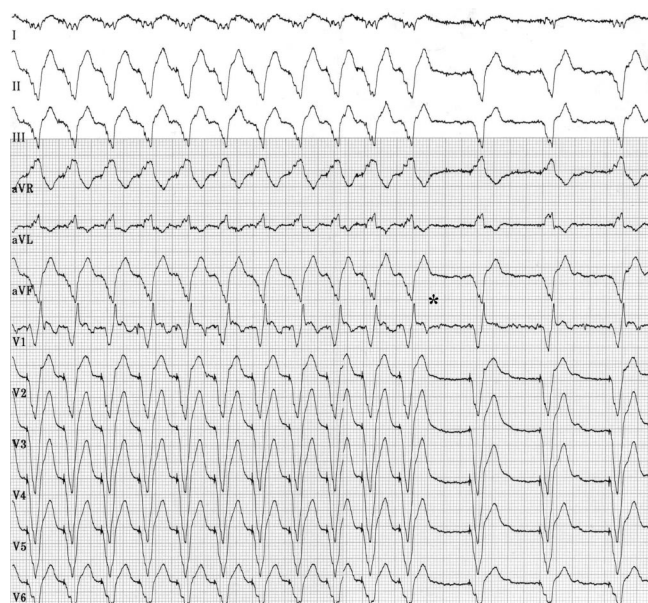
The effect we report here would be rare with most uses of etomidate because myoclonus has either resolved or been blocked by muscle relaxants before the end of the surgical procedure. Only in ultrashort cases such as cardioversion would there be a significant risk of postprocedural myoclonus. Given that several studies have demonstrated the utility and safety of etomidate for use during ambulatory external electrical cardioversion,

we can recommend two steps to minimize the incidence of this adverse effect in the future. First, the incidence of myoclonus associated with etomidate administration can be reduced by giving the drug as an infusion instead of an intravenous bolus. Second, premedicating the patient with a narcotic or benzodiazepine can minimize the occurrence of myoclonic activity.<sup>5</sup> However, these recommendations may not always be feasible in the context of the ambulatory setting, and the advantages and disadvantages must be considered.

There are several standard precautions that can help to minimize the incidence of any mechanically induced pacemaker-mediated tachycardia. It is essential that the pacemaker should be programmed to an asynchronous mode, preferably one that maintains atrial-ventricular sequence, especially in patients with impaired ventricular function.<sup>6</sup> We also stress the importance of carefully evaluating the patient for any signs of myoclonic activity before restoring the pacemaker to its responsive setting. Similarly, any other external mechanical disturbances must also be resolved before returning the device to normal operation. Following these recommendations may help to decrease the incidence of etomidate-induced or any other mechanically induced pacemaker-mediated ventricular tachycardia and allow for rapid and effective diagnosis and treatment of this rhythm.

## References

1. Herregods LL, Bossuyt GP, De Baerdemaeker LE, Moerman AT, Struys MM, Den Blauwen NM, Tavernier RM, Mortier E: Ambulatory electrical external cardioversion with propofol or etomidate. *J Clin Anesth* 2003; 15:91-6
2. Coll-Vinent B, Sala X, Fernandez C, Bragulat E, Espinosa G, Miro O, Milla J, Sanchez M: Sedation for cardioversion in the emergency department: Analysis of effectiveness in four protocols. *Ann Emerg Med* 2003; 42:792-7
3. Canessa R, Lema G, Urzua J, Dagnino J, Concha M: Anesthesia for elective cardioversion: A comparison of four anesthetic agents. *J Cardiothorac Vasc Anesth* 1991; 5:566-8
4. Hullander RM, Leivers D, Wingler K: A comparison of propofol and etomidate for cardioversion. *Anesth Analg* 1993; 77:690-4
5. Reves JG, Glass PSA, Lubarsky DA, McEvoy MD: Etomidate. *Anesthesia*, 6th edition. Edited by Miller RD. Philadelphia, Elsevier, 2005, pp 350-5
6. Atlee JL, Bernstein AD: Cardiac rhythm management devices: II. Perioperative management. *ANESTHESIOLOGY* 2001; 95:1492-506
7. Anand NK, Maguire DP: Anesthetic implications for patients with rate-responsive pacemakers. *Semin Cardiothorac Vasc Anesth* 2005; 9:251-9



**Fig. 2.** The patient's electrocardiogram showed pacemaker-mediated ventricular tachycardia at a rate of 140 beats/min. The rhythm returned to the preprocedure rate of 70 beats/min when the responsive function was disabled again, at the point indicated by the asterisk (\*).