

Unusual Cause of Postoperative Blindness

Tariq Chaudhry, M.D.,* Marc C. Chamberlain, M.D.,† Hector Vila, M.D.*

POSTOPERATIVE visual loss after nonophthalmic surgery is rare, with a reported incidence ranging from 0.01% to 1%. Most recently, perioperative visual loss associated with spine surgery prompted a Practice Advisory from the American Society of Anesthesiologists.¹ That advisory specifically focused on the most common causes during spine surgery, including ischemic optic neuropathy and central retinal artery occlusion. We report on an unusual case of postoperative blindness caused by basilar artery embolus during intraabdominal surgery.

Case Report

A 71-yr-old, 74-kg, female patient was scheduled to undergo exploratory laparotomy for a diagnosis of acute abdomen. She had a history of colon cancer, hypertension, and stable coronary artery disease, and a week previously, she had undergone an exploratory laparotomy to remove colon cancer. Her acute abdomen was presumed to be the result of bowel perforation.

Baseline laboratory work on the day of surgery, including a complete blood count and chemistry panel, was normal. A stress cardiac echo study performed 3 months previously showed a normal ejection fraction of 60%. An electrocardiogram showed normal sinus rhythm. Preoperative vital signs included blood pressure of 164/76 mmHg, heart rate of 116 beats/min, respiratory rate of 20 breaths/min, and temperature of 38.8°C.

Monitors included standard monitors, a radial artery catheter, and a Bispectral Index monitor. Anesthesia was induced using lidocaine, propofol, fentanyl, and rocuronium and was maintained with desflurane in air and oxygen. The patient was found to have a perforated cecum, and a wedge resection was performed. Blood pressure was stable during the entire case. Estimated blood loss was approximately 100 ml. She received a total of 2,900 ml crystalloid and 500 ml hetastarch over 4 h intraoperatively. Urine output was 200 ml. At the end of the case, the patient was taken to the recovery room and extubated approximately 3 h later when fully awake. After extubation, she was oriented to name and place and was aware of her surgery. She did not report anything unusual. She was transferred to the intensive care unit 70 min later.

More than 1 h after arriving in the intensive care unit, the patient casually reported being unable to differentiate between light and darkness since awakening from her operation. Examination revealed binocular vision loss. Given the uneventful operative and immediate

postoperative course, the patient's lack of anxiety, and the timing, a presumptive diagnosis of hysterical conversion reaction was made. Neurology consultation was obtained, confirming binocular loss of vision, and cranial magnetic resonance imaging was obtained (fig. 1). Review of the imaging revealed bilateral occipital lobe ischemia believed to be secondary to an embolic event and consistent with a posterior cerebral circulation stroke. Neurology recommended anticoagulation, and the patient received a heparin infusion. On the day after acute vision loss and on anticoagulation, the patient reported a modest improvement in her vision (able to distinguish between light and dark). A cardiac echo was obtained and ruled out the heart as a source of the embolic event. Magnetic resonance angiogram of the intracranial arteries demonstrated bilateral posterior cerebral artery occlusions.

The patient was diagnosed with posterior cerebral artery infarction due to basilar artery embolus with cortical blindness. At the time of discharge and on follow-up in the neurology clinic, the patient continued to improve and was left with a right homonymous hemianopsia as her only neurologic deficit.

Discussion

Visual loss after anesthesia for nonocular surgery is a devastating and fortunately uncommon event. In 1996, Roth *et al.*² reported that 34 of 60,965 (0.056%) patients sustained eye injuries after anesthesia. The most common injury was corneal abrasion, and only 1 patient had permanent blindness from ischemic optic neuropathy after spine surgery. In 2001, Warner *et al.*³ reported 405 cases of vision loss or changes after 501,342 anesthetics. Of these, only 4 patients (0.0008%) developed prolonged vision loss after nonophthalmologic or neurosurgical procedures. In 2003, a report from the American Society of Anesthesiologists Postoperative Visual Loss Registry on 79 cases of postoperative visual deficit after nonophthalmologic surgery revealed that the most common associations were spine operations (67%) and cardiac bypass procedures (10%).⁴ In the spine surgery cases, ophthalmologic diagnoses included ischemic optic neuropathy (81%) and central retinal artery occlusion (13%).

Postoperative visual loss caused by cortical infarction after routine noncardiovascular surgery is rare. Gelinas *et al.*⁵ reported a 51-yr-old woman who developed cortical blindness as a consequence of fat embolism during hip arthroplasty. There are also reports of cortical blindness in eclamptic obstetric patients.^{6,7} Amar *et al.*⁸ reported a case of cortical blindness as an iatrogenic consequence of subclavian artery surgery. We found no reports of cortical blindness after routine abdominal procedures.

* Assistant Professor of Anesthesiology and Interdisciplinary Oncology, † Professor of Interdisciplinary Oncology, University of South Florida College of Medicine.

Received from the Department of Interdisciplinary Oncology, University of South Florida College of Medicine, H. Lee Moffitt Cancer Center, Tampa, Florida. Submitted for publication November 1, 2006. Accepted for publication December 20, 2006. Support was provided solely from institutional and/or departmental sources.

Address correspondence to Dr. Vila: H. Lee Moffitt Cancer Center, Department of Interdisciplinary Oncology, University of South Florida College of Medicine, 12902 Magnolia Drive, Tampa, Florida 33612. vilah@moffitt.usf.edu. Individual article reprints may be purchased through the Journal Web site, www.anesthesiology.org.

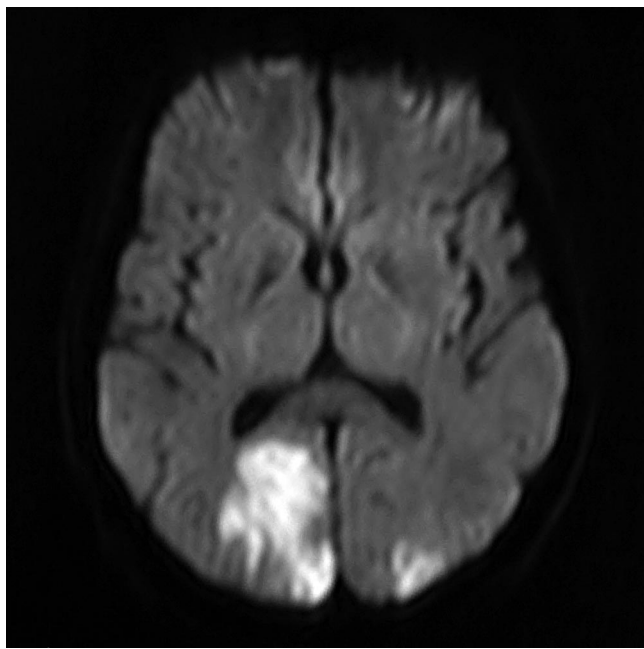


Fig. 1. Magnetic resonance image of head with abnormal diffusion signal in the occipital lobes bilaterally, characteristic of ischemia.

Basilar artery syndrome is a stroke syndrome affecting the basilar artery, brainstem arterial perforators, and posterior cerebral arteries. The basilar artery is the dominant artery in the posterior circulation of the brain, formed by confluence of both vertebral arteries. Embolic strokes predominate in the posterior circulation and, in particular, the posterior cerebral arteries. Atherosclerosis is less common in this location and predominantly affects the proximal and middle segments of the basilar artery. Posterior circulation stroke risk factors include elderly age, peripheral arterial disease, previous stroke or transient ischemic attack, hypertension, diabetes mellitus, hypercholesterolemia, hyperhomocysteinemia, coronary artery disease, and smoking. Herald symptoms include encephalopathy, brainstem syndromes, cortical blindness, gaze palsies, cranial neuropathies, and neurobehavioral disorders. The mortality rate varies and is a function of infarct volume.

Cortical blindness consists of complete loss of visual function including perception of light and dark due to injury to both occipital lobes. Cortical blindness is often associated with an encephalopathy, neurobehavioral abnormalities, and vertical gaze palsy. In most cases of cortical blindness due to ischemia, the associated encephalopathy is brief, after which the full extent of visual loss is often appreciated.

Diagnostic evaluation in a patient with a suspected embolic stroke is directed at possible embolic sources. These sources may be cardiac, aortic arch, or carotid or vertebral-basilar arteries, depending on whether an anterior or posterior circulation stroke has occurred. Cardiac sources are determined by history, electrocardiogram, and echocardiogram. Imaging studies include magnetic resonance imaging of the brain and magnetic resonance angiography of both extracranial and intracranial arteries. Magnetic resonance of the brain must include diffusion-weighted imaging because this sequence is most sensitive for early stroke detection. Computed tomography of the brain often underestimates ischemic stroke but is useful to exclude hemorrhagic stroke. In situations where a magnetic resonance angiography cannot be performed, *e.g.*, if a pacemaker is in place, computed tomographic angiography is an excellent substitute. Contrast angiography has an additional benefit as a therapeutic instrument for recanalization of the occluded artery.

Various treatment modalities have been suggested for patients with basilar artery syndrome, including treatment with thrombolytic agents (*i.e.*, prourokinase, streptokinase, and tissue plasminogen activator) given either intravenously or intraarterially. Patients should not be treated with thrombolytics if recent surgery has been performed, if they are taking anticoagulants, if more than 3 h have elapsed since stroke onset, or if there are large-volume ischemic changes on brain computed tomography (in the instance of middle cerebral infarcts). Anticoagulation with heparin or low-molecular-weight heparin has been advocated and used successfully.

References

1. American Society of Anesthesiologists Task Force on Perioperative Blindness: Practice advisory for perioperative visual loss associated with spine surgery: A report by the American Society of Anesthesiologists Task Force on Perioperative Blindness. *ANESTHESIOLOGY* 2006; 104:1319-28
2. Roth S, Thisted RA, Erickson JP, Black S, Schreider BD: Eye injuries after nonocular surgery: A study of 60,965 anesthetics from 1988 to 1992. *ANESTHESIOLOGY* 1996; 85:1020-7
3. Warner ME, Warner MA, Garrity JA, MacKenzie RA, Warner DO: The frequency of perioperative vision loss. *Anesth Analg* 2001; 93:1417-21
4. Lee LA: ASA Postoperative Visual Loss Registry: Preliminary analysis of risk factors associated with spine operations. *ASA Newsletter* 2003; 67:7-8
5. Gelinas JJ, Cherry R, MacDonald SJ: Fat embolism syndrome after cementless total hip arthroplasty. *J Arthroplasty* 2000; 15:809-13
6. Crosby ET, Preston R: Obstetrical anesthesia for a parturient with pre-eclampsia, HELLP syndrome and acute cortical blindness. *Can J Anaesth* 1998; 45:452-9
7. Della Sala S, Spinnler H: Anton's (Redlich-Babinski's) syndrome associated with Dide-Botcazo's syndrome: A case report of denial of cortical blindness and amnesia. *Schweiz Arch Neurol Psychiatr* 1998; 139:5-15
8. Amar AP, Levy ML, Giannotta SL: Iatrogenic vertebrobasilar insufficiency after surgery of the subclavian or brachial artery: Review of three cases. *Neurosurgery* 1998; 43:1450-7

Awareness without Recall during Anesthesia for Electroconvulsive Therapy

Lawrence Litt, Ph.D., M.D.,* Descartes Li, M.D.†

A RECENT publication reported recall of awareness during general anesthesia for electroconvulsive therapy (ECT).¹ We now report a case of awareness during anesthesia just before the ECT electroshock, but with no post-ECT recall.

Case Report

A 49-yr-old, 70-kg, otherwise healthy male inpatient presented for his fifth right unilateral ECT treatment. He was undergoing three ECT treatments each week for severe depression that was refractory to medical treatments, these including multiple previous antidepressant trials and hospitalizations. His history had three serious, documented suicide attempts, with psychotic features that included command auditory hallucinations to commit suicide. He had no history of substance abuse, except for a 30-yr history of one-pack-per-day cigarette smoking. His medications at the time of his fifth ECT treatment were as follows: venlafaxine extended-release, 75 mg daily; mirtazapine, 30 mg at bedtime; and hydroxyzine, 100 mg at bedtime. In the previous 12 months, he had been taking 2 mg clonazepam daily, with this being gradually tapered off over 2 weeks, with the final dose occurring 3 days before the fifth ECT treatment. At the time of the fifth ECT treatment, he had an improved affect and more energy, indicating that his depressive symptoms were already remitting.

In his four previous ECT treatments, an electroencephalographic seizure of approximately 30–41 s was produced. Patient recovery after earlier treatments was rapid and uneventful, with no complaints or complications. General anesthesia for his first four treatments consisted of an intravenous bolus injection of methohexital (80 mg), followed by an intravenous bolus injection of succinylcholine (80 mg), the latter being given immediately after the onset of unconsciousness (loss of eyelash response), and also after inflation of a lower right leg blood pressure cuff (arterial tourniquet) that prevented neuromuscular blockade in that extremity.

The same protocol and regimen was followed for the patient's fifth ECT treatment. After preoxygenation and administration of methohexital and succinylcholine, fasciculations were seen, and neuromuscular blockade was verified with a twitch monitor. ECT electrodes were applied to the patient's head, and the patient was hyperventilated *via* a mask and bag. However, it was then noticed that the patient made intermittent, erratic movements with his unparalyzed right foot. Concerned that the patient might be awake, we told the patient to stop moving his right foot. Somewhat to our surprise, his foot movement suddenly stopped. The patient was then told, "Move your right foot two times," which he did. We then appreciated that the patient was totally awake but pharmacologically paralyzed. This was verified by

repeated requests for foot motion, at which point we decided to assure the patient that he should not worry about breathing, that we would continue to ventilate him, and he just let us do this for him. We also apologized and explained that his waking up then was not part of our plan. We repeated assurances that he would soon regain his strength, which he did. After his total recovery from neuromuscular blockade we had an open discussion with the patient for approximately 10 min. He described being awake and paralyzed and not liking it, but he denied being fearful and expressed confidence in his doctors. He concluded by expressing a desire to continue the session and undergo his ECT treatment.

We began again with preoxygenation, but unconsciousness was induced with intravenous etomidate (12 mg) instead of methohexital. Succinylcholine (80 mg) was again used for neuromuscular blockade, and some mild clonic movements were seen in the unparalyzed right foot, but an unconscious state was verified by giving several commands and getting no response. A therapeutic seizure resulted from the ECT shock, which was followed by a rapid, uneventful recovery. The patient, who was questioned soon thereafter and again 2 h later, had no explicit memory of ever being awake and paralyzed, or of having two anesthesia inductions. An effort to evoke memories of the first induction was unsuccessful. We note that no other drugs, such as a benzodiazepine or narcotic, had been taken or administered. The patient subsequently underwent seven more ECT treatments without complications and with complete resolution of depressive symptoms.

Discussion

A recently published case report of an ECT patient having awareness during anesthesia described a patient who had an early morning treatment and was discharged to home within an hour.¹ Approximately 1 h after being home, the patient phoned the ECT therapist to report substantial displeasure with pre-electroshock awareness of neuromuscular blockade plus being hyperventilated and having a bite block placed in his mouth. The point of that report was to make sure that health professionals appreciate the possibility of ECT patient awareness during anesthesia. Specific drug dosages for ensuring unconsciousness were not recommended, which was appropriate because of the wide biovariability among patients of dose-response relations, and the need for titrating dosages for an optimum seizure response after the electroshock. However, a recommendation was made regarding postrecovery surveillance for awareness during anesthesia, this being done *via* questioning at different times.

Anesthesiologists and other physicians are increasingly being called upon to treat patients who are aware and cooperative, but incapable of recall, with the cause ranging from dementia to heavy premedication with a benzodiazepine. This raises ethical issues. To what extent

* Professor, Anesthesia Department, † Associate Clinical Professor, Psychiatry Department, University of California, San Francisco.

Received from the University of California, San Francisco, California. Submitted for publication December 15, 2006. Accepted for publication January 8, 2007. Support was provided solely from institutional and/or departmental sources.

Address correspondence to Dr. Litt: Anesthesia Department, Box 0648, Clinical Science Building C455, University of California, San Francisco, California 94143-0648. Larry.Litt@ucsf.edu. Individual article reprints may be purchased through the Journal Web site, www.anesthesiology.org.

should a physician allow discomfort if it is known that there will be no explicit memory of it? Is it appropriate to proceed with ECT in a paralyzed, awake, and psychologically stressed patient if one also knows that such will not be explicitly remembered? The medically correct answer is "no," because implicit memory, manifested by nonconscious behavioral changes, could potentially connect the psychological stress to subsequent harmful effects.² For example, implicit memory could manifest itself as an exaggerated autonomic response in a subsequent setting. Implicit memory, however, is difficult to objectively characterize and prove. Still, it is alleged to participate in the generation of post-traumatic stress disorder.² In addition, there are interesting studies that connect stress with chronic depression and related medications, with one prominent researcher having put forth medical evidence implicating chronic stress as a cause of chronic depression.³ If true, repeated inadequate anesthetics for ECT might potentially act oppositely to the therapeutic changes that ECT shocks are intended to create.

Our patient, in contrast to the one in the previous ECT case report, had documented awareness without recall. Given an aphorism of clinical medicine, that one finds only what one looks for, and recognizes only what one knows, our report suggests the importance of preshock vigilance during ECT procedures, this being done by asking the patient to respond to verbal commands to move distal limb muscles that have no neuromuscular blockade. Such should be discussed and rehearsed with

the patient before the procedure. It is noteworthy that currently available brain monitors, such as Aspect Medical Systems' BIS[®] Monitor (Newton, MA), although useful for predicting seizure duration,⁴ have great difficulty detecting awareness during complete neuromuscular blockade.⁵ Increased blood pressure and heart rate can suggest awareness before ECT shock. However, asking for response to commands would seem to be the most definitive test, just as one does at the anesthetic induction, before injecting succinylcholine and after injecting the hypnotic to produce unconsciousness. Because cardiovascular and psychological stress can come from being awake during neuromuscular blockade, we advocate "real-time," preshock vigilance to avoid this, because there might not be much help from the usual postoperative question: What is the last thing you remember from the period before you woke up?

References

1. Gajwani P, Muzina D, Gao K, Calabrese JR: Awareness under anesthesia during electroconvulsive therapy treatment. *J ECT* 2006; 22:158-9
2. Osterman JE, Hopper J, Heran WJ, Keane TM, van der Kolk BA: Awareness under anesthesia and the development of posttraumatic stress disorder. *Gen Hosp Psychiatry* 2001; 23:198-204
3. Sapolsky RM: Depression, antidepressants, and the shrinking hippocampus. *Proc Natl Acad Sci U S A* 2001; 98:12320-2
4. Ochiai R, Yamada T, Kiyama S, Nakaoji T, Takeda J: Bispectral index as an indicator of seizure inducibility in electroconvulsive therapy under thiopental anesthesia. *Anesth Analg* 2004; 98:1030-5
5. Messner M, Beese U, Romstock J, Dinkel M, Tschaikowsky K: The bispectral index declines during neuromuscular block in fully awake persons. *Anesth Analg* 2003; 97:488-91