

Loss of Transcranial Electric Motor Evoked Potentials during Pediatric Spine Surgery with Dexmedetomidine

Mohamed Mahmoud, M.D.,* Senthilkumar Sadhasivam, M.D.,* Anthony K. Sestokas, Ph.D., D.A.B.N.M.,†
Paul Samuels, M.D.,‡ John McAuliffe, M.D., M.B.A.‡

INTRAOPERATIVE neurophysiologic monitoring using transcranial electric motor evoked potentials (TcMEP) has been increasingly used to reduce the risk of spinal cord injury during corrective spine surgery. Because inhalational anesthetic agents considerably depress TcMEP amplitude in a dose-dependent manner,^{1,2} total intravenous anesthesia (TIVA) techniques with propofol as a central component have been advocated to optimize TcMEP monitoring during spine surgery.³ Because of its ability to decrease propofol requirements during TIVA, we often use dexmedetomidine, an α -2 agonist, as an adjunct to TIVA for procedures requiring TcMEP monitoring. We report two pediatric patients who experienced deterioration of TcMEP signal during the intraoperative use of dexmedetomidine.

Case 1

A 13-yr-old, 90-kg female patient with kyphoscoliosis presented for posterior spinal fusion with instrumentation of T2 to L3. Her medical history was significant only for obesity. After inhalation induction, intubation was facilitated with the administration of 100 μ g fentanyl and 100 mg propofol. TIVA was initiated immediately after intubation with 200 μ g \cdot kg⁻¹ \cdot min⁻¹ propofol, 0.5 μ g \cdot kg⁻¹ \cdot min⁻¹ remifentanyl, and 0.5 μ g \cdot kg⁻¹ \cdot h⁻¹ dexmedetomidine. No dexmedetomidine loading dose was given. One hour after starting TIVA (propofol, dexmedetomidine, and remifentanyl), the patient was placed in the prone position and baseline TcMEP was obtained (fig. 1). Motor evoked potentials were triggered using a Digitimer D-185 transcranial stimulator (Digitimer Ltd., Welwyn Garden City, UK) that delivered brief high-voltage stimulus trains through two subdermal needle electrodes placed over motor cortex representations at C1 and C2 (International 10-20 System). Triggered potentials were recorded from multiple sites in the lower extremities, including tibialis anterior and abductor hallucis muscles, as well as from first dorsal interosseous muscle in the hands as a control. Our standard monitoring protocol in these procedures included recordings of triggered compound muscle action potentials from abductor hallucis muscle to train-of-four electrical stimulation of the posterior tibial nerve for confirmation of adequate transmission across the neuromuscular junction (train of four =

4/4). Cervical/brainstem and cortical somatosensory evoked potentials (SSEP) to interleaved stimulation of the posterior tibial nerves also were recorded during the procedure, as were SSEPs to stimulation of the ulnar nerves. Neurophysiological signals were recorded using a commercially available neuromonitoring system (Axon Systems, Inc., Hauppauge, NY); baseline vitals were blood pressure 85/46 mmHg, heart rate 72 beats/min, end-tidal carbon dioxide 32 mmHg, and temperature 35°C. During the course of exposure over the next 1.5 h, TcMEP amplitude from upper and lower extremities gradually decreased in size and eventually disappeared after 2 h. By comparison, ulnar and posterior tibial nerve cortical SSEP amplitudes and latencies remained within baseline range, suggesting that the TcMEP changes did not reflect global iatrogenic injury to the spinal cord. The patient's vital signs at the time of TcMEP disappearance were as follows: blood pressure 95/50 mmHg, heart rate 66 beats/min, end-tidal carbon dioxide 38 mmHg, and temperature 35.2°C. The infusion rates of propofol, remifentanyl, and dexmedetomidine were 100 μ g \cdot kg⁻¹ \cdot min⁻¹, 0.5 μ g \cdot kg⁻¹ \cdot min⁻¹, and 0.5 μ g \cdot kg⁻¹ \cdot h⁻¹, respectively. The dexmedetomidine infusion was discontinued, and TcMEP reappeared within approximately 30 min, gradually increasing in size. There were no remarkable changes in the posterior tibial or ulnar nerve SSEP amplitudes throughout the period of TcMEP attenuation. Representative samples of motor and SSEPs recorded during dexmedetomidine infusion and after its cessation are shown in figure 1.

Case 2

A 19-yr-old, 62-kg male patient with kyphoscoliosis presented for anterior thoracic vertebrectomy, posterior decompression with instrumentation fusion with autologous bone graft. His medical history was significant for back pain. After intravenous induction with propofol 150 mg, fentanyl 100 μ g, cisatracurium 4 mg, and midazolam 2 mg, a double-lumen endobronchial tube was placed. TIVA was initiated with 150 μ g \cdot kg⁻¹ \cdot min⁻¹ propofol, 0.6 μ g \cdot kg⁻¹ \cdot h⁻¹ sufentanil, and 0.5 μ g \cdot kg⁻¹ \cdot h⁻¹ dexmedetomidine. A dexmedetomidine loading dose was not given before starting the infusion. Forty-five minutes after starting TIVA, the patient was placed in right lateral decubitus position; vital signs were blood pressure 89/59 mmHg, heart rate 61 beats/min, end-tidal carbon dioxide 38 mmHg, and temperature 35.6°C. At that time, the patient's baseline TcMEP was obtained. The neuromonitoring protocol was similar to that used in the previous case. One hour after obtaining the baseline TcMEP values, a bolus of 1 μ g/kg dexmedetomidine was administered over 10 min in an attempt to deepen the anesthetic level. At the completion of the bolus, blood pressure increased from 92/62 to 125/62 mmHg; heart rate remained unchanged. A significant decrease in TcMEP amplitude was noted approximately 10 min after the dexmedetomidine bolus. The propofol and sufentanil infusions remained unchanged from the start of the dexmedetomidine bolus until the TcMEP amplitude decreased. The dexmedetomidine infusion was continued at the same rate, and TcMEP amplitude gradually returned to baseline during the next 2 h. Representative samples of motor evoked potentials recorded before and after the bolus administration of dexmedetomidine are shown in figure 2. As in the previous case, cortical SSEPs did not show any remarkable amplitude changes during TcMEP amplitude attenuation.

* Assistant Professor in Clinical Anesthesia and Pediatrics, ‡ Associate Professor in Clinical Anesthesia and Pediatrics, Department of Anesthesiology, Cincinnati Children's Hospital Medical Center, Cincinnati, Ohio. † Staff Neurophysiologist, Surgical Monitoring Associates, Inc., Bala Cynwyd, Pennsylvania.

Received from the Department of Anesthesiology, Cincinnati Children's Hospital Medical Center, Cincinnati, Ohio. Submitted for publication June 15, 2006. Accepted for publication September 20, 2006. Support was provided solely from institutional and/or departmental sources.

Address correspondence to Dr. Mahmoud: Department of Anesthesiology, Cincinnati Children's Hospital Medical Center, 3333 Burnet Avenue, MLC 2001, Cincinnati, Ohio 45229. mohamed.mahmoud@cchmc.org. Individual article reprints may be purchased through the Journal Web site, www.anesthesiology.org.

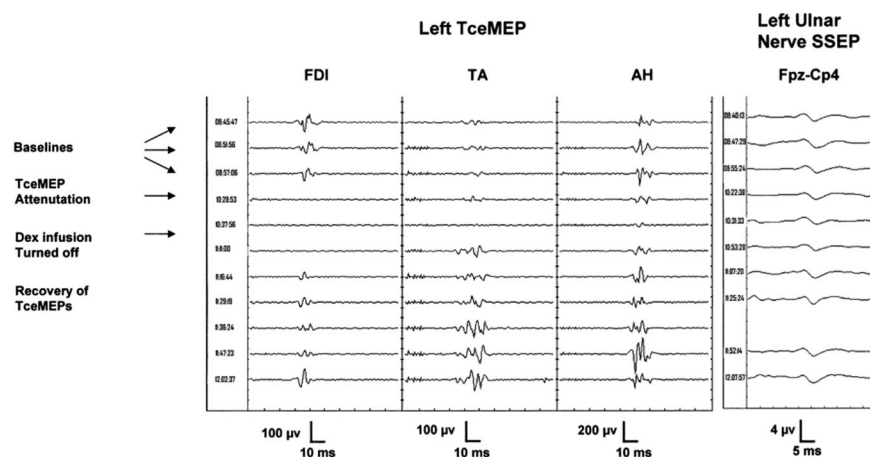


Fig. 1. Samples of transcranial electrical motor evoked potentials (TceMEP) recorded in case 1 from left first dorsal interosseous (FDI), tibialis anterior (TA), and abductor hallucis (AH) muscles 1 h after starting TIVA (Baselines), 1.5 h after acquisition of baselines (TceMEP Attenuation), and during a 2-h period after the infusion of dexmedetomidine (Dex) was stopped (Recovery of TceMEPs). Cortical somatosensory evoked potentials (SSEP) to stimulation of the left ulnar nerve recorded during the same time period as the TceMEPs are shown.

Discussion

Monitoring of descending corticospinal pathways using TceMEP has proven to be useful in potentially avoiding permanent neurologic deficits during corrective spine surgery. Most commonly used anesthetic drugs produce dose-related changes in the amplitude and latency of TceMEP. As a result, TIVA has been increasingly used during intraoperative neurophysiologic monitoring to provide adequate anesthesia with minimal interference of monitored neurophysiological signals. We often use dexmedetomidine as an adjunct to TIVA in procedures requiring intraoperative neurophysiologic monitoring (200-250 cases per year) because of its sedative, analgesic, and neuroprotective properties.⁴⁻⁶ Adding dexmedetomidine to our TIVA regimen enabled us to reduce infusion rates of propofol required to maintain adequate depth of anesthesia as judged by electroencephalographic spectral edge. Reducing the infusion rate of propofol in turn facilitated emergence from anesthesia for the intraoperative wake-up test (when requested) and at the completion of surgery. Dexmedetomidine was often continued into the postoperative period because of its ability to provide sedation and potentiate opioid analgesia with minimal additional respiratory depression.

When the amplitude of TceMEP was totally lost in the first case, we went through the following differential diagnosis: equipment failure, direct injury of the spinal cord, decreased spinal cord perfusion, and excessive doses of TIVA agents (propofol, remifentanyl, dexmedetomidine). Neuromonitoring equipment failure was ruled out as a possible explanation of signal loss given the gradual, progressive nature of TceMEP attenuation (and subsequent recovery) in the presence of verified constant voltage stimulus delivery, and given the continued ability to record SSEPs and electromyographic activity with the same monitoring equipment throughout TceMEP attenuation. In both cases 1 and 2, TceMEP recovered without any intervening adjustments to neuromonitoring equipment. Surgical manipulation of the spine was excluded as a likely cause, as there was generalized loss of TceMEPs, including those from the upper extremities with preservation of lower- and upper-extremity SSEPs (fig. 1). Spinal cord hypoperfusion as a result of decreased cardiac output seemed unlikely, as mean arterial pressures before and after loss of TceMEP fell within an acceptable range (55–62 mmHg). Excessive doses of TIVA agents were therefore believed to be the most likely reason for the loss of TceMEP amplitude. Remifentanyl has minimal effects on TceMEP even at high infusion rates.⁷ Although propofol infusion was relatively

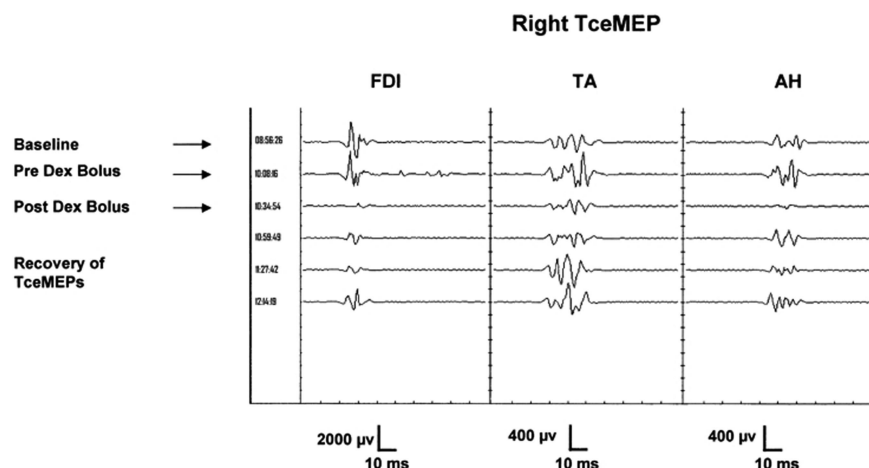


Fig. 2. Samples of transcranial electrical motor evoked potentials (TceMEP) recorded in case 2 from right first dorsal interosseous (FDI), tibialis anterior (TA), and abductor hallucis (AH) muscles 45 min after starting total intravenous anesthesia (Baselines), just before the bolus infusion of dexmedetomidine (Pre Dex Bolus), and during the subsequent 2-h period.

Predicted dexmedetomidine blood levels in relation to TcMEP signals

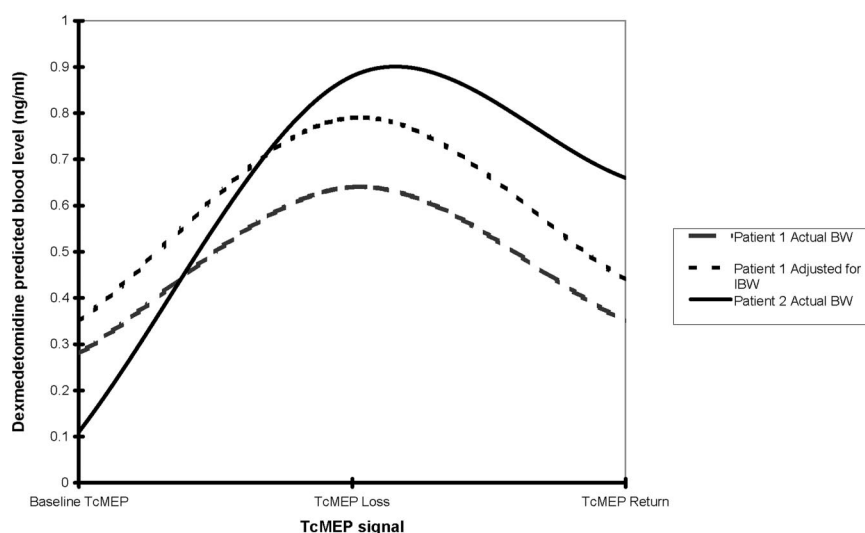


Fig. 3. Predicted blood levels of dexmedetomidine in relation to the amplitude of transcranial electric motor evoked potentials (TcMEP) signal in cases 1 and 2. BW = body weight; IBW = ideal body weight.

low ($100 \mu\text{g} \cdot \text{kg}^{-1} \cdot \text{min}^{-1}$) and the dexmedetomidine infusion fell within our usual range ($0.2\text{--}0.7 \mu\text{g} \cdot \text{kg}^{-1} \cdot \text{h}^{-1}$), both were calculated on actual rather than lean body mass. It is therefore possible that the patient had higher serum concentration of both drugs. We cannot exclude an interaction between propofol and dexmedetomidine as the explanation for the loss of TcMEP observed in this patient. We elected to discontinue the infusion of dexmedetomidine and continued to monitor the TcMEP. The gradual and progressive return of TcMEP signals 2 h after dexmedetomidine was discontinued, suggesting that excessive dexmedetomidine was responsible for the deterioration in TcMEP signal.

In the second patient, decreased TcMEP amplitude was noticed immediately after a bolus of dexmedetomidine, although the bolus was infused over 10 min to avoid the hypertension and bradycardia seen with rapid infusion of dexmedetomidine. Again, there was generalized attenuation of TcMEPs, including those from control muscle groups (upper extremity muscles), which suggested that surgical manipulation was not responsible. Mean arterial pressures in this patient also were well maintained during the episode, making it unlikely that the deterioration of TcMEP signal was due to a reduction in spinal cord perfusion.

Predicted concentrations of dexmedetomidine and propofol at acquisition of baseline TcMEP, loss or significant decrease of TcMEP signal, and recovery of TcMEP are shown in (figure 3 and table 1). Two sets of values of predicted serum concentrations are shown for patient 1; the first is based on actual body weight, and the second is based on the dosing weight proposed by Servin *et al.*⁸ (ideal + 0.4 times excess). The drug levels predicted based on actual body weight for patient 1 are well within the range in which authors have observed no changes in TcMEP amplitude relative to baseline in

nonobese patients. However, drug levels predicted based on adjusted body weight are at the upper limits of this range. The dexmedetomidine level predicted for patient 2 is also above the range for which no changes in TcMEP amplitude have been noted. The effects of dexmedetomidine on human TcMEP are not known; however, dexmedetomidine depresses rat TcMEP in a dose-dependent fashion. We believe that dexmedetomidine is the most likely cause for the loss of TcMEP amplitude in our first patient and the attenuation of TcMEP amplitude in our second patient. The persistence of cortical SSEPs in the presence of marked TcMEP attenuation suggests a differential effect of dexmedetomidine on the respective neural pathways that mediate these two signals. Action at the level of spinal cord interneurons or alpha motor neurons would be consistent with the observed differential effect of dexmedetomidine.

In conclusion, potential risks and benefits of adding dexmedetomidine should be assessed before its addition as an adjunct to TIVA in children. In addition, the intraoperative administration of a loading dose of dexmedetomidine before an infusion and/or dosing obese children with dexmedetomidine based on their actual body weight could

Table 1. Predicted Blood Concentrations of Propofol in Relation to TcMEP Measurements

	Patient 1			Patient 2		
	Baseline	Loss	Return	Baseline	Loss*	Return
Propofol ($\mu\text{g/ml}$)						
Actual BW	4.3	3.6	3.1	3.6	4.1	3.4
Adjusted BW	5.5	4.5	3.9			

* Transcranial electric motor evoked potential (TcMEP) was significantly reduced but not lost.

BW = body weight.

potentially affect TceMEP signals, especially with higher doses of propofol-based TIVA. Further studies on dose response effects of dexmedetomidine on the TceMEP are needed in children to confirm our anecdotal observations.

The authors thank Dr. Joel Gunter, M.D. (Professor of Anesthesiology, Cincinnati Children's Hospital Medical Center, Cincinnati, Ohio), for his constructive comments and valuable feedback. The authors also thank Andrew P. Warrington, E.C.N.E., C.N.I.M. (Staff Neurophysiologist, Surgical Monitoring Associates, Inc., Bala Cynwyd, Pennsylvania), who monitored the cases reported herein, and whose observations helped to establish the correlation between dexmedetomidine infusion and transcranial electric motor evoked potential attenuation.

References

1. Lieberman JA, Lyon R, Feiner J, Diab M, Gregory G: The effect of age on motor evoked potentials in children under propofol/isoflurane anesthesia. *Anesth Analg* 2006; 103:316-21
2. Lo YL, Dan YF, Tan YE, Nurjannah S, Tan SB, Tan CT, Raman S: Intraoperative motor-evoked potential monitoring in scoliosis surgery: comparison of desflurane/nitrous oxide with propofol total intravenous anesthetic regimens. *J Neurosurg Anesthesiol* 2006; 18:211-4
3. DiCindio S, Schwartz DM: Anesthetic management for pediatric spinal fusion: implications of advances in spinal cord monitoring. *Anesthesiol Clin North Am* 2005; 23:765-87
4. Jolkkonen J, Puurunen K, Koistinaho J, Kauppinen R, Haapalinna A, Nieminen L, Sivenius J: Neuroprotection by the alpha2-adrenoceptor agonist, dexmedetomidine, in rat focal cerebral ischemia. *Eur J Pharmacol* 1999; 372:31-6
5. Li BH, Lohmann JS, Schuler HG, Cronin AJ: Preservation of the cortical somatosensory-evoked potential during dexmedetomidine infusion in rats. *Anesth Analg* 2003; 96:1155-60
6. Hall JE, Uhrich TD, Barney JA, Arain SR, Ebert TJ: Sedative, amnestic, and analgesic properties of small-dose dexmedetomidine infusions. *Anesth Analg* 2000; 90:699-705
7. Scheufler KM, Zentner J: Total intravenous anesthesia for intraoperative monitoring of the motor pathways: an integral view combining clinical and experimental data. *J Neurosurg* 2002; 96:571-9
8. Servin FS, Bougeois B, Gomeni R, Mentre F, Farinotti R, Desmonts JM: Pharmacokinetics of propofol administered by target-controlled infusion to alcoholic patients. *ANESTHESIOLOGY* 2003; 99:576-85