

Nerve Puncture and Apparent Intraneural Injection during Ultrasound-guided Axillary Block Does Not Invariably Result in Neurologic Injury

Paul E. Bigeleisen, M.D.*

Background: Nerve puncture by the block needle and intraneural injection of local anesthetic are thought to be major risk factors leading to neurologic injury after peripheral nerve blocks. In this study, the author sought to determine the needle-nerve relation and location of the injectate during ultrasound-guided axillary plexus block.

Methods: Using ultrasound-guided axillary plexus block (10-MHz linear transducer, SonoSite, Bothell, WA; 22-gauge B-bevel needle, Becton Dickinson, Franklin Parks, NJ), the incidence of apparent nerve puncture and intraneural injection of local anesthetic was prospectively studied in 26 patients. To determine the onset, success rate, and any residual neurologic deficit, qualitative sensory and quantitative motor testing were performed before and 5 and 20 min after block placement. At a follow-up 6 months after the blocks, the patients were examined for any neurologic deficit.

Results: Twenty-two of 26 patients had nerve puncture of at least one nerve, and 21 of 26 patients had intraneural injection of at least one nerve. In the entire cohort, 72 of a total of 104 nerves had intraneural injection. Sensory and motor testing before and 6 months after the nerve injections were unchanged.

Conclusions: Under the conditions of this study, puncturing of the peripheral nerves and apparent intraneural injection during axillary plexus block did not lead to a neurologic injury.

ULTRASOUND is a useful aid for the performance of peripheral nerve block. Its use has resulted in a decreased incidence of vascular puncture, faster onset times, decreased dose requirements, and higher success rates.¹⁻⁴ The practice of ultrasound-guided nerve block is still evolving. Most practitioners continue to use a nerve stimulator even while performing the procedure under real-time viewing. There is also considerable debate about what the images mean. Most publications have shown a black (hypoechoic) local anesthetic ring around the nerve after injection is done (fig. 1). This is consistent with a nerve that is surrounded by a tissue

plane that is separated from the epineurium. Local anesthetic is injected into this potential space.

In the author's experience, as the needle touches the nerve, the nerve moves 1 or 2 cm before the needle pierces an anatomical structure that may be the fascia. As the needle pierces this anatomical structure/fascia, the practitioner may feel a pop, and the patient often reports a paresthesia or dysesthesia. Simultaneously, the needle seems to enter the substance of the nerve. Injection of 2-3 ml of local anesthetic usually proceeds with minimal pain and resistance. When compared with the undisturbed nerve (fig. 2A), the injected nerve seems to swell with a uniform stippled image and little or no black ring around it (fig. 2B). Some of the local anesthetic forms a black hypoechoic shadow in the nerve, and some of the local anesthetic leaks out of the nerve, forming a small hypoechoic ring around the nerve (fig. 2C). These observations are intriguing because they contradict the common assumptions that needle-nerve contact and intraneural injection are invariably associated with neurologic injury. A retrospective review of 50 ultrasound-guided blocks in the author's archive showed that one or more nerves in each patient was punctured and followed by an intraneural injection with local anesthetic. Because these patients did not experience any known sequelae, the author decided to perform a prospective study of his ultrasound-guided axillary blocks to determine the incidence of needle entry into the nerve as well as the images formed if local anesthetic was injected into the nerve. The author also studied any transient or permanent injuries to the nerves.

Materials and Methods

After institutional review board approval at Lindsay House Surgery Center and written patient consent, 50 American Society of Anesthesiologists physical status I-III patients who were older than 17 yr were enrolled in the study. All patients had previously consented to an ultrasound-guided axillary block for surgical repair of the basal joint of the thumb. An anesthesiologist with experience performing ultrasound-guided nerve blocks conducted the study. Before the performance of the block and before sedation, each patient was given a sensory and motor examination of the musculocutaneous nerve, median nerve, radial nerve, and ulnar nerve. The sensory examination was performed as follows: musculocutane-

This article is accompanied by an Editorial View. Please see: Borgeat A: Regional anesthesia, intraneural injection, and nerve injury: Beyond the epineurium. ANESTHESIOLOGY 2006; 105:647-8.

* Associate Professor.

Received from the Department of Anesthesiology, Lindsay House Surgery Center at Linden Oaks, Rochester, New York. Submitted for publication December 28, 2005. Accepted for publication April 19, 2006. Supported by Sleeping Gorilla Studios, Pittsford, New York.

Address correspondence to Dr. Bigeleisen: Department of Anesthesiology, University of Pittsburgh School of Medicine, 2300 Lothrop Street, C Wing, Room C-203, Pittsburgh, Pennsylvania 15213. bigeleisenpe@upmc.edu. Individual article reprints may be purchased through the Journal Web site, www.anesthesiology.org.

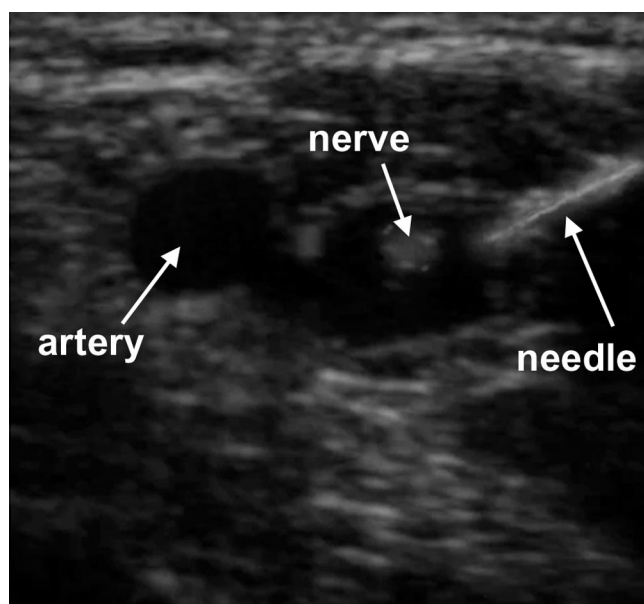


Fig. 1. Injection of local anesthetic around peripheral nerve.

ous nerve in the distribution of the lateral antebrachial nerve, median nerve in the palmar tip of the middle finger, radial nerve on the dorsum of the wrist proximal to the incision site, ulnar nerve in the palmar surface of the fifth finger. The following modalities were used: pinprick, alcohol wipe (cold), and a soft brush (light touch). A score of 1 was given if the patient could identify the modality, and a score of 0 was given if the patient could not identify the modality.

A qualitative muscular examination using the Medical Research Council Scale† (5 = full strength, 0 = no movement) was conducted by asking the patient to perform the following maneuvers: musculocutaneous nerve (flex forearm), median nerve (flex distal interphalangeal joint of second finger), radial nerve (extend wrist), ulnar nerve (abduct third and fourth fingers). Any patient who had deficiencies in any of the sensory or motor tests was excluded from the study. There were no other exclusionary criteria. A quantitative muscular examination was also conducted using grip strength and a force meter. With the forearm pronated and the wrist extended, the force meter was squeezed between the index finger and thumb. With the forearm supinated, the force meter was squeezed between the index finger and thumb. These maneuvers collectively test the median (index finger flexion), radial (wrist extension), and ulnar nerves (thumb apposition).

All axillary blocks were performed with the arm abducted 120°, the shoulder externally rotated, and the forearm flexed 90°. Patients received premedication with 1–2 mg midazolam and 50–100 µg fentanyl. A 22-gauge, short-bevel needle designed for nerve blocks (Becton Dickinson, Franklin Parks, NJ) was used for all injections. A 10-MHz linear transducer was sited in the axilla over the axillary artery. The axillary artery, vein,

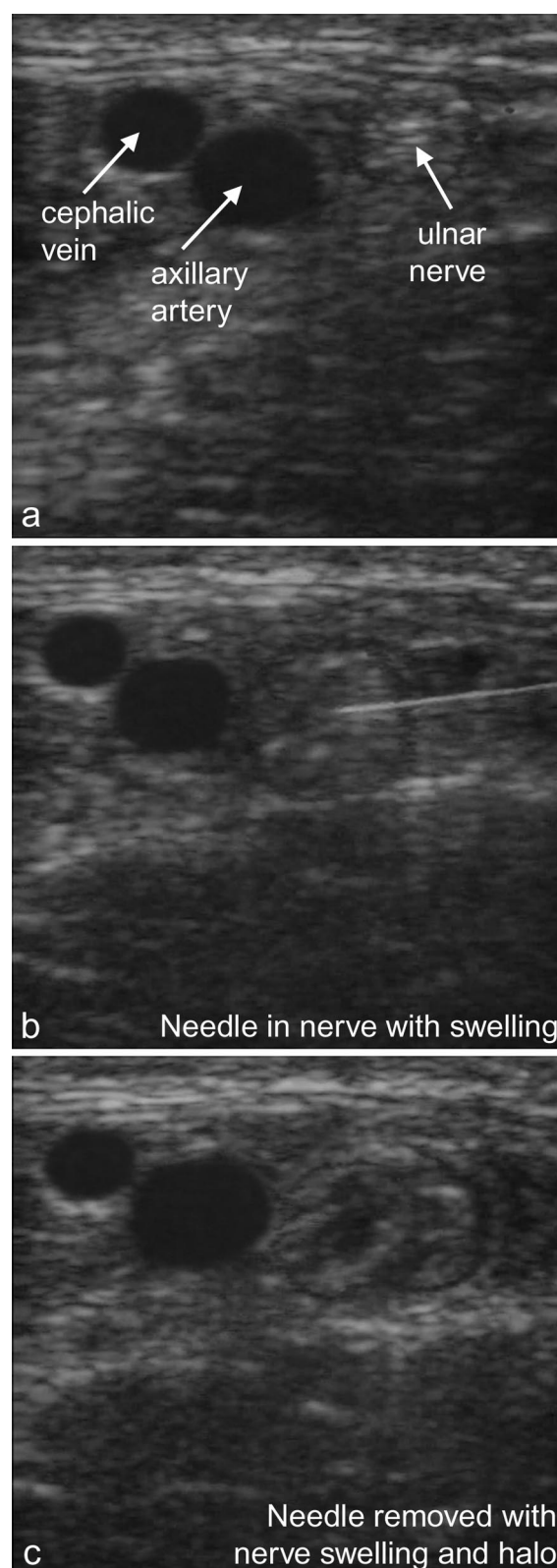


Fig. 2. Intraneural puncture and injection of peripheral nerve.

pectoralis major muscle, biceps muscle, and coracobrachialis muscle were identified on ultrasound. To the best of the author's ability, the musculocutaneous, median, ulnar, and radial nerves were also identified on ultra-

sound as well. Each nerve was anesthetized in the order described above by eliciting a paresthesia or piercing the fascia around the nerve by the sensation of a pop. After a paresthesia had been elicited or pop had been felt, 2–3 ml of anesthetic mixture (2.5 mg/ml bupivacaine, 10 mg/ml lidocaine, 3 μ g/ml epinephrine) was injected. If the injection appeared intraneural, the needle was withdrawn and 2–3 ml of local anesthetic mixture was injected around the nerve. If the initial injection produced a halo, an additional 2–3 ml of local anesthetic was injected around the nerve. If neither an intraneural injection nor a halo appeared, the process was repeated one more time with the exception of the musculocutaneous nerve. In the case of the musculocutaneous nerve, if neither an intraneural injection nor a halo could be achieved on the first injection, a total of 10 ml of local anesthetic was injected into the coracobrachialis muscle. The musculocutaneous and median nerves were anesthetized using an approach superior to the axillary artery. The ulnar and radial nerves were anesthetized using an approach inferior to the artery. The total dose of local anesthetic injected was recorded for each patient.

The ultrasound sequence was recorded on a digital recorder, and a nurse recorded the clinical activities of the author and patient response during the injections with a digital video recorder. The ultrasound tape and clinical video were then spliced together using Adobe Premiere (San Jose, CA) so that both ultrasound and clinical sequences could be viewed simultaneously. A licensed sonographer, trained in musculoskeletal imaging, reviewed each spliced tape to ascertain whether the needle appeared to enter the substance of the nerve during injection. The sonographer also noted whether the nerve appeared to swell, to become surrounded by a dark ring, or both. Finally, the sonographer noted whether the patient appeared to have a paresthesia or dysesthesia during the fascial puncture or injection by studying whether the patient moved or reported tingling or pain. Any occurrence of vascular puncture or hematoma formation was also tallied.

Qualitative sensory and muscle testing was repeated on each patient using the same maneuvers as described

Table 1. Mean Sensory Block at 5 and 20 Minutes

n = 26	Mu	M	R	U
5 min				
Sharp	0.2	0.4	0.3	0.3
Light touch	0	0.5	0.3	0.2
Cold	0	0.3	0.4	0.3
20 min				
Sharp	0	0.1	0	0.1
Light touch	0	0	0	0
Cold	0	0	0	0

M = median nerve; Mu = musculocutaneous nerve; R = radial nerve; U = ulnar nerve.

Table 2. Mean Motor Block at 5 and 20 Minutes

n = 26	Mu	M	R	U
5 min	1.1	2.7	2.2	2.3
20 min	0.1	0.2	0.1	0.2

5 = full strength, 0 = akinetic.

M = median nerve; Mu = musculocutaneous nerve; R = radial nerve; U = ulnar nerve.

above. These tests were repeated at 5 min, and 20 minutes after the block was completed by the author. The same examination, including quantitative muscle testing, was repeated at a follow-up visit 6 months after the patient's surgery. The 6-month follow-up examinations were performed by a nurse practitioner or physical therapist who was blinded to the results of the preoperative examinations. A tally was also made of the number of patients who reported surgical pain during the surgery or in the recovery room. Statistical analysis of quantitative strength was done using a one-sided *t* test. A value of 0.05 was assumed to be statistically significant. All patients were contacted 24–48 h after surgery to determine whether they had residual anesthesia in their surgical limb. They were also questioned about whether they had paresthesias, dysesthesias, weakness in the surgical limb, or pain at the injection site. All patients were seen within 96 h after the surgery, at 3 weeks, and again at 6 months by the surgeon. She was asked to report any abnormalities in the patients' sensory or motor examinations to the author.

Results

Twenty-two patients were excluded from the study because of preoperative abnormalities in their qualitative sensory or motor examinations. Two patients were lost to follow-up. The musculocutaneous and radial nerves were the easiest to block (tables 1 and 2). None of the patients reported surgical pain during the procedure, and all of the patients completed the surgery without local anesthetic supplementation by the surgeon or the need for general anesthesia. None of the patients required analgesia in the recovery room. All 26 patients who completed the study had normal qualitative sensory and motor examinations at 6-month follow-up. There was no significant difference in quantitative muscle testing preoperatively and at 6-month follow-up (table 3). The incidence of nerve puncture, halo around the nerve, nerve swelling, halo and nerve swelling, and paresthesias or dysesthesias are listed in table 4.

Table 3. Force Meter

n = 26	Supination	Pronation
Preoperatively, mean, kg	5.7 \pm 0.6	4.4 \pm 0.8
6 Months postoperatively, mean, kg	5.7 \pm 0.8	4.5 \pm 0.5

Table 4. Incidence of Nerve Puncture, Halo, Swelling, or Paresthesia

n = 26	Puncture	Halo	Swelling	Halo and Swelling	Paresthesia or Dysesthesia
Mu	8	18	5	3	4
M	22	4	4	18	23
R	23	3	3	20	24
U	19	7	1	18	15

M = median nerve; Mu = musculocutaneous nerve; R = radial nerve; U = ulnar nerve.

Puncture, intraneural injection, or halo around the musculocutaneous nerve did not produce any paresthesias or dysesthesias. Injection into the coracobrachialis muscle produced a paresthesia in 4 patients. Puncture of the median nerve produced a paresthesia or dysesthesia in 18 patients. In 15 patients, this paresthesia diminished during intraneural injection. In 3 patients, the paresthesia intensified during injection in to the median nerve. In 4 patients, puncture or injection of the median nerve did not produce any sensation. Halo alone of the median nerve produced a paresthesia when the nerve was initially contacted in 1 patient. Augmentation of the paresthesia occurred in this patient during injection. In 10 patients, puncture of the ulnar nerve produced a paresthesia or dysesthesia, which was diminished on intraneural injection. Halo alone produced a paresthesia in 5 patients during contact of the ulnar nerve. Three of these patients had a paresthesia or dysesthesia during injection around the ulnar nerve. Puncture of the radial nerve produced a paresthesia or dysesthesia in 21 patients. In 14 patients, this paresthesia diminished during intraneural injection. In 7 patients, the paresthesia increased with injection of the radial nerve. Halo alone produced a paresthesia or dysesthesia on radial nerve contact in 3 patients but no sensation during injection. Three patients reported tenderness at the injection site in the axilla on the day after surgery. This complication resolved by 3 weeks in all 3 patients without treatment. None of the patients reported paresthesias or dysesthesias in the distribution of the four injected nerves after surgery. The mean dose of local anesthetic used was 26 ± 12 ml (range, 17–45 ml). There were no vascular punctures or hematomas.

Discussion

The incidence of nerve puncture was lowest for the musculocutaneous nerve. This is most likely because the musculocutaneous nerve is the smallest in diameter and therefore the most difficult to puncture. The incidence of halo or swelling alone after injection was very low for all nerves. In most cases, there was both a halo and swelling because some of the local anesthetic infiltrated the nerve itself, whereas some of the local anesthetic

filled a potential space around the nerve. The absence of measurable neurologic injury (qualitative sensory and qualitative and quantitative motor testing) in any of the patients at 6-month follow-up suggests that neural puncture and or injection, *per se*, are not the immediate or most likely cause of neural injury after nerve block using the techniques described in this study. Unfortunately, the author did not have access to diagnostic electrophysiologic tools such as sensory nerve conduction thresholds, nerve conduction velocity, or electromyography, which may have added useful information to the study. It is also possible that the surgeon missed transient injuries in the early postoperative period, which may have resolved by the 6-month follow-up.

This study does not explain the cause of neural injury after nerve block, and the study was likely underpowered to elucidate the cause of neural injury because the incidence of nerve injury after neural block is so low.⁵ The large number of patients excluded from the study because of neurologic abnormalities also decreased the robustness of the study. Other mechanisms, however, may be the cause of neural injury. Ultrasound does not have the resolution to differentiate between injection into the stroma of the nerve or a fascicle of the nerve. Intrafascicular injection may be one cause of nerve injury. High injection pressure is also thought to be one cause of neural injury.⁶ Unfortunately, the author did not have the equipment to perform manometry. However, small aliquots of local were injected into or around the nerve; therefore, high injection pressure was less likely. In traditional nerve block techniques, the nerve is localized by paresthesia or electrolocation. When the nerve or plexus is located, many practitioners inject 30–40 ml of local anesthetic at one site. This is more likely to create a high pressure if the injection is intraneural. Finally, dysesthesia without motor deficit after a nerve block may be due to injury of the nervi nervorum, which innervate the epineurium and mesoneurium. If this is the mechanism of injury, puncture or injection of the epineurium may be the cause of injury. Again, this study does not have the spatial resolution to identify this type of injury.

Bevel type and needle gauge may also influence the incidence of nerve injury. In this study, we used a short-bevel, 22-gauge needle. One may not assume that needles of different gauge or with different bevel types, used in the same manner, will result in the same safety record. Inglis *et al.*⁷ found that conduction deficits occurred after individual axon impalement by microelectrodes. Finally, the type and location of the nerve may influence the way ultrasound-guided injections proceed. Nerves in the axilla have little or no fascia surrounding them and are frequently septated with large amounts of stroma between the fascicles (fig. 3). A blunt needle that pierces these small nerves may be less likely to puncture a fascicle. Moreover, these small nerves are freer to swell

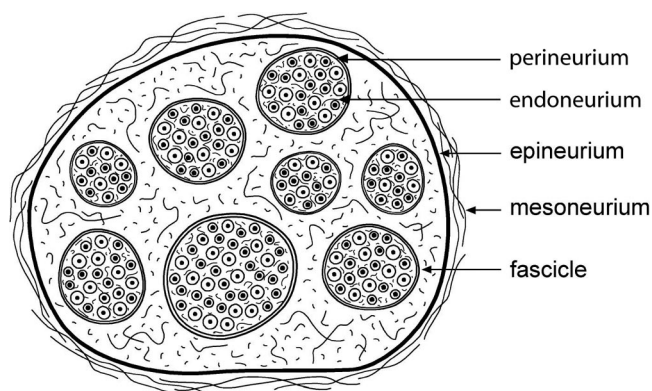


Fig. 3. Cross-section of peripheral nerve.

because they are not constrained by dense fascia. Finally, the cross section of a peripheral nerve is comprised of approximately 50% neurons and 50% fat and connective tissue.^{8,9} Thus, there is a significant probability of puncturing a peripheral nerve without contacting a fascicle or damaging the neurons. Case reports describe similar scenarios. Impalement of the femoral nerve under ultrasound guidance resulted in temporary injury,¹⁰ whereas the placement of a catheter within the sciatic nerve under computed tomography guidance did not cause any clinical injury.¹¹ These may be reasons why puncture and injection of small doses of local anesthetic into nerves did not cause injury. Nerve roots and nerve trunks have larger fascicles with virtually no intraneural stroma and are much more heavily invested with fascia.⁹ Injection into these structures, even with small doses of local anesthetic, may produce higher pressures and permanent injury.

In summary, the author has used ultrasound to study, in real time, the injection of local anesthetic during nerve block in the axilla. Nerves were frequently punctured and infiltrated with local anesthetic. This did not

seem to cause any long-term damage to the nerves under the conditions used in this study. Injection into the nerve after eliciting a paresthesia/dysesthesia produced a heterogeneous set of sensations. Sometimes the paresthesia/dysesthesia was augmented by injection, whereas in other instances, the paresthesia/dysesthesia was diminished or absent during intraneural injection. This study is underpowered to assert that intraneural injections or nerve puncture are inconsequential. However, these data and recent reports suggest that nerve puncture or intraneural injection does not inevitably lead to neurologic injury.

References

1. Marhofer P, Schrogendorfer K, Koinig H, Kapral S, Weinstabl C, Mayer N: Ultrasonographic guidance improves sensory block and onset time of three-in-one blocks. *Anesth Analg* 1997; 85:854-7
2. Marhofer P, Schrogendorfer K, Wallner T, Konig H, Mayer N, Kapral S: Ultrasonic guidance reduces the amount of local anesthetic for 3-in-1 blocks. *Reg Anesth Pain Med* 1998; 23:584-8
3. Sandu NS, Capan LM: Ultrasound-guided infraclavicular brachial plexus block. *Br J Anaesth* 2002; 89:254-9
4. Chan VWS: Applying ultrasound imaging to interscalene brachial plexus block. *Reg Anesth Pain Med* 2003; 28:340-3
5. Auroy Y, Benhamou D, Bagues L, Ecoffey C, Falissard B, Mercier F, Bouaziz H, Kamran S: Major complications of regional anesthesia in France: The SOS, Regional Anesthesia Hotline Service. *ANESTHESIOLOGY* 2002; 97:1274-80
6. Hadzic A, Dilberovic F, Shah S, Kulenovic A, Kapur E, Zaciragic A, Cosovic E, Vuckovic I, Divanovic KA, Mornjakovic Z, Thys DM, Santos AC: Combination of intraneural injections and high injection pressure leads to fascicular injury and neurological deficits in dogs. *Reg Anesth Pain Med* 2004; 29:417-23
7. Inglis JT, Leeper JB, Wilson LR, Gandevia SC, Burke D: The development of conduction block in single human axons following a focal nerve injury. *J Physiol* 1988; 518:127-33
8. Reina MA, Lopez A, De Andres JA: Adipose tissue within peripheral nerves: Study of human sciatic nerve [in Spanish]. *Rev Esp Anesthesiol Reanim* 2002; 49:397-402
9. Sunderland S: *Nerve Injuries and Their Repair: A Critical Appraisal*. New York, Churchill Livingstone, 1991, pp 31-40
10. Schafhalter-Zoppoth I, Gray AT: Inadvertent femoral nerve impalement and intraneural injection visualized by ultrasound. *Anesth Analg* 2004; 99:627-8
11. Sala-Blanch X, Pomes J, Matute P, Valls-Sole J, Carrera A, Tomas X, Garcia-Diez A: Intraneural injection during anterior approach for sciatic nerve block. *ANESTHESIOLOGY* 2004; 101:1027-30