

Reevaluation of Gray and White Matter Injury after Spinal Cord Ischemia in Rabbits

Naoko Kurita, M.D.,* Masahiko Kawaguchi, M.D.,† Meiko Kakimoto, M.D.,‡ Yuri Yamamoto, M.D.,§ Satoki Inoue, M.D.,‡‡ Mitsutoshi Nakamura, M.D.,|| Noboru Konishi, M.D.,# Piyush M. Patel, M.D., F.R.C.P.C.,** Hitoshi Furuya, M.D.††

Background: Although gray matter injury has been well characterized, the available data on white matter injury after spinal cord ischemia (SCI) in rabbits are limited. The current study was conducted to investigate the evolution of ischemia induced injury to gray and white matter and to correlate this damage to hind-limb motor function in rabbits subjected to SCI.

Methods: Thirty-eight rabbits were randomly assigned to 24-h, 4-day, or 14-day reperfusion groups or a sham group (n = 9 or 10 per group). SCI was induced by occlusion of the infrarenal aorta for 16 min. Hind-limb motor function was assessed using the Tarlov scale (0 = paraplegia, 4 = normal). The gray matter damage was assessed on the basis of the number of normal neurons in the anterior spinal cord. White matter damage was assessed on the basis of the extent of vacuolation and accumulation of amyloid precursor protein immunoreactivity.

Results: Tarlov scores gradually decreased and reached a nadir 14 days after reperfusion. There were no significant differences in the number of normal neurons among the 24-h, 4-day, and 14-day groups. The extent of vacuolation, expressed as a percent of total white matter area, was significantly greater in the 4-day and 14-day groups in comparison with the sham group. By contrast, there was no difference in vacuolation between the sham and 24-h groups. Amyloid precursor protein immunoreactivity was greater in the 4-day and 14-day groups.

Conclusion: The results in the current study show that SCI induced white matter injury as well as gray matter injury in a rabbit model of SCI. The time course for 14 days after reperfusion may differ among the gray and white matter damages and hind-limb motor function in rabbits subjected to SCI.

PARAPLEGIA remains a devastating complication of thoracoabdominal aortic operations, with the reported incidence ranging from 2.4% to 40%.¹⁻⁴ The mechanisms of postoperative paraplegia involve both acute ischemic and delayed reperfusion injury. Several attempts using hypothermia, cerebrospinal fluid drainage, *N*-methyl-D-aspartate receptor antagonists, calcium channel blockers, and free radical scavengers have been made to protect spinal cord against ischemic injury.^{2,5,6} However, because their efficacy is limited, a more detailed understanding of pathophysiologic mechanisms of spinal cord ischemic injury is needed.

In studies of ischemia-induced spinal cord injury, gray matter injury has been the primary focus as a target for therapy because of the traditional view that white matter is less vulnerable to ischemic injury compared with gray matter. Zivin *et al.*⁷ reported that spinal cord ischemia (SCI) induced necrosis of gray matter with little evidence of damage to the long white matter tracts in rabbits. Since that time, most published studies regarding SCI have assessed only neurologic function and the severity of histologic gray matter injury.⁸⁻¹⁰ However, recent evidence suggests that white matter injury is of equal importance to gray matter injury.¹¹⁻¹³ Follis *et al.*¹¹ demonstrated that white matter was more vulnerable to ischemia in comparison with gray matter in a rat model of SCI. The data from our laboratory have also shown that SCI induced white matter injury as well as gray matter injury 24 h after reperfusion in rats.¹⁴ Kanellouopoulos *et al.*¹³ suggested that evaluation of only gray matter injury may underestimate the extent of spinal cord injury and that the true extent of SCI may only be obtained with the assessment of both white and gray matter injury.

Methods for quantitative analysis of white matter damage, which include vacuolation and immunohistochemical analysis of damaged axons and oligodendrocytes, have only recently been established.¹³⁻¹⁶ Reevaluation of white matter injury after SCI in rabbits, with the use of these methods, would be therefore seem to be warranted. Such a reevaluation may well be necessary for a fuller understanding of the pathophysiology of SCI and may lead to novel therapeutic strategies to protect the spinal cord against ischemia. The current study was therefore conducted to evaluate the temporal changes in white and gray matter injury and to correlate this injury to hind-limb motor function in rabbits subjected to SCI.

Materials and Methods

The study was approved by the Animal Experiment Committee of Nara Medical University (Kashihara, Nara, Japan). Male New Zealand White rabbits were housed and maintained on a 12-h light-dark cycle with free access to food and water. All animals were neurologically intact before anesthesia and surgery.

Surgical Preparation

The rabbits were fasted overnight and were then anesthetized in a plastic box with 5% isoflurane in oxygen. Anesthesia was maintained with 2-3.5% isoflurane in

* Research Associate, † Associate Professor, ‡‡ Assistant Professor, § Research Fellow, †† Professor and Chair, Department of Anesthesiology, || Assistant Professor, # Professor and Chair, Department of Pathology, Nara Medical University. ‡ Chief Anesthesiologist, Department of Anesthesia, Uda City Hospital, Uda, Nara, Japan. ** Professor of Anesthesiology, Department of Anesthesiology, Veterans Affairs Medical Center and University of California, San Diego, California.

Received from the Department of Anesthesiology, Nara Medical University, Kashihara, Nara, Japan. Submitted for publication January 10, 2006. Accepted for publication April 10, 2006. Supported by Grant-in-Aid for Scientific Research C2-17591649 and C2-15591657, Tokyo, Japan.

Address correspondence to Dr. Kawaguchi: Department of Anesthesiology, Nara Medical University, 840 Shijo-cho, Kashihara, Nara 634-8522, Nara, Japan. drjkawa@naramed-u.ac.jp. Individual article reprints may be purchased through the Journal Web site, www.anesthesiology.org.

40% oxygen administered *via* a nonsealing facemask device. An ear vein catheter was inserted, and an infusion of normal saline at a rate of $10 \text{ ml} \cdot \text{kg}^{-1} \cdot \text{h}^{-1}$ was initiated. An ear artery was cannulated to monitor proximal mean arterial blood pressure. After infiltration with 1% lidocaine, the right femoral artery was exposed and cannulated with an SP-55 catheter for monitoring distal mean arterial blood pressure and for sampling arterial blood.

Spinal cord ischemia was induced as described previously.¹⁷ Briefly, a 5-cm left flank incision parallel to the spine was made at the 12th costal level after preparation of the skin with iodine and infiltration of 1% lidocaine. The retroperitoneal infrarenal aorta was exposed. A silicone string 1.5 mm in width was carefully placed around the aorta immediately distal to the left renal artery. Both ends of the silicone string were then passed through a rubber tube for occlusion of the aorta. After completion of the surgical preparation, 600 U heparin was administered intravenously.

Experimental Protocol

The rabbits were randomly allocated to one of the following four groups according to the duration of the reperfusion period: 24 h after ischemia (24-h group), 4 days after ischemia (4-day group), 14 days after ischemia (14-day group), or sham operation (sham group). SCI was produced by occlusion of the aorta by applying tension to the silicone string and clamping the rubber tube for a period of 16 min. Reperfusion of the spinal cord was achieved by removing the silicone string. Animals in the sham group underwent surgical preparation but were not subjected to SCI. Throughout the experiment, paravertebral muscle temperature was monitored by a needle-type thermistor and was servo-controlled at 38°C by using a water blanket. Proximal and distal mean arterial blood pressure and heart rate were monitored continuously and were recorded after surgical preparation (baseline), during ischemia, and 10 min after reperfusion. Arterial pressure of oxygen (PaO_2), arterial pressure of carbon dioxide (PaCO_2), pH, serum glucose, and hematocrit were measured after surgical preparation (baseline). After the final measurement was made, all vascular catheters were removed and wounds were sutured. Isoflurane was discontinued, and the animals were allowed to recover.

Neurologic Evaluation

At 3 h, 24 h, 4 days (only in the 4-day and 14-day groups), 7 days, and 14 days (only in the 14-day group) after the ischemic injury, the animals were assessed neurologically by blinded observers. Assessment was made using the Tarlov score,¹⁸ which consists of a five-point grading scale: 0 = paraplegic with no lower extremity function; 1 = poor lower extremity function, weak antigravity movement only; 2 = some lower ex-

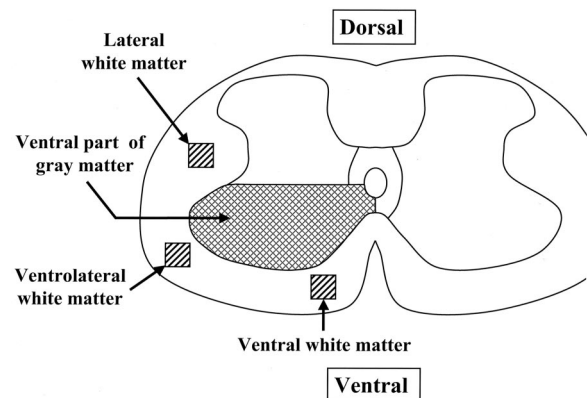


Fig. 1. Schema showing target areas for histologic assessment in the rabbit spinal cord (fifth lumbar segment). Gray matter damage was assessed by counting the number of normal neurons in the ventral part of gray matter (anterior to a line drawn through the central canal perpendicular to the vertical axis). White matter damage was evaluated by measuring areas of vacuolation in ventral, ventrolateral, and lateral white matter. Percentage of area of vacuolations was calculated at 200 \times magnification.

tremity motor function with good antigravity strength but inability to draw legs under body or hop; 3 = ability to draw legs under body and hop but not normally; 4 = normal motor function.

Histologic Evaluation

After scoring of neurologic function, the animals were anesthetized with 5% isoflurane in oxygen in a plastic box. Thiopental, 50 mg/kg, was administered by intraperitoneal injection. Transcardiac perfusion and fixation were performed with 1,000 ml heparinized cold saline solution followed by 500 ml buffered 3.7% formaldehyde. The lumbar spinal cord was removed and post-fixed in the same fixative for 1–2 days. After this period, the 5th lumbar spinal segment was dissected, embedded into paraffin and sectioned. Three micrometer sections were prepared and were stained with hematoxylin and eosin for quantitative evaluation.

Figure 1 shows the schema of target areas for histologic assessment in the rabbit spinal cord (fifth lumbar segment). The gray matter damage was evaluated by counting the number of normal neurons in the ventral part of gray matter (anterior to a line drawn through the central canal perpendicular to the vertical axis) with $\times 200$ magnification. Cells that contained Nissl substance in the cytoplasm, loose chromatin, and prominent nucleoli were considered normal neurons. The number of normal neurons of the right and left hemicords were then averaged. White matter injury was assessed by evaluating the extent of vacuolation in ventral, ventrolateral, and lateral white matter as reported previously.¹⁴ A grid with a dimension of 200 μm was placed on each white matter area. The grid was separated into 144 squares. The squares in which more than 75% of the area was vacuolated were counted as being areas of white matter injury with $\times 200$ magnification. Percentage of areas of

Table 1. Hemodynamic Parameters in the Experimental Groups

	Sham (n = 9)	24 h (n = 10)	4 days (n = 9)	14 days (n = 10)
Baseline				
Proximal MAP, mmHg	67 (15)	60 (8)	59 (9)	68 (9)
Distal MAP, mmHg	75 (15)	66 (10)	67 (7)	75 (8)
Heart rate, beats/min	279 (19)	279 (24)	269 (26)	276 (19)
Paravertebral temperature, °C	37.9 (0.5)	38.1 (0.6)	37.8 (0.4)	38.1 (0.4)
Ischemia				
Proximal MAP, mmHg		61 (11)	66 (7)	69 (9)
Distal MAP, mmHg		11 (2)	12 (2)	12 (2)
Heart rate, beats/min		276 (23)	278 (17)	279 (18)
Paravertebral temperature, °C		37.8 (0.5)	37.8 (0.4)	37.9 (0.3)
10 min after ischemia				
Proximal MAP, mmHg	62 (18)	57 (12)	58 (4)	62 (6)
Distal MAP, mmHg	71 (17)	68 (14)	65 (6)	66 (8)
Heart rate, beats/min	270 (27)	272 (23)	279 (19)	266 (22)
Paravertebral temperature, °C	38.2 (0.3)	38.2 (0.3)	37.9 (0.4)	38.1 (0.1)

Data are expressed as mean (SD).

MAP = mean arterial pressure.

vacuolation of total target area (0.04 mm^2) were calculated. The percentage areas of vacuolation in the ventral, ventrolateral, and lateral areas of white matter in both sides (total six areas) were then averaged.

Adjacent sections were immunostained with amyloid precursor protein (APP) antibody (Clone 6E10; Chemicon, Temecula, CA) to label injured axons using the streptavidin-biotin method (Histofine SAB-PO (M) Kit, Nichirei Corp., Tokyo, Japan). Briefly, sections were deparaffinized and pretreated for antigen retrieval by a microwave oven in a citric acid buffer (10 mM; pH 6.0) for 10 min for immunostaining, allowed to cool to room temperature, and rinsed in phosphate-buffered saline. To block endogenous peroxidase, they were incubated in 3% hydrogen peroxide in methanol for 30 min, rinsed in phosphate-buffered saline, and incubated again with normal rabbit serum for 10 min. Thereafter, the sections were rinsed and incubated at 4°C overnight with the primary mouse monoclonal antibody against APP diluted 1:100 in normal rabbit serum. The next day, sections were rinsed again and were exposed to a biotin-labeled rabbit anti-mouse immunoglobulin (Ig) G/IgA/IgM mixture for 5 min at room temperature, followed by streptavidin for 5 min. Antigen-antibody complex was visualized with 3,3'-diaminobenzidine (DAB; Nichirei Corp., Tokyo, Japan). At the end of the procedure, the sections were lightly counterstained with hematoxylin, dehydrated in graded concentrations of alcohol, and cleared in xylene before being coverslipped for microscopic examination. Negative controls for immunostaining were performed by omitting the primary antibody. APP immunoreactivity was assessed in the areas of ventral, ventrolateral, and lateral white matter as mentioned above. To assess the APP immunoreactivity, a score of 0 (no APP accumulation) or 1 (APP accumulation in axonal swellings) was assigned to each area, and the total score (average of both sides) in each animal was calculated

(from 0 to 3). Investigators without knowledge of the injury models (sham or ischemia) performed the histologic assessment of the gray and white matter injury.

Statistical Analysis

Differences in physiologic variables, the number of normal neurons, and percentage area of vacuolation were assessed using one-way analysis of variance; when significant differences were identified, the Student-Newman-Keuls test was performed for intergroup comparisons. Tarlov scoring and APP score were analyzed by the Kruskal-Wallis test followed by the Mann-Whitney U test with Bonferroni correction for intergroup comparisons. To determine the relation between the number of normal neurons and percentage area of vacuolation, linear regression analysis was performed. To determine relation between Tarlov scoring and the number of normal neurons or percentage area of vacuolation, the Spearman correlation analysis was performed. A *P* value less than 0.05 was considered statistically significant. Physiologic variables, the number of normal neurons, and percentage area of vacuolation are expressed as mean \pm SD, and Tarlov scoring and APP score are expressed as median with interquartile range in parentheses.

Results

Forty-four animals were randomly allocated to each group. Because 1 of 11 animals in the 24-h group, 1 of 10 animals in the 4-day group, and 4 of 14 animals in the 14-day group died before the final assessments, final analysis was performed in 38 animals. Hemodynamic parameters are shown in table 1. There were no significant differences in proximal mean arterial pressure, distal mean arterial blood pressure, heart rate, and paravertebral temperature before ischemia (baseline). During ischemia, there were no significant differences in

Table 2. Physiologic Variables in the Experimental Groups

	Sham (n = 9)	24 h (n = 10)	4 days (n = 9)	14 days (n = 10)
Baseline				
Paco ₂ , mmHg	44 (12)	37 (7)	41 (11)	39 (6)
Pao ₂ , mmHg	216 (39)	211 (33)	201 (21)	200 (32)
Hematocrit, %	41 (1)	41 (2)	40 (3)	39 (2)
Glucose, mg/dl	158 (72)	135 (36)	142 (19)	147 (25)
10 min after ischemia				
Paco ₂ , mmHg	42 (13)	33 (11)	37 (7)	39 (11)
Pao ₂ , mmHg	207 (38)	214 (35)	208 (14)	197 (21)
Hematocrit, %	41 (2)	40 (4)	38 (3)	38 (3)
Glucose, mg/dl	163 (74)	148 (46)	153 (39)	157 (37)

Data are expressed as mean (SD).

Paco₂ = arterial partial pressure of carbon dioxide; Pao₂ = arterial partial pressure of oxygen.

distal mean arterial blood pressure values among the three ischemic groups. After reperfusion, all parameters were similar among the groups. Blood gas data are shown in table 2. There were no significant differences in Paco₂, Pao₂, hematocrit, and glucose before or after ischemia among the groups.

Median values (25th–75th) of Tarlov scoring in all animals are shown in table 3. Tarlov scores gradually decreased over the recovery period and reached a median score of 0 at 14 days. Tarlov scores at 3 h, 24 h, 4 days, 7 days, and 14 days after ischemia were significantly lower compared with those in the sham group. Tarlov scores at 14 days after ischemia were significantly lower compared with those at 3 h after ischemia.

The number of normal neurons in the three ischemic groups was significantly lower compared with that in the sham group (mean ± SD: 24 ± 22, 11 ± 14, and 12 ± 9 vs. 45 ± 8, respectively; $P < 0.05$; fig. 2). There were no significant differences in the number of normal neurons among the ischemic groups. The relation between Tarlov scoring and the number of normal neurons is shown in figure 3. There was a significant positive correlation between Tarlov scores and the number of normal neurons ($r = 0.678$; $P < 0.0001$).

Figure 4 shows the results of white matter injury. The percentage areas of vacuolation in the 4-day and 14-day groups were significantly higher compared with those in the 24-h group and the sham group ($P < 0.05$). There was no significant difference in the percentage areas of vacuolation between the sham group and the 24-h group. Representative photomicrographs of hematoxy-

Table 3. Tarlov Scoring after Spinal Cord Ischemia for 16 Minutes

	Sham (n = 9)	3 h (n = 28)	24 h (n = 28)	4 days (n = 18)	7 days (n = 10)	14 days (n = 10)
Median (25th–75th)	4 (4–4)	2* (0–3)	1* (1–1.5)	1* (1–1)	0.5* (0–2)	0*† (0–1)

Data are expressed as median (interquartile range). Hind-limb motor function was assessed using Tarlov scoring (0 = paraplegic with lower extremity function; 1 = poor lower extremity function, weak antigravity movement only; 2 = some lower extremity motor function with good antigravity strength but inability to draw legs under body or hop; 3 = ability to draw legs under body and hop but not normally; 4 = normal motor function).

* $P < 0.05$ vs. sham. † $P < 0.05$ vs. 3 h.

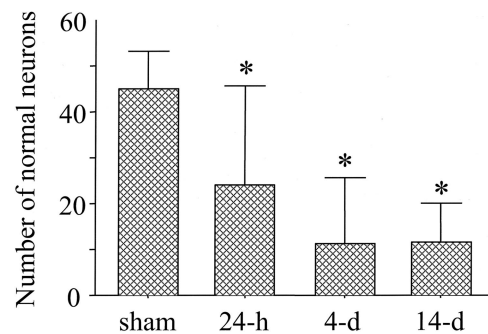


Fig. 2. Numbers of normal neurons in the experimental groups. The numbers of normal neurons in the ischemic three groups were significantly lower in comparison with the sham group ($P < 0.05$). There were no significant differences in the numbers of normal neurons among the ischemic groups. Data are expressed as mean ± SD. * $P < 0.05$ versus sham.

lin and eosin-stained sections in the ventrolateral white matter are shown in figure 5. Vacuolation was not noted in the sham group, whereas vacuolation was seen in the ventrolateral white matter in the 4-day and 14-day groups. The relation between Tarlov scoring and the extent of vacuolation is shown in figure 6. There was a significant negative correlation between Tarlov scoring and vacuolation areas ($r = -0.631$, $P = 0.0001$). Figure 7 shows the relation between the number of normal neurons and percentage areas of vacuolation. A significant negative correlation was noted between the number of normal neurons and the percentage of vacuolation areas ($R^2 = 0.354$, $P < 0.0001$).

Immunohistochemical analysis revealed that APP immunoreactivity was concentrated within axon bundles in the ventral, ventrolateral, and lateral white matter predominantly in the 4-day and 14-day groups, whereas APP immunoreactivity was not noted in the sham group. Representative photomicrographs of APP immunohistochemistry in the ventrolateral region of white matter are shown in figure 5. Median values of APP scores (25th–75th) in the sham, 24-h, 4-day, and 14-day groups were 0 (0–0), 0 (0–0), 1.5 (0.9–2.5), and 1.8 (1.5–2.5), respectively. APP scores in 4-day and 14-day groups were significantly higher than those in 24-h and sham groups ($P < 0.05$; fig. 8).

Discussion

In the current study, hind-limb function deteriorated over a recovery period of 14 days in rabbits subjected to

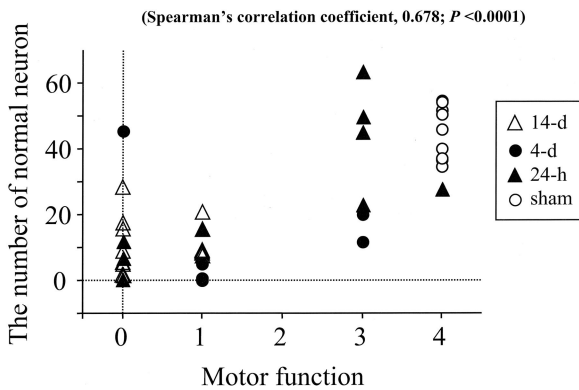


Fig. 3. Relation between hind-limb motor function and the number of normal neurons. Hind-limb motor function was assessed just before the reperfusion using Tarlov scoring, which consists of a five-point grading scale: 0 = paraplegic with no lower extremity function; 1 = poor lower extremity function, weak antigravity movement only; 2 = some lower extremity motor function with good antigravity strength but inability to draw legs under body and hop but not normally; 4 = normal motor function. Open circle, closed triangle, closed circle, and open triangle indicate the animals in the sham, 24-h, 4-day, and 14-day groups, respectively. There was a significant positive correlation between motor function and the number of normal neurons (Spearman correlation coefficient, 0.678; $P < 0.0001$).

16 min of SCI. Gray matter injury, assessed by counting the number of normal neurons in the anterior spinal cord, was observed 24 h after ischemia and was maximal at 4 days after ischemia. By contrast, white matter injury, assessed by measuring the extent of vacuolation and APP immunoreactivity, was not observed 24 h after ischemia but was prominent at 4 and 14 days later. These results indicate that the temporal progression of injury in the gray and white matter differed, with a progression apparent in the latter but not in the former. As such, the data are consistent with the premise that both gray and white matter injury contribute to progression in neurologic deterioration that was apparent in the animals subjected to SCI.

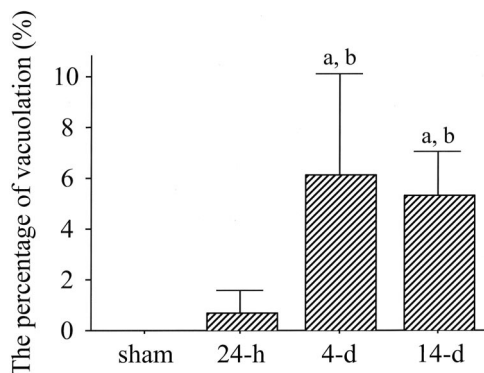


Fig. 4. Percentage areas of vacuolation in the white matter in the experimental groups. The percentage area of vacuolation in the 4-day and 14-day groups was significantly higher than in the 24-h group and sham group ($P < 0.05$). There was no significant difference in the percentage area of vacuolation between sham group and the 24-h group. Data are expressed as mean \pm SD: $P < 0.05$ versus sham, b: $P < 0.05$ versus 24-h

Since Zivin and DeGirolami⁷ reported in 1980 that a rabbit SCI model with infrarenal aortic occlusion was highly reproducible, a number of investigators have used this model for the assessments of spinal cord ischemic injury. In the rabbit, the spinal cord is susceptible to ischemic injury after infrarenal aortic occlusion because the lumbar and sacral portions receive a majority of their blood flow from segmental vessels that originate from the abdominal aorta. In most of these studies, only gray matter has been assessed as a target for therapy.^{8,10,17} This is probably because Zivin and DeGirolami⁷ originally reported in 1980 that occlusion of abdominal aorta induced necrosis of gray matter with relative sparing of white matter throughout the lumbar and sacral cord. They demonstrated that there is a total loss of the myelinated fibers in the gray matter and little evidence of damage to the long white matter tracts. However, in their study, extensive assessments of white matter injury were not performed because of the lack of established techniques.

Recently, techniques for the assessment of white matter injury have been developed in models of cerebral and spinal cord ischemic injury. Of these, vacuolation and accumulation of APP immunoreactivity have been used to assess white matter injury. Kanellopoulos *et al.*¹³ evaluated gray and white matter injury after SCI in rats. In the white matter, vacuolation was widespread and was prominent in the ventral and ventrolateral white matter at 2 days after ischemia, and at 6 weeks after the injury, losses of 47% and 58% of axons in the ventral and ventrolateral white matter areas, respectively, were noted. Follis *et al.*¹¹ investigated the effects of SCI on gray and white matter injury in rats and demonstrated that paraplegic animals had myelin vacuolation and an increased number of macrophages in the anterior and lateral columns; white matter injury was observed with or in the absence of injury to the gray matter. Data from our laboratory have also shown that SCI results in vacuolation in the ventral and ventrolateral areas of white matter as well as a reduction in the number of normal neurons 24 h after ischemia in rats.¹⁴ In a model of focal cerebral ischemia, Pantoni *et al.*¹⁹ evaluated the white matter injury using light and electron microscopy in rats and demonstrated that vacuolation and pallor of the white matter were marked after ischemia. This reflected a segmental swelling of myelinated axons, the formation of spaces between myelin sheaths and axolemma, and astrocyte swelling.

Because APP is transported by fast anterograde axonal transport, the accumulation of APP at sites of injury, accompanied by morphologic evidence of axonal damage in the form of axonal swelling or bulbs, has been regarded as evidence of axonal injury. For the detection of axonal injury, APP accumulation has been used in the models of cerebral ischemia^{15,16,20} and spinal cord injury.²¹ Several investigators have reported that damaged

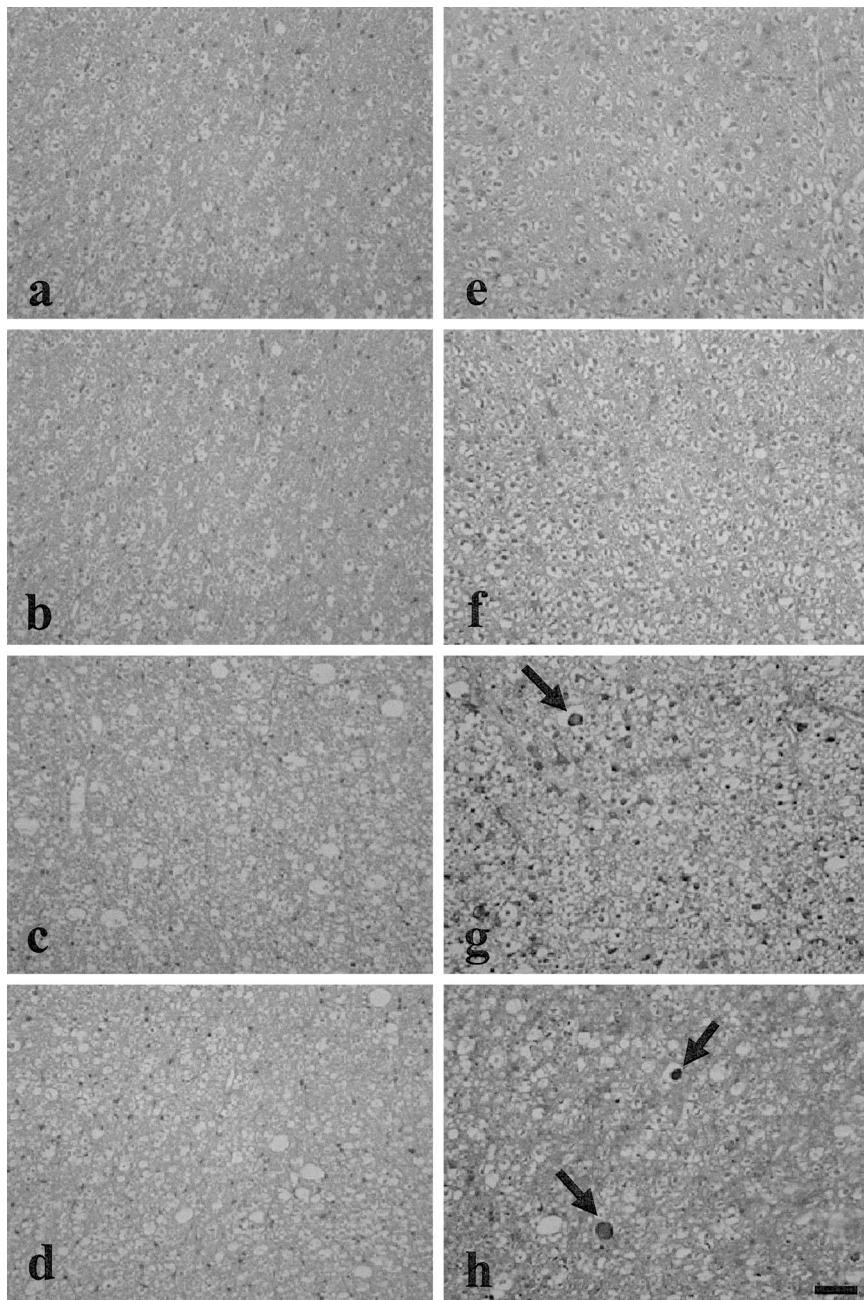


Fig. 5. Representative photomicrographs of hematoxylin and eosin-stained sections (A, B, C, D) and amyloid precursor protein immunohistochemistry (E, F, G, H) in the ventrolateral white matter. Animals received the sham operation (A, E) or reperfusion for 24 h (B, F), 4 days (C, G), or 14 days (D, H) after 16 min of spinal cord ischemia. Vacuolation was not noted after the sham operation (A), whereas vacuolation was widespread and prominent in the ventrolateral white matter 4 days (C) and 14 days (D) after reperfusion. Amyloid precursor protein immunoreactivity (arrows) was apparent in the regions of axon bundles in the ventrolateral white matter predominantly 4 days (G) and 14 days (H) after reperfusion, whereas amyloid precursor protein immunoreactivity was not noted after the sham operation (E). Scale bar = 50 μ m.

axons have a bulbous or swollen appearance with increased APP immunoreactivity within subcortical white matter and myelinated fiber tracts after focal cerebral ischemia in rats.^{15,20} Westergren *et al.*²¹ indicated that APP accumulation was noted in the swollen axons in the white matter 24 h after spinal cord compression injury in rats. Our previous report showed the increased APP immunoreactivity in the swollen axons in rats with SCI, in which prominent vacuolations were noted by the hematoxylin and eosin-stained sections.¹⁴ Collectively, the available evidence indicates that APP accumulation is a sensitive indicator of axonal injury.

In the current study, we demonstrate the findings of vacuolation and APP accumulation 4 and 14 days after

SCI as white matter injury. These results are discordant with those reported by Zivin *et al.*⁷ Although the reasons for this are unknown, the differences in methodology for white matter injury evaluation probably underlie this discrepancy. In the study by Zivin *et al.*, myelin staining with the Loyez/Heidenhain-Woelke method was used to qualitatively evaluate white matter injury without any quantitative analysis. In contrast, we quantitatively analyzed white matter injury based on the methodologies reported recently.¹⁴ Of interest is that white matter injury was prominent 4 days and 14 days but not 24 h after SCI in rabbits. White matter injury after SCI seems to be delayed in rabbits. This differs from the findings in rats, in which white matter injury was noted even 24 h after

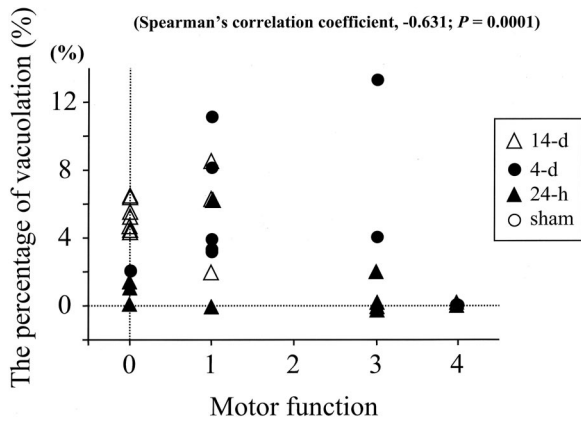


Fig. 6. Relation between hind-limb motor function and percentage area of vacuolation. Hind-limb motor function was assessed just before the reperfusion using Tarlov scoring, which consists of a five-point grading scale: 0 = paraplegic with no lower extremity function; 1 = poor lower extremity function, weak antigravity movement only; 2 = some lower extremity motor function with good antigravity strength but inability to draw legs under body and hop but not normally; 4 = normal motor function. *Open circle, closed triangle, closed circle, and open triangle* indicate the animals in the sham, 24-h, 4-day, and 14-day groups, respectively. There was a significant negative correlation between motor function and vacuolation area ($r = -0.631, P = 0.0001$)

ischemia. Because histologic assessment in most studies of SCI in rabbits was performed within 2-3 days after ischemia, it may not have been possible to identify delayed white matter injury.

Of note was the observation that hind-limb motor function gradually deteriorated and reached a nadir 14 days after reperfusion. This highlights the importance of long-term neurologic evaluation after ischemia injury. Short-term assessment may underestimate the extent of neurologic dysfunction, and therefore, such assessments may be insufficient for purposes of quantifying the extent of neurologic injury. It should be noted, however, that the degree of injury to the white and gray matter

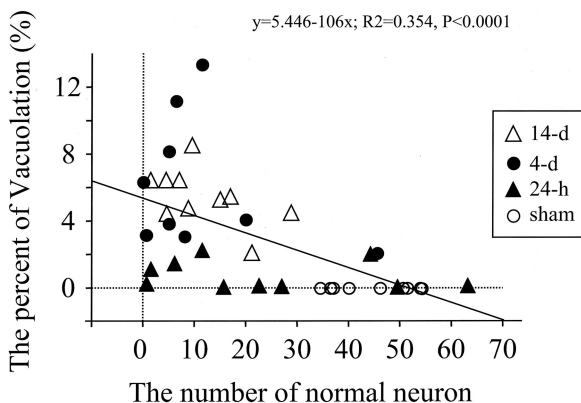


Fig. 7. Relation between the number of normal neurons and percentage area of vacuolation. *Open circle, closed triangle, closed circle, and open triangle* indicate the animals in the sham, 24-h, 4-day, and 14-day groups, respectively. A significant negative correlation was noted between the number of normal neurons and the percentage areas of vacuolation ($R^2 = 0.354, P < 0.0001$).

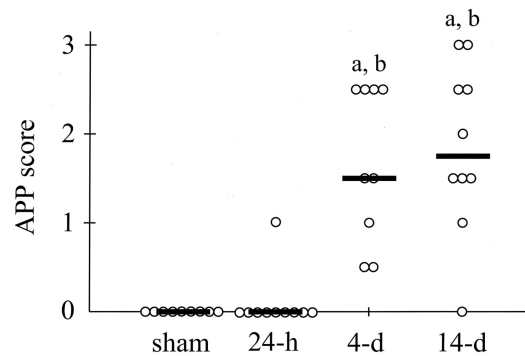


Fig. 8. Amyloid precursor protein (APP) immunoreactivity in the experimental groups. APP immunoreactivity in the areas of ventral, ventrolateral, and lateral white matter was assessed using APP scores, which consist of a score of 0 (no APP immunoreactivity) or 1 (APP immunoreactivity in axonal swellings). Total scores in each animal ranging from 0 to 3 (average of both sides) are shown. APP scores in the 4-day and 14-day groups were significantly higher than those in the 24-h and sham groups ($P < 0.05$). There was no difference in APP scores between sham group and the 24-h group. Bars indicate median values. a: $P < 0.05$ versus sham; b: $P < 0.05$ versus 24-h.

was similar in the 4-day and 14-day groups even though there was a further deterioration in hind-limb function from day 4 to day 14. The reason for the continued deterioration in function is not clear. One possibility that deserves comment is the high mortality rate in the 14-day group. In this study, mortality rates of animals were 9, 10, and 29% in the 24-h, 4-day, and 14-day groups, respectively. It is conceivable that the animals that died before the completion of the study might have been the ones that were more severely injured. Consequently, their exclusion from analysis would tend to underestimate the extent of injury in the 14-day group.

In summary, our results indicate that SCI induced white matter as well as gray matter damage in rabbits. There was a progressive deterioration in hind-limb motor function over the course of 14 days. Gray matter injury was apparent early after ischemia and was maximal at 4 days, whereas white matter injury was delayed. The data are consistent with the premise that both gray and white matter injury contributed to the progression of hind-limb motor dysfunction. Our results highlight the need for long-term evaluation of neurologic function in studies of spinal cord ischemia and the importance of quantifying not only gray matter injury but also that of white matter.

References

1. Svensson LG, Crawford ES, Hess KR, Coselli JS, Safi HJ: Experience with 1509 patients undergoing thoracoabdominal aortic operation. *J Vasc Surg* 1993; 17:357-70
2. Wan IYP, Angelini GD, Bryan AJ, Ryder I, Underwood MJ: Prevention of spinal cord ischemia during descending thoracic and thoracoabdominal aortic surgery. *Eur J Cardiothorac Surg* 2001; 19:203-13
3. Coselli JS, LeMaire SA, Conklin LD, Koksoy C, Schmittling ZC: Morbidity and mortality after extent thoracoabdominal aortic aneurysm repair. *Ann Thorac Surg* 2002; 73:1107-16
4. Derrow AE, Seeger JM, Dame DA, Carter RL, Ozaki CK, Flynn TC, Huber TS:

The outcome in the United States after thoracoabdominal aortic aneurysm repair, renal artery bypass, and mesenteric revascularization. *J Vasc Surg* 2001; 34:54-61

5. Juvonen T, Biancari F, Rimpiläinen J, Satta J, Raino P, Kiviluoma K: Strategies for spinal cord protection during descending thoracic and thoracoabdominal aortic surgery: Up-to-date experimental and clinical results—a review. *Scand Cardiovasc J* 2002; 36:136-60

6. de Haan P, Kalkman CJ, Jacobs MJ: Pharmacologic neuroprotection in experimental spinal cord ischemia: A systematic review. *J Neurosurg Anesthesiol* 2001; 13:3-12

7. Zivin JA, DeGirolami U: Spinal cord infarction: A highly reproducible stroke model. *Stroke* 1980; 11:200-2

8. Matsumoto M, Iida Y, Sakabe T, Sano T, Ishikawa T, Nakakimura K: Mild and moderate hypothermia provide better protection than a burst-suppression dose of thiopental against ischemic spinal cord injury in rabbits. *ANESTHESIOLOGY* 1997; 86:1120-7

9. Kakinohana M, Taira Y, Marsala M: The effect of graded postischemic spinal cord hypothermia on neurological outcome and histopathology after transient spinal ischemia in rat. *ANESTHESIOLOGY* 1999; 90:789-98

10. Lips J, de Haan P, Bodewits P, Vanicky I, Dzoljic M, Jacobs MJ, Kalkman CJ: Neuroprotective effects of riluzole and ketamine during transient spinal cord ischemia in the rabbit. *ANESTHESIOLOGY* 2000; 93:1303-11

11. Follis F, Scremin OU, Blisard KS, Scremin AM, Pett SB, Scott WJ, Kessler RM, Wernly JA: Selective vulnerability of white matter during spinal cord ischemia. *J Cereb Blood Flow Metab* 1993; 13:170-8

12. Blisard KS, Follis F, Wong R, Miller KB, Wernly JA, Scremin OU: Degeneration of axons in the corticospinal tract secondary to spinal cord ischemia in rats. *Paraplegia* 1995; 33:136-40

13. Kanellopoulos GK, Xu XM, Hsu CY, Lu X, Sundt TM, Kouchoukos NT: White matter injury in spinal cord ischemia—protection by AMPA/kainate glutamate receptor antagonism. *Stroke* 2000; 31:1945-52

14. Kurita N, Kawaguchi M, Horiuchi T, Inoue S, Sakamoto T, Nakamura M, Konishi N, Furuya H: An evaluation of white matter injury after spinal cord ischemia in rats: A comparison with gray matter injury. *Anesth Analg* 2005; 100:847-54

15. Valeriani V, Dewar D, McCulloch J: Quantitative assessment of ischemic pathology in axons, oligodendrocytes, and neurons: Attenuation of damage after transient ischemia. *J Cereb Blood Flow Metab* 2000; 20:765-71

16. Imai H, McCulloch J, Graham DI, Masayasu H, Macrae IM: New Method for the quantitative assessment of axonal damage in focal cerebral ischemia. *J Cereb Blood Flow Metab* 2002; 22:1080-9

17. Kakimoto M, Kawaguchi M, Sakamoto T, Inoue S, Furuya H, Nakamura M, Konishi N: Evaluation of rapid ischemic preconditioning in a rabbit model of spinal cord ischemia. *ANESTHESIOLOGY* 2003; 99:1112-7

18. Tarlov IM: Acute spinal cord compression paralysis. *J Neurosurg* 1972; 36:10-20

19. Pantoni L, Garcia JH, Gutierrez JA: Cerebral white matter is highly vulnerable to ischemia. *Stroke* 1996; 27:1641-7

20. Yam PS, Takasago T, Dewar D, Graham DI, McCulloch J: Amyloid precursor protein accumulates in white matter at the margin of a focal ischaemic lesion. *Brain Res* 1997; 760:150-7

21. Westergren H, Yu WR, Farooque M, Holtz A, Olsson Y: Systemic hypothermia following spinal cord compression injury in the rat: Axonal changes studied by beta-APP, ubiquitin, and PGP 9.5 immunohistochemistry. *Spinal Cord* 1999; 37:696-704