David C. Warltier, M.D., Ph.D., Editor

Anesthesiology 2006; 104:368–73 © 2006 American Society of Anesthesiologists, Inc. Lippincott Williams & Wilkins, Inc.

Ultrasound-guided Regional Anesthesia

Current State of the Art

*Andrew T. Gray, M.D., Ph.D.**

HIGH-RESOLUTION ultrasound can provide direct real-time imaging of peripheral nerves and identify tissue planes that permit favorable local anesthetic distribution for conduction block and catheter placement. To be successful at ultrasound-guided neural blockade, one must be familiar with the relevant cross-sectional anatomy and the coordination of the imaging probe with the block needle. Ultrasound has many roles in pain management interventions, both peripheral and neuraxial.

Relation of Ultrasound with Other Techniques for Regional Block

With imaging playing an increasing role in vascular access, transesophageal echocardiography, and regional blockade, the ultrasound machine may become an important component of the anesthesia machine of the future. Other fields of medicine in which practitioners are familiar with ultrasound imaging, such as emergency medicine, also may use ultrasound to guide regional blockade. Ultrasound guidance can be combined with alternative techniques for regional block, including nerve stimulation.

Ultrasound guidance can be used for neuraxial blocks. Ultrasound imaging may improve success with epidural placement.[1] Paramedian longitudinal imaging planes provide the best acoustic window around bony structures. Of neuraxial structures, the dura mater is well visualized with ultrasound imaging. However, formal review of ultrasound guidance for neuraxial anesthesia is beyond the scope of this article.

Nerve Imaging with Ultrasound

Additional information regarding this is available on the ANESTHESIOLOGY Web site at http://www.anesthesiology.org.†

Because peripheral nerves can be difficult to identify from adjacent background structures, it is important to know all of their distinguishing features. The smallest peripheral nerves that have been imaged with ultrasound are the digital nerves.[2] These nerves are 2 mm in diameter and have been examined for the purpose of assessing nerve repair. While the limits of resolution continue to improve, most of the nerves for regional blockade can be imaged with ultrasound technology today. Nerves can have a round, oval, or triangular shape.[3] Interestingly, a single nerve can have all three shapes along its nerve path as it travels between adjacent structures.[4]

Nerves are not static structures. Nerve position within the subarachnoid space is influenced by gravity and body position.[5] Extremity movement causes sciatic nerve rotation in the popliteal fossa.[6] Light pressure with the ultrasound probe can displace nerves to the side of the axillary artery.[7] Peripheral nerves also can be displaced by the advancing block needle or local anesthetic injection, and this may be an underlying safety factor for peripheral block.

Cervical nerve roots (ventral rami) have a monofascicular appearance on ultrasound scans,[8] whereas more peripheral nerves have an internal fascicular pattern characterized by hypoechoic (dark) fascicles surrounded by

This article is featured in "This Month in Anesthesiology." Please see this issue of ANESTHESIOLOGY, page 5A.

Additional material related to this article can be found on the ANESTHESIOLOGY Web site. Go to http://www.anesthesiology.org, click on Enhancements Index, and then scroll down to find the appropriate article and link. Supplementary material can also be accessed on the Web by clicking on the "ArticlePlus" link either in the Table of Contents or at the top of the HTML version of the article.

* Associate Professor.

Received from the Department of Anesthesia and Perioperative Care, University of California, San Francisco, San Francisco General Hospital, San Francisco, California. Submitted for publication May 17, 2005. Accepted for publication July 19, 2005. Support was provided solely from institutional and/or departmental sources. Presented in part at the Second Annual International Symposium for Ultrasound and Regional Anaesthesia, Schwetzingen, Germany, April 1–3, 2005.

Figure 1A and Table 1 in this article have been prepared by Dimitri Karetnikov, 7 Tennyson Drive, Plainsboro, New Jersey 08536.

Address correspondence to Dr. Gray: Department of Anesthesia and Perioperative Care, Room 3C-38, San Francisco General Hospital, University of California, San Francisco, California 94110. graya@anesthesia.ucsf.edu. Individual article reprints may be accessed at no charge through the Journal Web site, www.anesthesiology.org.

† Because dynamic aspects of ultrasound imaging are critical to regional block, supplemental video materials are provided. These videos illustrate ultrasound imaging of peripheral nerves, block needle, and local anesthetic distribution.

Copyright © by the American Society of Anesthesiologists. Unauthorized reproduction of this article is prohibited.

Downloaded from http://asa2.silverchair.com/anesthesiology/article-pdf/104/2/368/359610/0000542-200602000-00024.pdf by guest on 19 April 2024

hyperechoic (bright) connective tissue. This fascicular echotexture results in the "honeycomb" appearance of nerves on short axis (transverse) scan. Although the genesis of the fascicular echotexture pattern is not completely understood, approximately one third the number of fascicles visible on light microscopy is visible on ultrasound at 15 MHz.[9]

Nerve identity can be confirmed by scanning along the known course of the nerve. Ultrasound can easily follow the oblique course of nerves, and this is difficult to accomplish with other imaging modalities such as magnetic resonance imaging.[10] Short axis (transverse) scanning is preferred to follow a nerve along its course.

Although nerve vasculature can be demonstrated with color Doppler in some healthy subjects,[11] this imaging mode is useful for distinguishing smaller nerves from vessels. Specifically, a robust Doppler signal distinguishes a blood vessel from a small nerve. Unlike vessels, nerves are not compressible structures.

Tendons have similar ultrasound appearance to nerves. The tendon echotexture consists of a fibrillar pattern: fine linear echos resembling fibrils, with hypoechoic areas that are not as prominent (like the fine hairs of a violin's bow). A 10-MHz transducer can differentiate the fascicular and fibrillar echotexture patterns. In addition, tendons only form at the ends of muscle, whereas nerve area is relatively uniform along the nerve path. Furthermore, most blocks are performed where tendons are not in the scan plane. Tendons are more anisotropic than nerves, meaning the echo intensity will vary more substantially with the angle of insonation.

Advances in ultrasound technology will allow imaging of smaller and deeper nerves. Today, high-frequency broadband linear probes provide the best nerve imaging.[11] Display of nerve sonograms is commonly performed with grayscale postprocessing maps, although there is recent evidence that color encoding received echoes improves musculoskeletal imaging.[12]

Needle Visibility

The primary factors that determine the ultrasound visibility of the needle are the insertion angle and gauge.[13] At steep angles, backscatter from the needle rather than specular reflections is received by the ultrasound transducer.[14] This results in marked reductions in needle tip visibility. Many authors have emphasized the critical importance of establishing needle tip visibility before advancing the needle when the in plane approach is used (see section entitled The In-plane Needle Approach). However, needle tip visibility is inherently reduced at steep angles and may present problems. Entering the skin with the needle close to the transducer disturbs the surface contact and forces steep angles to the target.

Large-bore needles are easier to visualize for two reasons. First, the larger cross-sectional area makes the needle easier to locate. Second, larger needles are less flexible and therefore less likely to bend out of the plane of imaging. One strategy has been to use large-bore (17-gauge) needles to promote needle tip visibility for deeper blocks.[15]

The role of acoustic background is substantial: The needle tip is best visualized within dark (anechoic) vessels or local anesthetic. A dark background, which can be created by low receiver gain, can improve needle tip visibility. Commercial modifications (coating or dimpling) to improve echogenicity of regional block needles are technically possible but have not been specifically marketed at this time.

Vascular punctures have been reported despite use of the in plane technique, emphasizing the importance of needle tip visibility in clinical practice.[15,16] These inadvertent vascular punctures have occurred despite the fact that vessels are the easiest anatomical structures to identify with ultrasound. However, the vascular puncture rates with ultrasound guidance are probably lower than with other approaches to regional block.[17]

Local Anesthetic Solutions and Injection

Injection of quiescent (unagitated) solution can serve as reverse contrast, outlining the borders of the anesthetized nerve. Nerves will often be easier to identify after injection of undisturbed local anesthetic and sometimes can be seen to float freely within the injected solution. Injection of small amounts of air (0.3–0.5 ml) into the tissue through a needle can be used to identify the location of the tip.[18] Although bubbles are easy to identify sonographically and can serve as a useful marker of the needle tip, bubbles also can disperse in tissue and cause acoustic shadowing distally, becoming problematic. Therefore, all air bubbles are removed from the local anesthetic solution before injection. Most practitioners elect not to use bicarbonate containing solutions of local anesthetic because these solutions evolve carbon dioxide, which obscures imaging.

One of the most important advantages of ultrasound imaging is the ability to reposition the needle after initial injection of local anesthetic. Test injections to visualize local anesthetic distribution should be small (1–2 ml). If the local anesthetic distribution is not seen on the monitoring screen immediately stop, aspirate, and move the transducer or needle (do not continue to inject because inadvertent intravascular injection is one of the possibilities). If the local anesthetic distribution does not adequately surround the nerves, the block needle can be repositioned, and the process of test injections can be continued. It is not necessary to contact nerves with the block needle to surround them with local anesthetic if

Copyright © by the American Society of Anesthesiologists. Unauthorized reproduction of this article is prohibited.

Downloaded from http://asa2.silverchair.com/anesthesiology/article-pdf/104/2/368/359610/0000542-200602000-00024.pdf by guest on 19 April 2024

the correct fascial planes are identified. After injection, the local anesthetic distribution can be assessed by sliding the transducer along the nerve path with the nerve viewed in short axis.

Imaging Planes and Approaches to Regional Block

Imaging Planes for Nerves

Nerves can be imaged in short axis or long axis (fig. 1). This nomenclature is familiar to many anesthesiologists because it is used in the field of transesophageal echocardiography.[19] Similarly, the terms *transverse* and *longitudinal* have been used in the radiology literature. Ultrasound-guided blocks are generally performed with short axis imaging of nerves for several reasons. First, identification of peripheral nerves is relatively easy. Second, there is good resolution of the fascial barriers that surround nerves. Third, dynamic assessment and verification of circumferential distribution of local anesthetic with injection is possible. Finally, if the transducer moves slightly, the image is still workable (an oblique view of the nerve). For these reasons, short axis views of peripheral nerves for regional blocks have dominated practice at many institutions.

The Out-of-plane Needle Approach

The out-of-plane (OOP) technique involves inserting the needle so that it crosses the plane of imaging near the target. With this approach, the target is typically centered within the field of view and the depth noted. If the needle tip is not visualized, the endpoint for injection is not so clear and may require more dependence on small-volume test injections for visualization of adequate local anesthetic distribution. The OOP technique can be made similar to the in-plane (IP) technique (see section entitled The In-plane Needle Approach) with sliding and tilting of the transducer[20] so as to follow the needle tip.

The In-plane Needle Approach

The needle can be inserted within the plane of imaging to visualize the entire shaft and tip (IP technique). For the IP approach, the imaged needle path should be maximized by placing the target on the side of the imaging field of view away from the approaching needle. The transducer can be manipulated as necessary to bring the needle into the plane of imaging. If the needle tip is not clearly identified within the plane of imaging, do not advance the needle. When the needle is in plane (longitudinal scan), the *in vivo* sonographic appearance will be hyperechoic, with parallel hyperechoic traces displayed away from the transducer. These hyperechoic traces result from reverberations inside the needle itself.[21]

General Comments

Both the IP and OOP approaches are currently in clinical use, and the merits of each have been debated. Critics of the OOP approach are concerned that lack of needle tip visibility during the procedure can lead to complications. Finding an echogenic dot for the OOP approach within a bright background can be difficult (but IP needle tip identification also can be difficult in this circumstance). Critics of the IP approach are concerned that this approach is time-consuming and that partial lineups of the needle and probe create a false sense of security. If the transducer tilt is critical to nerve visibility, then with the IP approach, which usually requires transducer manipulation, it can be difficult to visualize the block needle and nerve simultaneously. The IP approach requires longer needle insertion paths than the OOP approach and can therefore cause more patient discomfort.[22]

For either the OOP or the IP approach, the author's institution prefers a freehand technique to the use of needle guides. A flat angle of approach improves needle visualization (place the needle entry point away from the transducer to achieve a flatter angle and produce less problems with probe contact). Optimal visualization of the needle occurs when the needle is parallel to the active face of the transducer. The needle should be inserted with the bevel directly facing (or averting) the active face of the transducer to improve visibility of the needle tip.[23]

The long axis in plane approach may be suitable for vascular access procedures.[24] However, alignment on nerves can be difficult because nerves do not always have a straight path and slight movement of the transducer can result in loss of the nerve image. Furthermore, with the long axis IP approach, the needle is constrained to come down directly on the nerve and therefore may increase the chance of injecting into the targeted structure.[25]

Clinical Studies

A number of clinical trials have examined block characteristics with ultrasound guidance (table 1).[15–17,26–29] Several types of clinical blocks at different anatomical locations have been studied. All studies found improved block characteristics with ultrasound guidance (or a trend toward such a difference). This includes block performance time, an issue of interest today because of the focus on operating room efficiency. The lack of statistical difference in success rates is not surprising given the high overall success rates (the studies were underpowered to find a small increase in success rate). No study has found that nerve stimulation improves block characteristics compared with ultrasound. Although one cannot exclude the possibility of reporting bias, favorable block outcomes with ultrasound guidance are strongly suggested.

The reported incidence of nerve injury after peripheral nerve block is low and highly depends on the method of

Copyright © by the American Society of Anesthesiologists. Unauthorized reproduction of this article is prohibited.

Downloaded from http://asa2.silverchair.com/anesthesiology/article-pdf/104/2/368/359610/0000542-200602000-00024.pdf by guest on 19 April 2024

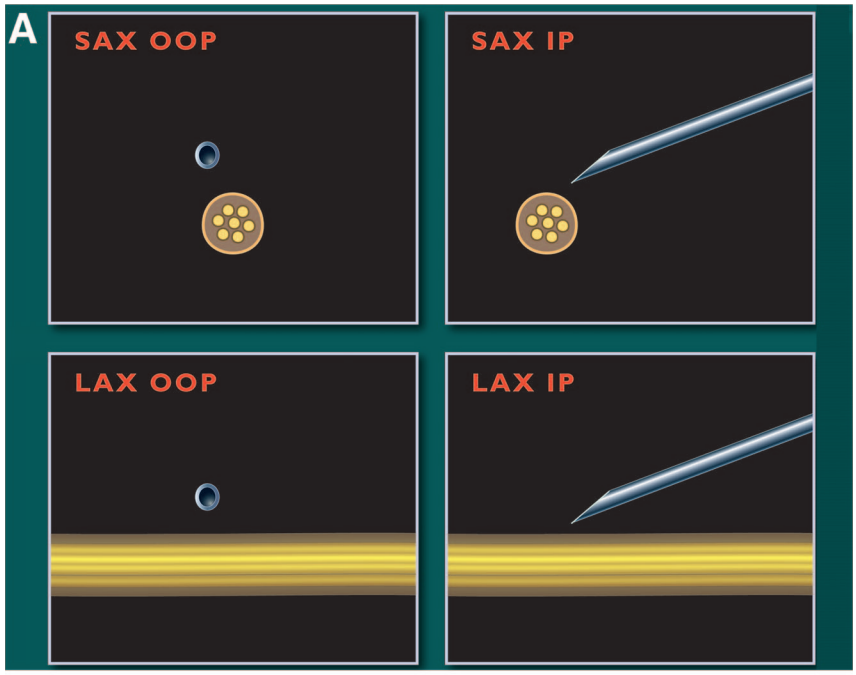

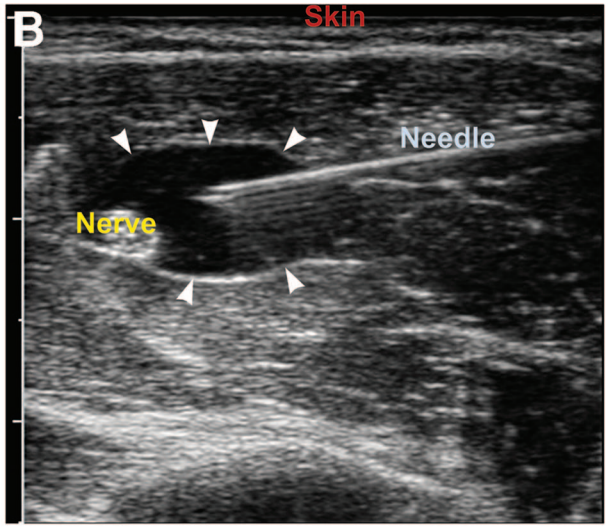

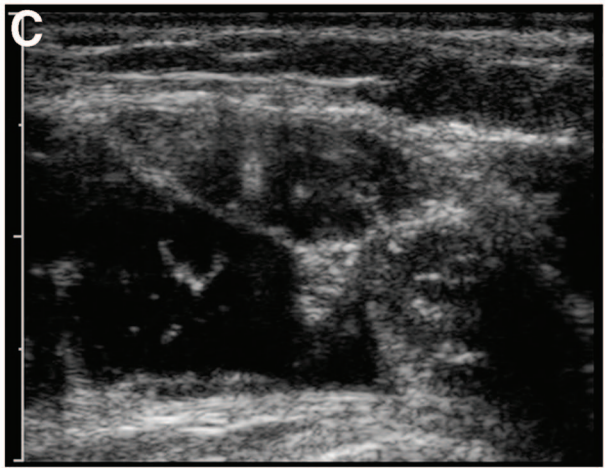

Fig. 1. (*A*) Approaches to regional block with ultrasound (SAX OOP, SAX IP, LAX OOP, and LAX IP). For the OOP approach, the needle crosses the plane of imaging as an echogenic dot with the target centered in the field of view. For the IP technique, the entire tip and shaft of the needle are seen while the needle approaches the target on the opposite side of the field. IP = in-plane approach of the needle; LAX = long axis view of the target; OOP = out-of-plane approach of the needle; SAX = short axis view of the target. (*B*) Short axis (transverse cross-sectional) ultrasound scan of the musculocutaneous nerve in the axilla. The needle tip and local anesthetic injection (*arrowheads*) are identified within the plane of imaging (SAX IP approach). After the initial injection the needle tip is substantially displaced from the nerve. *Large tick marks* are spaced 10 mm. (*C*) Short axis (transverse cross-sectional) ultrasound scan of the musculocutaneous nerve in the axilla. The needle tip crosses the plane of imaging to facilitate local anesthetic injections (SAX OOP approach). Multiple test injections and needle repositioning were performed based on feedback using the observed images. *Large tick marks* are spaced 10 mm.

Downloaded from http://asa2.silverchair.com/anesthesiology/article-pdf/104/2/368/359610/0000542-200602000-00024.pdf by guest on 19 April 2024

Copyright © by the American Society of Anesthesiologists. Unauthorized reproduction of this article is prohibited.

Table 1. Clinical studies measuring characteristics of ultrasound guided peripheral nerve blocks

Outcome	Block	Ultrasound	Nerve Stimulation	P Value	Study Design	Ref.
Performance (min)	Supraclavicular	5.0 ± 2.4 (40)	9.8 ± 7.5 (40)	< 0.001	Randomized	26
	Infraclavicular	10.0 ± 4.4 (114)	NA	NA	Prospective	15
	Musculocutaneous	1.9 ± 0.7 (10)	NA	NA	Prospective	27
Success (%)	Supraclavicular	85% (40)	78% (40)	NS	Randomized	26
	Supraclavicular	95% (40)	NA	NA	Prospective	16
	Infraclavicular	100% (20)	100% (20)	NS	Randomized	28
	Infraclavicular	90% (126)	NA	NA	Prospective	15
	Musculocutaneous	100% (10)	NA	NA	Prospective	27
	Three-in-one	95% (20)	85% (20)	NS	Randomized	29
	Three-in-one	95% (20)	80% (20)	NS	Randomized	17
Onset (min)	Infraclavicular	6.7 ± 3.2 (114)	NA	NA	Prospective	15
	Supraclavicular	9 [5-15] (20)	15 [5-25] (20)	< 0.001	Randomized	28
	Musculocutaneous	3.6 ± 0.9 (10)	NA	NA	Prospective	27
	Three-in-one	16 ± 14 (20)	27 ± 16 (20)	< 0.05	Randomized	29
	Three-in-one	13 ± 16 (20)	27 ± 12 (20)	< 0.01	Randomized	17
Duration (min)	Supraclavicular	846 ± 531 (40)	652 ± 473 (40)	NS	Randomized	26
	Supraclavicular	384 [280-480] (20)	310 [210-420] (20)	< 0.001	Randomized	28

Unless otherwise stated, data are expressed as mean ± SD (N value). Marhofer et al., 2004 expressed data as median [range].[28] Chan et al., 2003 confirmed all ultrasound guided blocks with nerve stimulation.[16] Spence et al., 2005 confirmed some ultrasound guided blocks with nerve stimulation.[27] NA = not applicable. NS = not statistically significant ($P \geq 0.05$). Ref. = reference.

follow-up. Therefore, large controlled studies are needed to look at approaches to peripheral nerve block and their complications. These safety issues have yet to be addressed in a prospective fashion.

As this new field develops, we must appreciate that we are studying an evolving technology. Therefore, published results may not accurately reflect current practice. An effect of training during a clinical trial has been shown for ultrasound guidance but not for the control nerve stimulation group.[26] While clinical trials will continue to compare effort and operator dependent techniques, this result suggests that performance of ultrasound guidance will improve.

Recent Developments in Ultrasound Imaging

In this issue of Anesthesiology, Dr. Chan *et al.*[30] convincingly demonstrate that it is possible to image the largest peripheral nerve in the body (the sciatic nerve, which is approximately 17 mm in its mediolateral dimension) with low-frequency (2- to 5-MHz) ultrasound and curved array transducers. Previous investigators have stated that frequencies of 10 MHz or higher are necessary to discriminate peripheral nerves from tendons or background. This advance will appear subtle to some readers, but the implications for the future of anesthetic practice may be enormous.

The study dispels the belief that ultrasound frequencies of 10 MHz or higher are necessary to image peripheral nerves. Attenuation of ultrasound waves relates to frequency *via* the attenuation constant (approximately 0.75 dB/(cm-MHz) in soft tissue), indicating larger attenuation of high frequencies. Because sound waves are longitudinal waves, the frequency only relates to one component of resolution (the axial resolution along the path of the sound beam). Other components of resolution (lateral resolution and elevational resolution) are typically worse and therefore potentially more important.

Now that we are aiming at lower frequencies for nerve imaging with ultrasound, new issues arise. There is some suggestion from the sonograms provided that nerve fascicles can be identified at 2–5 MHz. However, adjacent structures may have similar sonographic appearance to the sciatic nerve in the thigh (specifically, the tendon of

Copyright © by the American Society of Anesthesiologists. Unauthorized reproduction of this article is prohibited.

Downloaded from http://asa2.silverchair.com/anesthesiology/article-pdf/104/2/368/359610/0000542-200602000-00024.pdf by guest on 19 April 2024

the long head of the biceps femoris). At these low frequencies, nerves and tendons must be distinguished using different criteria than fascicular or fibrillar echotexture. Tendons and nerves must be discriminated based on position and change in size and shape along their course.

These investigators used a curved array that provides a broad view useful for imaging the approaching block needle. However, in this study, block needle visibility was not demonstrated, so the critical issue with the use of curved arrays and low frequencies may actually relate more to needle visibility than to nerve visibility. Controlled studies of needle visibility comparing linear and curved arrays are needed to address this issue specifically. If needle visibility at these frequencies with a curved probe is problematic, nerve stimulation is probably still essential. Sciatic nerve stimulation was consistent with sonographic evidence of needle–nerve contact (unlike previous studies of the brachial plexus by this same research group).

Most observed nerve depths ranged between 3 and 7 cm, depths that can be reached with higher-frequency ultrasound and better image quality. The biggest advance of this study might be for obese subjects, who were not formally included. In this set of 15 volunteers, these authors did not detect proximal sciatic nerve division by the piriformis muscle (an anatomical variant with estimated incidence between 1.5 and 21%),[31] a suggested benefit of ultrasound imaging to prevent incomplete block.[22]

Conclusions

Clinical studies suggest that ultrasound guidance has advantages over more traditional nerve stimulation–based techniques for regional block. If desired, ultrasound guidance can be combined with nerve stimulation to confirm proximity to neural structures. However, it is not necessary to use electrical stimulation or obtain paresthesias to achieve reliable conduction block of peripheral nerves. Given clinical experience, practitioners will become confident in assigning nerve identity based on ultrasound appearance alone. Because ultrasound imaging is especially useful in patients with difficult external anatomy, many clinicians have now integrated its use into their routine clinical practice to gain expertise with this important technology.

References

1. Grau T, Leipold RW, Conradi R, Martin E, Motsch J: Efficacy of ultrasound imaging in obstetric epidural anesthesia. J Clin Anesth 2002; 14:169–75
2. Peer S, Harpf C, Willeit J, Piza-Katzer H, Bodner G: Sonographic evaluation of primary peripheral nerve repair. J Ultrasound Med 2003; 22:1317–22
3. Gruber H, Peer S, Kovacs P, Marth R, Bodner G: The ultrasonographic appearance of the femoral nerve and cases of iatrogenic impairment. J Ultrasound Med 2003; 22:163–72
4. Schafhalter-Zoppoth I, Gray AT: The musculocutaneous nerve: Ultrasound appearance for peripheral nerve block. Reg Anesth Pain Med 2005; 30:385–90
5. Takiguchi T, Yamaguchi S, Okuda Y, Kitajima T: Deviation of the cauda equina by changing position. ANESTHESIOLOGY 2004; 100:754–5
6. Schafhalter-Zoppoth I, Younger SJ, Collins AB, Gray AT: The "seesaw" sign: Improved sonographic identification of the sciatic nerve. ANESTHESIOLOGY 2004; 101:808–9
7. Retzl G, Kapral S, Greher M, Mauritz W: Ultrasonographic findings of the axillary part of the brachial plexus. Anesth Analg 2001; 92:1271–5
8. Martinoli C, Bianchi S, Santacroce E, Pugliese F, Graif M, Derchi LE: Brachial plexus sonography: A technique for assessing the root level. AJR Am J Roentgenol 2002; 179:699–702
9. Silvestri E, Martinoli C, Derchi LE, Bertolotto M, Chiaramondia M, Rosenberg I: Echotexture of peripheral nerves: Correlation between US and histologic findings and criteria to differentiate tendons. Radiology 1995; 197:291–6
10. Peer S, Bodner G: High-Resolution Sonography of the Peripheral Nervous System. Berlin, Springer Verlag, 2003, pp 3–4
11. Martinoli C, Bianchi S, Derchi LE: Tendon and nerve sonography. Radiol Clin North Am 1999;37:691–711, viii
12. Sofka CM, Lin D, Adler RS: Advantages of color B-mode imaging with contrast optimization in sonography of low-contrast musculoskeletal lesions and structures in the foot and ankle. J Ultrasound Med 2005; 24:215–8
13. Schafhalter-Zoppoth I, McCulloch CE, Gray AT: Ultrasound visibility of needles used for regional nerve block: An in vitro study. Reg Anesth Pain Med 2004; 29:480–8
14. Winn VD, Sonson J, Filly RA: Echogenic intracardiac focus: potential for misdiagnosis. J Ultrasound Med 2003; 22:1207–14
15. Sandhu NS, Capan LM: Ultrasound-guided infraclavicular brachial plexus block. Br J Anaesth 2002; 89:254–9
16. Chan VW, Perlas A, Rawson R, Odukoya O: Ultrasound-guided supraclavicular brachial plexus block. Anesth Analg 2003; 97:1514–7
17. Marhofer P, Schrogendorfer K, Wallner T, Koinig H, Mayer N, Kapral S: Ultrasonographic guidance reduces the amount of local anesthetic for 3-in-1 blocks. Reg Anesth Pain Med 1998; 23:584–8
18. Lee TG, Knochel JQ: Air as an ultrasound contrast marker for accurate determination of needle placement: Tumor biopsy localization and other applications. Radiology 1982; 143:787–8
19. Shanewise JS, Cheung AT, Aronson S, Stewart WJ, Weiss RL, Mark JB, Savage RM, Sears-Rogan P, Mathew JP, Quinones MA, Cahalan MK, Savino JS: ASE/SCA guidelines for performing a comprehensive intraoperative multiplane transesophageal echocardiography examination: Recommendations of the American Society of Echocardiography Council for Intraoperative Echocardiography and the Society of Cardiovascular Anesthesiologists Task Force for Certification in Perioperative Transesophageal Echocardiography. Anesth Analg 1999; 89:870–84
20. American Institute of Ultrasound in Medicine: AIUM technical bulletin: Transducer manipulation. J Ultrasound Med 1999; 18:169–75
21. Fornage BD: Preoperative sonographic localization of a migrated transosseous stabilizing wire in the hand. J Ultrasound Med 1987; 6:471–3
22. Marhofer P, Greher M, Kapral S: Ultrasound guidance in regional anaesthesia. Br J Anaesth 2005; 94:7–17
23. Hopkins RE, Bradley M: In-vitro visualization of biopsy needles with ultrasound: A comparative study of standard and echogenic needles using an ultrasound phantom. Clin Radiol 2001; 56:499–502
24. Yeow KM, Toh CH, Wu CH, Lee RY, Hsieh HC, Liau CT, Li HJ: Sonographically guided antegrade common femoral artery access. J Ultrasound Med 2002; 21:1413–6
25. Adler RS, Sofka CM: Percutaneous ultrasound-guided injections in the musculoskeletal system. Ultrasound Q 2003; 19:3–12
26. Williams SR, Chouinard P, Arcand G, Harris P, Ruel M, Boudreault D, Girard F: Ultrasound guidance speeds execution and improves the quality of supraclavicular block. Anesth Analg 2003; 97:1518–23
27. Spence BC, Sites BD, Beach ML: Ultrasound-guided musculocutaneous nerve block: A description of a novel technique. Reg Anesth Pain Med 2005; 30:198–201
28. Marhofer P, Sitzwohl C, Greher M, Kapral S: Ultrasound guidance for infraclavicular brachial plexus anaesthesia in children. Anaesthesia 2004; 59: 642–6
29. Marhofer P, Schrogendorfer K, Koinig H, Kapral S, Weinstabl C, Mayer N: Ultrasonographic guidance improves sensory block and onset time of three-in-one blocks. Anesth Analg 1997; 85:854–7
30. Chan VWS, Nova H, Abbas S, McCartney CJL, Perlas A, Xu D: Ultrasound examination and localization of the sciatic nerve: A volunteer study. ANESTHESIOLOGY 2006; 104:309–14
31. Benzon HT, Katz JA, Benzon HA, Iqbal MS: Piriformis syndrome: Anatomic considerations, a new injection technique, and a review of the literature. ANESTHESIOLOGY 2003;98:1442–8

Copyright © by the American Society of Anesthesiologists. Unauthorized reproduction of this article is prohibited.

Downloaded from http://asa2.silverchair.com/anesthesiology/article-pdf/104/2/368/359610/0000542-200602000-00024.pdf by guest on 19 April 2024