

Sonographic Visualization and Ultrasound-guided Block of the Third Occipital Nerve

Prospective for a New Method to Diagnose C2-C3 Zygapophysial Joint Pain

Urs Eichenberger, M.D.,* Manfred Greher, M.D.,† Stephan Kapral, M.D.,‡ Peter Marhofer, M.D.,‡ Roland Wiest, M.D.,§ Luca Remonda, M.D.,|| Nikolai Bogduk, M.D., Ph.D.,# Michele Curatolo, M.D. Ph.D.**

Background: Chronic neck pain after whiplash injury is caused by cervical zygapophysial joints in 50% of patients. Diagnostic blocks of nerves supplying the joints are performed using fluoroscopy. The authors' hypothesis was that the third occipital nerve can be visualized and blocked with use of an ultrasound-guided technique.

Methods: In 14 volunteers, the authors placed a needle ultrasound-guided to the third occipital nerve on both sides of the neck. They punctured caudal and perpendicular to the 14-MHz transducer. In 11 volunteers, 0.9 ml of either local anesthetic or normal saline was applied in a randomized, double-blind, crossover manner. Anesthesia was controlled in the corresponding skin area by pinprick and cold testing. The position of the needle was controlled by fluoroscopy.

Results: The third occipital nerve could be visualized in all subjects and showed a median diameter of 2.0 mm. Anesthesia was missing after local anesthetic in only one case. There was neither anesthesia nor hyposensitivity after any of the saline injections. The C2-C3 joint, in a transversal plane visualized as a convex density, was identified correctly by ultrasound in 27 of 28 cases, and 23 needles were placed correctly into the target zone.

Conclusions: The third occipital nerve can be visualized and blocked with use of an ultrasound-guided technique. The needles were positioned accurately in 82% of cases as confirmed by fluoroscopy; the nerve was blocked in 90% of cases. Because ultrasound is the only available technique today to visualize this nerve, it seems to be a promising new method for block guidance instead of fluoroscopy.

LONG-TERM outcome after conservative treatment of chronic neck pain after whiplash injury is frequently poor.¹ Among the possible reasons for this are that an anatomical diagnosis is not made and that treatment does not specifically target the source of pain. However, if diagnostic blocks are used, the source of pain can be traced to one or more of the cervical zygapophysial

joints in more than 50% of patients.² These patients can then be treated by percutaneous radiofrequency neurotomy. Introduced in 1980 by Sluiter *et al.*,³ radiofrequency neurotomy has since been validated as an effective therapy for zygapophysial joint pain.⁴ Furthermore, third occipital neurotomy has been validated as an effective treatment for headache stemming from the C2-C3 zygapophysial joint, and mediated by the third occipital nerve.⁵

Pertinent to the conduct of diagnostic blocks and radiofrequency neurotomy is the innervation of the cervical zygapophysial joints. At levels below C2-C3, each joint is innervated by two medial branches of the posterior rami of the spinal nerves. The C2-C3 joint is exclusively innervated by a single one: the third occipital nerve, which is the superficial medial branch of the C3 dorsal ramus.⁶ This nerve also supplies a small patch of skin immediately below the occiput.

Because valid clinical or radiologic signs to identify the responsible joints are lacking, diagnostic blocks of the cervical medial branches are the only method to diagnose zygapophysial joint pain.^{7,8} Because the false-positive rate of a single block is 38%,⁹ a second confirmatory block should be performed on a different day to minimize the chance of obtaining a false-positive response.¹⁰ Radiofrequency neurotomy is indicated only if a positive response is obtained after both injections.

Medial branch blocks are currently performed under fluoroscopic control. Because several blocks are often needed to identify the symptomatic joint or to rule out zygapophysial joint pain, the procedure may expose patients and personnel to considerable radiation doses.¹¹ In contrast, ultrasound is not associated with exposure to radiation. Moreover, ultrasound guidance was recently found to be a possible alternative to fluoroscopy for the conduct of lumbar medial branch blocks.^{12,13}

The aim of this study was to develop a new method to block the third occipital nerve with use of ultrasound. We sought to answer whether the third occipital nerve can be directly visualized by ultrasound and accurately blocked with local anesthetic using ultrasound guidance. To this end, we conducted a double-blind, placebo-controlled, crossover trial in volunteers and confirmed the position of the ultrasound-guided needle with fluoroscopy.

* Staff Anesthesiologist, ** Associate Professor, Department of Anesthesiology, Division of Pain Therapy, § Staff Neuroradiologist, || Associate Professor, Department of Neuroradiology, University of Bern, Inselspital. † Staff Anesthesiologist, Department of Anesthesiology and General Intensive Care, Division B, ‡ Associate Professor, Department of Anesthesiology and General Intensive Care, Division A, Medical University of Vienna, Vienna, Austria. # Professor, Department of Clinical Research, Royal Newcastle Hospital, Newcastle, Australia.

Received from the Department of Anesthesiology, Division of Pain Therapy, University of Bern, Inselspital, Bern, Switzerland. Submitted for publication February 8, 2005. Accepted for publication September 1, 2005. Supported by the Department of Anesthesiology, University of Bern, Inselspital, Bern, Switzerland. No other funding was received for this study and the authors confirm there are no financial or any other conflicts of interest.

Address correspondence to Dr. Eichenberger: Department of Anesthesiology, University of Bern, Inselspital, CH-3010 Bern, Switzerland. urs.eichenberger@insel.ch. Individual article reprints may be purchased through the Journal Web site, www.anesthesiology.org.

Materials and Methods

After approval of the study by the ethics committee of the University of Bern, Bern, Switzerland, written informed consent was obtained from 14 healthy paid volunteers. Exclusion criteria were age less than 18 yr or more than 70 yr, a history of alcohol abuse or intake of psychotropic drugs, intake of nonsteroidal antiinflammatory drugs during the week preceding the study, coagulation abnormalities, a history of coronary artery disease, allergy to local anesthetics, possible pregnancy, bacterial infection (systemic or in the cervical region), or fever of unknown origin.

The first 3 volunteers were planned as pilot cases for the needle placement procedure. In these subjects, we did not inject any solution after needle placement, whereas the ultrasound measurements were performed.

The remaining 11 volunteers were randomized by drawing lots to receive local anesthetic or placebo (normal saline) injection at the left or the right side of the neck in a double-blinded fashion. After a minimal time interval of 4 h, the injection was performed on the other side in the same volunteer. All procedures were performed by one single physician (U. E.) experienced in sonography and in ultrasound-guided nerve blocks. In total, we performed 28 needle placements and planned 22 injections.

Before all injections, pinprick and cold tests in the small skin region over the rostral end of the neck and the occiput below the external occipital protuberance were performed because this skin region constitutes the sensory cutaneous distribution of the third occipital nerve.

The volunteers were placed in the left or right lateral decubitus position on a biplane Angio-G-Ring Station (CAS 500; Toshiba Inc., Tokyo, Japan). High-resolution ultrasound imaging was performed using a Sequoia 512[®] Ultrasound System with a 14-MHz high-resolution linear ultrasound transducer with a maximal axial resolution of 0.28 mm and a maximal horizontal resolution of 0.42 mm (15L8w; Acuson Corporation, Mountain View, CA). To maintain sterility, the ultrasound transducer was wrapped with a sterile, disposable, latex-free glove (Sempermed Supreme; Sempermed Inc., North-Clearwater, FL), and sterile ultrasound coupling gel (produced by the hospital pharmacy) was used.

We started with the ultrasound examination just caudal to the mastoid process exactly perpendicular to the lateral aspect of the neck in an almost transverse plane. Moving the transducer slowly caudally, the lateral mass of the axis and more caudally the most superficial situated bony landmark of the upper cervical spine, *i.e.*, the transverse process of C1, are easily visible. Moving the transducer only 1–3 mm more caudally, the vertebral artery appears at the same anteroposterior location in the picture as the transverse process of C1 before. By following this artery caudally, one can see the bony

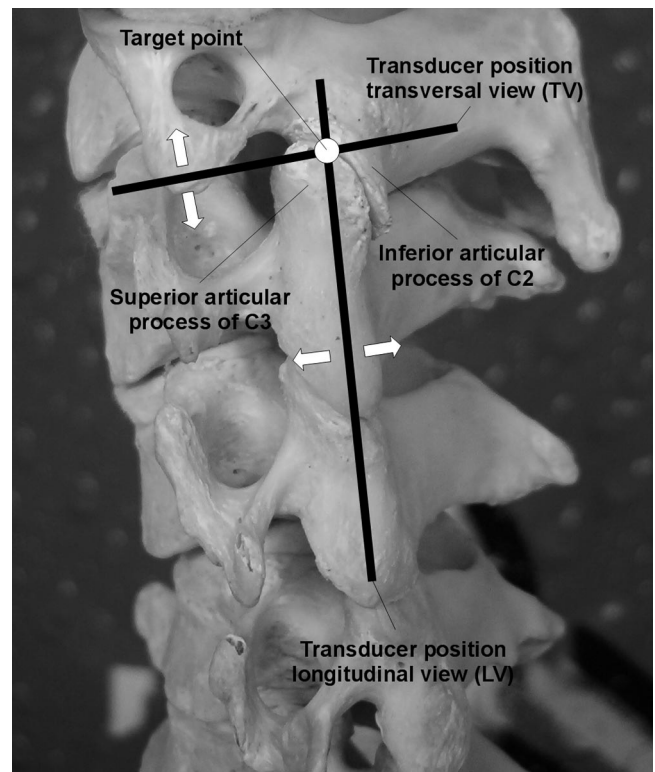
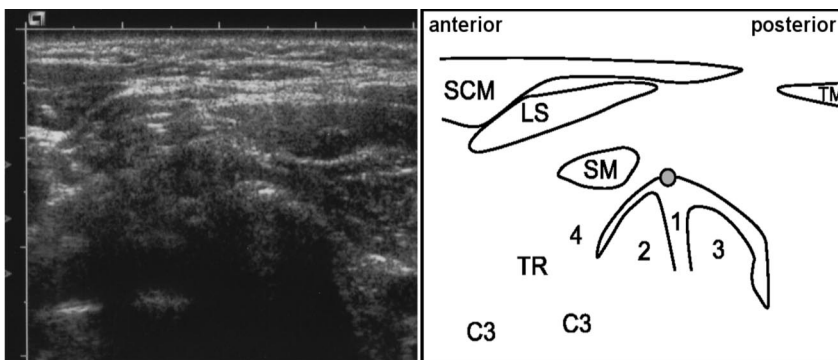


Fig. 1. Cervical spine (C2–C5): Transducer alignment in relation to the cervical spine for ultrasound-guided third occipital nerve block in the transverse view (TV) and the longitudinal view (LV). The circle indicates the target point. The third occipital nerve crosses the articulation C2–C3 in an anterior–posterior direction at the target point. The white arrows indicate the movements of the transducer during examination of the neck cranial–caudal in the TV and anterior–posterior in the LV.

landmarks of the C1–C2 zygapophysial joint several millimeters posterior to the artery location. Some millimeters more caudally, the vertebral artery disappears in the transverse foramen of C2, and the C2–C3 joint appears posteriorly. The approximate position of the ultrasound transducer at this point is illustrated in figure 1. Slight rotational movements of the transducer were executed until the typical, transverse, cross-sectional appearance of the C2–C3 joint was found (fig. 2). In this view, the joint presents as a convex density covered by the laminated densities of the overlying posterolateral neck muscles. The apex of the convexity of the joint was identified and constituted the target point for the ensuing needle insertion, in accord with the standard fluoroscopic block technique.⁸ The depth of this point from the skin was measured and recorded.

Thereafter, the transducer was rotated 90° to obtain a longitudinal view. Figure 1 shows the orientation of the ultrasound transducer, and figure 3 shows the appearance of a longitudinal view. Because it is known that the third occipital nerve crosses the C2–C3 zygapophysial joint in this plane at an average distance of 1 mm from the bone,¹⁴ we searched for the typical sonomorphologic appearance of a small peripheral nerve at this

Fig. 2. Ultrasound image transversal view (TV) as shown in figure 1 of the C2–C3 zygapophysial joint. The gray circle indicates the target point for the needle tip during the ultrasound-guided needle placement for third occipital nerve block. 1 = C2–C3 joint line; 2 = superior articular process of C3; 3 = inferior articular process of C2; 4 = intervertebral foramen of C2–C3; C3 = white reflex of the surface of the vertebral body of C3; LS = levator scapulae muscle; SCM = sternocleidomastoid muscle; SM = scalenus medius muscle; TM = trapezius muscle; TR = ultrasound shadow of the transverse process of C2.



location. A peripheral nerve crossing the ultrasound plane at an angle of approximately 90° , as in the current case, can be identified better than one running longitudinally along the plane of view. It appears typically as an oval hypoechoic area with hyperechoic spots encircled by a hyperechoic horizon.^{15–17} The depth and diameter of this structure were measured, and the location of the nerve in relation to the joint line (cranial, over, or caudal to the line), was recorded, whenever the joint line was visible.

The bony surfaces were scanned again in a transverse plane by ultrasound as described above. In this view, a 22-gauge, 40-mm spinal needle (UNIEVER, point K3; UNISIS Corp., Tokyo, Japan) was introduced from immediately below the ultrasound probe and advanced perpendicular to the beam (“short axis”) just over the apex of the convexity of the joint, until its tip appeared in the ultrasound plane. Once seen, the needle was advanced under ultrasound guidance toward the target point, until bony resistance was encountered. Then the transducer was rotated to the longitudinal plane because in this view the nerve is best visualized; the third occipital nerve was located; and the needle was adjusted to lie closer to the nerve.

The standard technique for blocking the third occipital nerve under fluoroscopy is designed to accommodate both the relatively large size of the nerve and variations in its location.¹⁴ The technique requires the injection 0.3 ml local anesthetic onto each of three target points and has been validated.⁸ The points are located along a vertical line through the middle of the C2–C3 joint, at levels opposite the apex of the C3 superior articular process, opposite the bottom of the C2–C3 interverte-

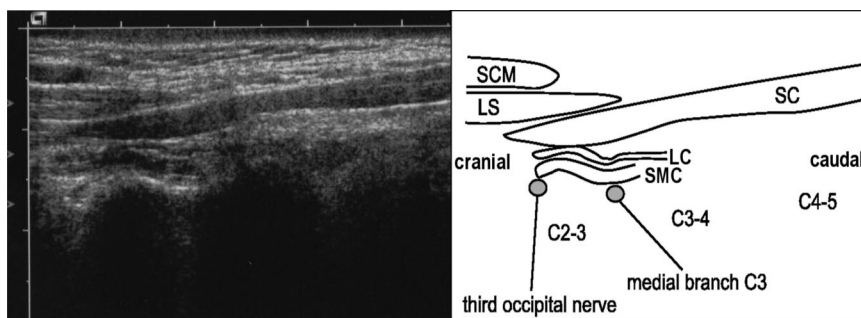
bral foramen, and midway between these two extremes. In the current study, because the target nerve could be visualized under ultrasound, multiple blocks were not required to accommodate possible variations in location. Accordingly, the ultrasound-guided block was condensed to a single injection of 0.9 ml lidocaine, 2% (Xylocain®; AstraZeneca AG, Zug, Switzerland), or normal saline at the one prescribed target point.

The solutions were prepared by a member of the research team who did not perform the injection. After each injection, the person performing the puncture left the room.

Plain radiographs of the position of the needle were obtained in anteroposterior and lateral views, complemented by a standardized calibration tool to adjust for different magnifications. The table positions and the bi-plane orientation of the volunteer's head were controlled by standardized absorbent head markers. Plain radiographs were analyzed by two trained neuroradiologists, and the position of the needle tip was plotted. The distance between the x-ray tube and a marker on the patient's skin (over the temporomandibular joint) was measured and used to correct any magnification effects. Then the distance between a predefined target point on the radiograph and the actual position of the needle tip was measured. We defined the radiologic target point arbitrarily as the intersection of a vertical line passing through the middle of the C2–C3 zygapophysial joint and an oblique line passing directly over the joint line. Subsequently, displacement of the needle from the target was quantified after correct for magnification effects.

The position of the needle was arbitrarily considered to be adequate if the total distance to the radiologic

Fig. 3. Ultrasound image longitudinal view (LV) as shown in figure 1 along the articular pillars from C2 to C5. LC = longissimus capitis muscle; LS = levator scapulae muscle; SC = splenius capitis muscle; SCM = sternocleidomastoid muscle; SMC = semispinalis capitis muscle.



target point was not greater than 5 mm. We based this distance on the results of the study by Barnsley *et al.*⁸ regarding the spread of contrast medium after C2-C3 medial branch blocks. The blockade was considered clinically successful if pinprick and cold testing showed anesthesia in the skin area innervated by the third occipital nerve after lidocaine, but no anesthesia or hyposensitivity after saline. This sensory assessment was performed 30 min after each injection.

Statistics

The statistical analysis was based on intent to treat. Data are presented as median and range if not otherwise stated. We only used descriptive statistics to present data.

Results

The median age of the volunteers (10 women, 4 men) was 28.4 yr (range, 21.4–44.6 yr), and the median body mass index was 21.6 kg/m² (range, 18.1–26.0 kg/m²). In all 14 volunteers, cervical ultrasound examination was feasible, and the third occipital nerve was successfully visualized in 27 of 28 cases. In most cases, the third occipital nerve was seen as an oval hypoechoic structure with hyperechoic small spots inside (fig. 3). The median diameter of the third occipital nerve was 2.0 mm (range, 1.0–3.0 mm), and we found the nerve at a median depth of 20.8 mm (range, 14.0–27.0 mm).

In one volunteer, the formation of a small subcutaneous hematoma (2 × 2 × 0.5 cm) markedly reduced sonographic resolution deeper in the neck. No other complications or side effects occurred during the study. Because we could no longer clearly identify the third occipital nerve, which was lying directly behind the hematoma, the procedure was terminated, we did not advance the needle further, and we did not inject the solution (local anesthetic according to the randomization). Radiologic control showed that the initial puncture site was located at the correct level (C2–C3 articulation), but the needle tip was too superficial to measure the exact distance to the target point. In regard to the intent-to-treat analysis, the needle placement of this case was counted as missing the radiologic target. In the first 3 volunteers (predefined as pilot cases), we did not inject any solution after needle placements. Therefore, we analyzed radiologic data (distance of needle tip to the radiologic target on the radiograph) in 28 attempts and clinical data (anesthesia in the skin area of the third occipital nerve) in 11 volunteers, *i.e.*, 21 injections.

During injection of local anesthetic or saline, we could follow the expansion of the tissue around the third occipital nerve in most cases. The spread of the fluid around the nerve could not be visualized in all cases because of artifacts caused by small amounts of injected

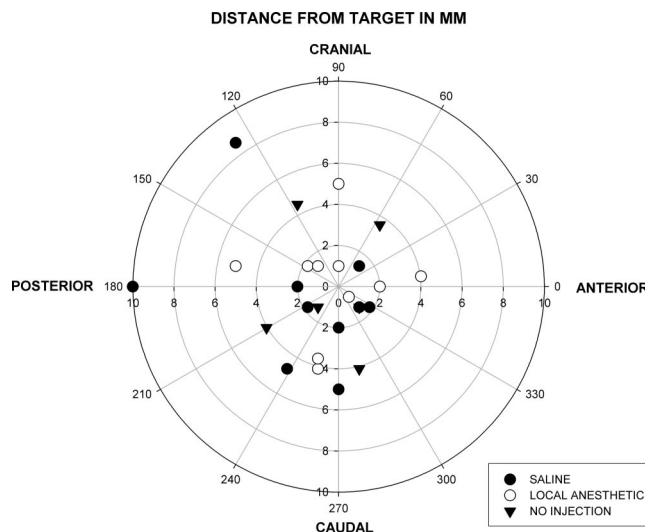


Fig. 4. The graph shows the position of the needle tips in relation to the target point confirmed by fluoroscopy, which is represented in the center of the graph. Distances along the vertical and horizontal axes are given in millimeters. The case in which we did not target the right joint and the case with subcutaneous hematoma formation are not included.

air (bubbles) trapped in the solution or unintentional small displacement of the transducer.

Anesthesia in the corresponding skin area to pinprick or cold testing developed in 9 of 10 cases after the injection of lidocaine. In the only case with no anesthesia after local anesthetic, the needle tip was within a 2-mm radius around the radiologic target point on the radiograph, *i.e.*, 1 mm cranial and 1 mm posterior. In none of the 11 cases after saline injection did we observe anesthesia or a difference in sensory testing compared with testing before the injection.

The radiologic analysis of the needle positions showed that we localized the C2–C3 zygapophysial joint correctly in 27 of 28 cases. In one case, we mistook the C3–C4 joint for the C2–C3 joint. Ultrasound measurements of this case were not included. This is why the third occipital nerve was correctly identified in only 27 of 28 cases, as stated above.

In 23 of the 28 approaches, needle placement was within the defined maximal 5-mm distance from the radiologic target point. Figure 4 shows the measured distance of the needle tip from the radiologic target point of 26 punctures.

We were able to associate the course of nerve with the joint line in 18 of the 22 cases (we did not ascertain these data in the 3 pilot cases). The nerve was localized sonographically cranial to the joint line in 6 cases, on the joint line in 3 cases, and caudal to the joint line in 9 cases. In 4 cases, we could not unmistakably localize the joint line, and therefore, any correlation of the third occipital nerve to it was impossible. On the radiograph, the needle tip was located on the same side (cranial or caudal) of the joint line as localized by ultrasound in 13

of 18 cases. In 3 of the remaining 5 cases, the nerve was seen directly on the joint line by ultrasound.

Discussion

The current study demonstrates, for the first time, that the third occipital nerve can be visualized under ultrasound. It was seen in 27 of 28 cases. The one omission occurred as the result of mistaking the C3–C4 joint for the C2–C3 joint. When evident, the nerve appeared to be 2 mm in diameter, which compares favorably with the diameter (1.5 mm) obtained from direct measurements in cadavers.¹⁴ The discrepancy can be explained on the grounds that the outer boundaries of nerves are difficult to define under ultrasound because of the similar sonographic appearance of the epineurium and surrounding fat.¹⁷

Nerves are difficult to identify on static ultrasound images, but ultrasound is a dynamic examination. Knowing the expected location and sonographic appearance of the nerve and using slow movements of the transducer along its course is the key to detecting small nerves. Although they may appear inhomogeneous—from hypoechoic to hyperechoic, depending on the surrounding tissue and the angle of the probe—the fascicular sonographic appearance of peripheral nerves is a constant finding.¹⁶

In the current study, the nerve was found in the range of locations described for it in anatomical studies.¹⁴ Twelve of the 26 needle tips were within 2 mm of the radiologic midpoint of the C2–C3 zygapophysial joint, which corresponds to the middle of the three target points advocated for this nerve when fluoroscopically guided blocks are performed. A further 11 needle tips were within 5 mm of this point. In only two cases was the needle tip identified more than 8 mm from this central point. Unfortunately, those two cases were in patients who were injected with normal saline. Therefore, it is not possible to report whether blocks at these distant points would have been successful.

In the 10 cases in which the local anesthetic was used, a successful block was achieved in 9. In the one exception, the nerve was found, and the needle was placed within 1 mm above and 1 mm posterior to the radiologic target point. Under those conditions, it seems unlikely that 0.9 ml local anesthetic could have failed to reach the nerve. Inadvertent vascular uptake of the injected solution would seem to be the likely explanation of the failure to obtain a block. Because we could not see the local anesthetic reaching the nerve by ultrasound in this special case, spread of the local anesthetic away from the nerve is another possible explanation.

Together, the radiographic accuracy in 23 of 28 needle placements and the clinical success in 9 of 10 blocks strongly suggest that third occipital nerve blocks can be accurately performed under ultrasound guidance. Ethical

considerations precluded using a greater number of healthy volunteers to achieve a larger sample size. The high yield in the small sample size, we submit, may be nonetheless sufficient for us to adopt the technique in patients, and perhaps for others also to do so.

There is every prospect that better and more consistent results could be obtained as ultrasound technology improves. Newer devices provide greater resolution and require smaller transducers. In the current study, accuracy was restricted by the size of the transducer available and used (6 cm). Optimally, needles should be directed onto the third occipital nerve under longitudinal view, in which the nerve is best seen (*i.e.*, in transverse section). However, in this view, the transducer must be moved cranial to the target point, to allow the needle to be admitted below it. But when the transducer measures 6 cm, the mandible and mastoid process prevent it from moving sufficiently cranially to admit a needle. Therefore, in the current study, we were obliged to use a transverse view to insert the needle. No longer able to see the nerve directly, we had to adjust the needle, in the anteroposterior direction, toward the estimated location of the no-longer-visible nerve. Thereafter, the transducer had to be rotated 90° to adjust the needle in the craniocaudal direction and to bring the needle tip close to the now-visible nerve. This two-step maneuver could explain some of the displacements of the needle from the ideal target point. A 3-cm transducer would overcome this limitation. With a 3-cm transducer, a needle could be inserted in the longitudinal view in which the nerve was clearly apparent.

The conventional, fluoroscopically guided technique for third occipital blocks requires needle placements onto three target points, each injected with 0.3 ml local anesthetic. These requirements were developed because under fluoroscopy the nerve is not evident, and the blocks must accommodate all variations in the location of the nerve, from over the joint line to substantially above it or substantially below it. Ultrasound guidance overcomes this requirement for multiple placements. Because the nerve can be seen, the needle can be aimed directly onto it. Additional measures to accommodate possible variations in location are not required. The promise that ultrasound offers, therefore, is that the blocks can be made faster as well as more accurate.

In one volunteer, the formation of a small subcutaneous hematoma markedly reduced sonographic resolution deeper in the neck. Hematoma formation may also occur during x-ray-guided third occipital nerve block but does not reduce the visibility of the needle tip in this case. Therefore, this possible complication may be one of the limitations of the ultrasound-guided technique.

In the current study, a volume of 0.9 ml was used to secure the block. This volume was selected because it amounts to the total volume used with the fluoroscopically guided technique. Although perhaps small in an absolute sense, this is a relatively large volume in the

context of spinal blocks. Even 0.5 ml spreads a long way from the target point for third occipital and cervical medial branch blocks.⁸ However, this spread may account for why blocks were successful in the five cases in the current study when the needle was placed several millimeters from the central target point. But extensive spread means that much of the injected solution no longer remains in the relevant target area, which makes much of the volume redundant. The possibility exists that blocks could still be effective if lesser volumes were used, if the needle was placed directly on the nerve, under ultrasound guidance. This is a prospect that could be explored in the future.

Perhaps the most attractive aspect of ultrasound-guided blocks is that they are safer and require less elaborate equipment. Ultrasound guidance avoids radiation exposure and can be performed outside lead-shielded facilities. Ultrasound equipment is generally more widely available than C-arm or biplanar fluoroscopes. The latter consideration could make third occipital blocks more readily available to patients with headache of cervical origin.

In that regard, the results of the current study are an encouraging first step that others might care to follow and evaluate. One caution remains, however. The current study was conducted in individuals of average size and normal weight, without significant degenerative changes of the cervical spine. Whether ultrasound guidance is practical in larger individuals is yet to be determined and should be the subject of future studies.

The authors thank Jürg Imobersteg, C.R.N.A. (Department of Anesthesiology, University Hospital of Bern, Inselspital, Bern, Switzerland), for logistical support.

References

1. Radanov BP, Sturzenegger M, Di Stefano G: Long-term outcome after whiplash injury: A2-year follow-up considering features of injury mechanism and somatic, radiologic, and psychosocial findings. *Medicine (Baltimore)* 1995; 74: 281-97
2. Lord SM, Barnsley L, Wallis BJ, Bogduk N: Chronic cervical zygapophysial joint pain after whiplash: A placebo-controlled prevalence study. *Spine* 1996; 21:1737-45
3. Sluiter ME, Koetsveld-Baart CC: Interruption of pain pathways in the treatment of the cervical syndrome. *Anaesthesia* 1980; 35:302-7
4. Lord SM, Barnsley L, Wallis BJ, McDonald GJ, Bogduk N: Percutaneous radio-frequency neurotomy for chronic cervical zygapophysial-joint pain. *N Engl J Med* 1996; 335:1721-6
5. Govind J, King W, Bailey B, Bogduk N: Radiofrequency neurotomy for the treatment of third occipital headache. *J Neurol Neurosurg Psychiatry* 2003; 74:88-93
6. Bogduk N: The clinical anatomy of the cervical dorsal rami. *Spine* 1982; 7:319-30
7. Barnsley L, Lord S, Bogduk N: Comparative local anaesthetic blocks in the diagnosis of cervical zygapophysial joint pain. *Pain* 1993; 55:99-106
8. Barnsley L, Bogduk N: Medial branch blocks are specific for the diagnosis of cervical zygapophysial joint pain. *Reg Anesth* 1993; 18:343-50
9. Barnsley L, Lord S, Wallis B, Bogduk N: False-positive rates of cervical zygapophysial joint blocks. *Clin J Pain* 1993; 9:124-30
10. Bogduk N: International Spinal Injection Society guidelines for the performance of spinal injection procedures: I. Zygapophysial joint blocks. *Clin J Pain* 1997; 13:285-302
11. Fishman SM, Smith H, Meleger A, Seibert JA: Radiation safety in pain medicine. *Reg Anesth Pain Med* 2002; 27:296-305
12. Greher M, Kirchmair L, Enna B, Kovacs P, Gustorff B, Kapral S, Moriggl B: Ultrasound-guided lumbar facet nerve block: Accuracy of a new technique confirmed by computed tomography. *ANESTHESIOLOGY* 2004; 101:1195-200
13. Greher M, Scharbert G, Kamolz LP, Beck H, Gustorff B, Kirchmair L, Kapral S: Ultrasound-guided lumbar facet nerve block: A sonoanatomic study of a new methodologic approach. *ANESTHESIOLOGY* 2004; 100:1242-8
14. Lord SM, McDonald GJ, Bogduk N: Percutaneous radiofrequency neurotomy of the cervical medial branches: A validated treatment for cervical zygapophysial joint pain. *Neurosurgery Quarterly* 1998; 8:288-308
15. Fornage BD: Peripheral nerves of the extremities: Imaging with US. *Radiology* 1988; 167:179-82
16. Silvestri E, Martinoli C, Derchi LE, Bertolotto M, Chiamondia M, Rosenberg I: Echotexture of peripheral nerves: Correlation between US and histologic findings and criteria to differentiate tendons. *Radiology* 1995; 197:291-6
17. Martinoli C, Bianchi S, Dahmane M, Pugliese F, Bianchi-Zamorani P, Valle M: Ultrasound of tendons and nerves. *Eur Radiol* 2002; 12:44-55