

Effect of Lateral Positioning on Upper Airway Size and Morphology in Sedated Children

Ronald S. Litman, D.O.* Nicole Wake, B.A.,† Lai-Ming Lisa Chan, B.S.,† Joseph M. McDonough, M.S.,‡ Sanghun Sin, M.S.,‡ Soroosh Mahboubi, M.D.,§ Raanan Arens, M.D.||

Background: Lateral positioning decreases upper airway obstruction in paralyzed, anesthetized adults and in individuals with sleep apnea during sleep. The authors hypothesized that lateral positioning increases upper airway cross-sectional area and total upper airway volume when compared with the supine position in sedated, spontaneously breathing children.

Methods: Children aged 2–12 yr requiring magnetic resonance imaging examination of the head or neck region using deep sedation with propofol were studied. Exclusion criteria included any type of anatomical or neurologic entity that could influence upper airway shape or size. T1 axial scans of the upper airway were obtained in the supine and lateral positions, with the head and neck axes maintained neutral. Using software based on fuzzy connectedness segmentation (3D-VIEWNIX; Medical Imaging Processing Group, University of Pennsylvania, Philadelphia, PA), the magnetic resonance images were processed and segmented to render a three-dimensional reconstruction of the upper airway. Total airway volumes and cross-sectional areas were computed between the nasal vomer and the vocal cords. Two-way paired *t* tests were used to compare airway sizes between supine and lateral positions.

Results: Sixteen of 17 children analyzed had increases in upper airway total volume. The total airway volume (mean \pm SD) was 6.0 ± 2.9 ml³ in the supine position and 8.7 ± 2.5 ml³ in the lateral position ($P < 0.001$). All noncartilaginous areas of the upper airway increased in area in the lateral compared with the supine position. The region between the tip of the epiglottis and vocal cords demonstrated the greatest relative percent change.

Conclusions: The upper airway of a sedated, spontaneously breathing child widens in the lateral position. The region between the tip of the epiglottis and the vocal cords demonstrates the greatest relative percent increase in size.

ONE of the most important side effects of the use of anesthetic or sedative agents in children is respiratory

depression. This depression, which is manifested as decreased respiratory drive and often the inability to maintain a patent upper airway, can lead to life-threatening hypoxemia. Traditionally, the ability of an anesthetic agent to cause respiratory depression has been quantitatively described by measuring its effects on resting carbon dioxide concentrations and its ability to alter the normal ventilatory response to hypoxia and hypercapnia.^{1,2} However, it has become increasingly clear that these parameters are not clinically useful because apnea and upper airway obstruction are more important causes of hypoxemia, especially in children.³

Researchers in the area of sleep apnea have determined a variety of factors that may decrease upper airway obstruction in susceptible subjects. One of these factors is positioning. Lateral positioning decreases upper airway obstruction in sleeping individuals,^{4,5} anesthetized children breathing spontaneously,⁶ and paralyzed adults during general anesthesia.⁷ The mechanism of this phenomenon is unknown and presumed to be secondary to gravitational effects.

The primary aim of this study was to determine the changes in upper airway anatomy that occur when sedated, spontaneously breathing children are placed in the lateral position. We hypothesized that lateral positioning increases upper airway cross-sectional area and total upper airway volume when compared with the supine position.

To determine positional changes in upper airway morphology, we used a magnetic resonance (MR) imaging technique that allows three-dimensional characterization of upper airway structures. This methodology, which was developed at the University of Pennsylvania and The Children's Hospital of Philadelphia (Philadelphia, Pennsylvania), uses fuzzy connectedness-based automatic segmentation and minimum-cost-path centerline determination, which allows quantification of the upper airway cross-sectional area in a correct anatomical orientation as it relates to airflow.^{8,9} We used this methodology to determine the conformational changes that occur in the upper airway of anesthetized children when they are placed in the lateral position.

Materials and Methods

Children aged 2–12 yr requiring MR examination of the head or neck region using deep sedation with propofol were eligible for inclusion. The protocol was approved by The Children's Hospital of Philadelphia Department of Radiology Research Review Board and the

* Associate Professor of Anesthesiology and Pediatrics, University of Pennsylvania School of Medicine, Philadelphia, Pennsylvania, and The Children's Hospital of Philadelphia. † Research Associate, Department of Anesthesiology and Critical Care. ‡ Research Associate, Department of Pediatrics, The Children's Hospital of Philadelphia. § Professor, Departments of Radiology and Pediatrics, University of Pennsylvania School of Medicine, Philadelphia, Pennsylvania, and The Children's Hospital of Philadelphia. || Associate Professor of Pediatrics, University of Pennsylvania School of Medicine, Philadelphia, Pennsylvania, and The Children's Hospital of Philadelphia.

Received from the Departments of Anesthesiology, Pediatrics, and Radiology, The Children's Hospital of Philadelphia, Philadelphia, Pennsylvania. Submitted for publication February 24, 2005. Accepted for publication May 17, 2005. Supported by Children's Anesthesia Associates, Philadelphia, Pennsylvania; the Department of Anesthesiology and Critical Care (Drs. Litman, Wake, and Chan) and the Department of Radiology (Dr. Mahboubi), The Children's Hospital of Philadelphia, Philadelphia, Pennsylvania; and grant No. HL-62408 from the National Institutes of Health, Bethesda, Maryland (Drs. Arens, McDonough, and Sin). Presented in part at the Annual Meeting of the Society of Pediatric Anesthesia, Miami Beach, Florida, February 25, 2005, and the Annual Meeting of the Association of University Anesthesiologists, Baltimore, Maryland, May 5, 2005.

Address reprint requests to Dr. Litman: Department of Anesthesiology and Critical Care Medicine, The Children's Hospital of Philadelphia, 34th Street and Civic Center Boulevard, Philadelphia, Pennsylvania 19104. Address electronic mail to: litmanr@email.chop.edu. Individual article reprints may be purchased through the Journal Web site, www.anesthesiology.org.

institutional review board. Written consent was obtained from all parents, and verbal assent was obtained from children when appropriate. Exclusion criteria included acute or chronic lung disease, upper airway disease or dysfunction of any kind, heart disease, obesity (body weight > 90th percentile for age), known sleep apnea syndrome, central nervous system disease likely to influence muscle tone, any type of abnormality in neck anatomy, or the requirement for any type of airway adjunct device (e.g., oral airway, endotracheal tube).

Children were anesthetized before the MR scan with 8% sevoflurane in 70% N₂O or with intravenously administered propofol if an indwelling intravenous catheter was present. Maintenance of deep sedation was accomplished using propofol at a starting dose of 200 $\mu\text{g} \cdot \text{kg}^{-1} \cdot \text{min}^{-1}$ and titrated based on maintenance of unconsciousness (e.g., lack of spontaneous limb movement) and normal hemodynamic and ventilatory parameters (e.g., within 20% of baseline values). All children breathed spontaneously without assistance throughout the entire anesthetic. Supplemental oxygen was administered by nasal cannula with a capnograph attachment (2 or 3 l/min) in all cases. After completion of the clinically indicated scans, the study protocol was performed while the child remained in the supine position. The head and neck rested in the neutral position on a small blanket, without obvious flexion, extension, lateral flexion, or lateral rotation. The degree of mouth opening was not controlled in either position.

The study protocol consisted of T1 axial scans of the upper airway (based on a sagittal scout scan) in 3-mm slices without a gap. We used a 1.5-T Vision System MR (Siemens, Iselin, NJ), and images were acquired using an anterior-posterior volume head coil. The cephalad border consisted of the top of the nasal cavity, and the caudad border consisted of the subglottic region below the vocal cords. The time to completion of the study scan was approximately 5 min. At the completion of the airway scan in the supine position, each subject was turned laterally (based on a randomization scheme for each episode) on the MR gurney. Extreme care was taken to ensure that the head and neck were maintained in the neutral position, without flexion, extension, lateral flexion, or lateral rotation. All other body parts were appropriately protected, while the child's body was maintained in a plane at 90° to the axis of the table. When the child was secured in this manner, the upper airway scans were repeated using the same protocol as for the supine scans.

After the study scans, the MR images were saved and transferred to a UNIX-based Sun workstation (Sun Microsystems, Santa Clara, CA) where the images were processed and segmented automatically to render a three-dimensional reconstruction of the upper airway, including its surface description, centerline, and volume. This was accomplished using a software program (3D-VIEWNIX;

Medical Imaging Processing Group, University of Pennsylvania, Philadelphia, PA) that uses fuzzy connectedness segmentation.^{10,11} A centerline through the airway is computed that passes through all points maximally distant from the perimeter of the airway at sequential planes orthogonal to the airway axis. The total upper airway volume was computed as a product of the centerline length and the mean cross-sectional area. Cross-sectional areas at planes orthogonal to the centerline were computed every 0.2 mm after interpolation, filtering, and thresholding of the original axial slices. We defined the cephalad border of the upper airway by the posterior edge of the vomer and used the vocal cords as a lower landmark with which to divide the upper airway into 10 consecutive (10%) equidistant intervals along the centerline to facilitate analysis and comparison between body positions. Only airflow-conducting portions of the upper airway are used for the analysis of volume and cross-sectional area.

Sample Size and Statistical Analysis

Data from previous studies indicated that in normal children, the mean cross-sectional area of the upper airway is $47.1 \pm 18.2 \text{ mm}^2$ (mean \pm SD).¹² We considered a 30% change in upper airway cross-sectional area to represent a clinically important change. Based on this premise, a sample size of 16 would have 80% power to detect a difference in means of 14 mm^2 using a paired *t* test with a 0.05 two-sided significance level. We determined differences in total airway volume and cross-sectional areas at multiple levels of the pharynx using two-sided paired *t* tests.

Results

Nineteen children enrolled into the study; however, the data on one child was accidentally lost in the transfer process, and another child did not have study data collected because of copious secretions and frequent coughing during the clinically indicated scan. Therefore, adequate data were collected on 17 children (10 in the left lateral decubitus position, 7 in the right). There were 9 boys and 8 girls. Their ages ranged from 2 to 11 yr (mean \pm SD, 5.4 ± 2.2 yr), and their weights ranged from 11.1 to 52.0 kg (mean \pm SD, 20.1 ± 10.1 kg). Table 1 lists each patient and his or her diagnosis. All subjects except two received sevoflurane for induction of general anesthesia. There were no complications or adverse events during the clinical or study scans. No child demonstrated obvious upper airway obstruction, and no child experienced oxyhemoglobin desaturation (< 95% oxygen saturation measured by pulse oximetry) at any time during the scans.

The separate results from the right and left lateral positions were similar and were therefore combined for the final analysis. Sixteen of the 17 subjects had in-

Table 1. Characteristics of All Study Subjects

Subject	Sex	Age, yr	Weight, kg	Diagnosis	Lateral Decubitus Position
1	M	4	14.6	Neurofibromatosis	Left
2	M	5	15.0	Factor IX deficiency	Right
3	F	4	17.4	Developmental delay	Left
4	M	7	31.4	Astrocytoma	Left
5	M	7	17.0	PNET	Left
6	F	3	13.5	Temporal glioma	Right
7	F	4	15.0	Neck skin lesion	Left
8	F	5	16.8	Seizure disorder	Right
9	F	5	12.0	PNET	Left
10	M	8	23.0	Seizure disorder	Right
11	F	6	24.7	Neurofibromatosis	Right
12	F	11	52.0	Neurofibromatosis	Left
13	F	7	18.6	Cranial nerve III palsy	Left
14	M	4	18.0	Nasal pit	Left
15	M	2	11.1	Ependymoma	Left
16	M	2	12.1	Neurofibromatosis	Right
17	M	7	30.0	Neurofibromatosis	Right

PNET = primitive neuroectodermal tumor.

creases in total upper airway volume when placed in the lateral position. As a group, the total airway volume was $6.0 \pm 2.9 \text{ mL}^3$ in the supine position (mean \pm SD) and $8.7 \pm 2.5 \text{ mL}^3$ (mean \pm SD) in the lateral position ($P < 0.001$; fig. 1). Figure 2 illustrates the reconstruction of the total upper airway in both body positions in one subject using 3D-VIEWNIX.

All noncartilaginous cross-sectional areas of the upper airway increased in area in the lateral compared with the supine position (fig. 3). The region between the tip of the epiglottis and vocal cords demonstrated the greatest relative percent change.

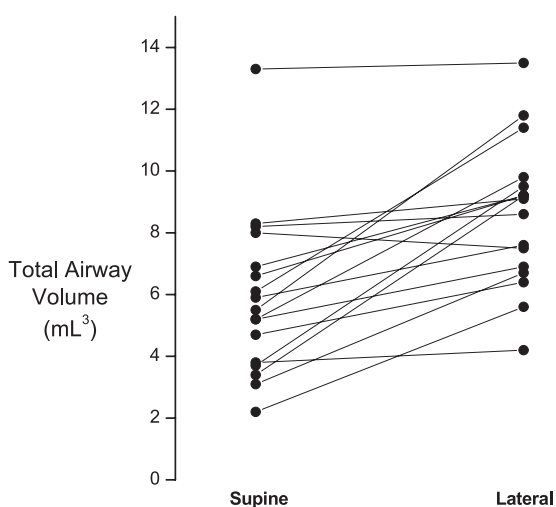


Fig. 1. Sixteen of 17 children had increased volumes in the lateral when compared with the supine position. Total upper airway volume (mm^3) was significantly greater in the lateral position ($P < 0.001$).

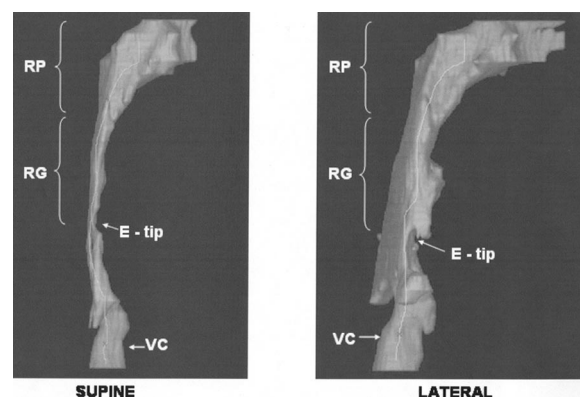


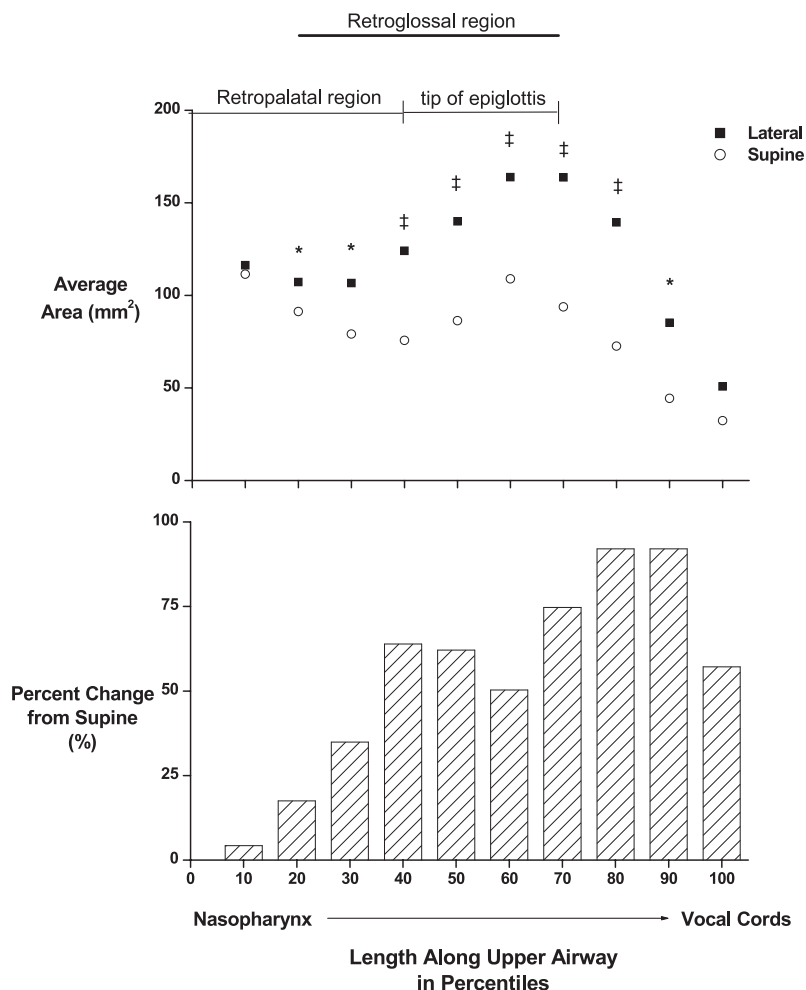
Fig. 2. One subject's reconstruction of the upper airway in the supine and lateral positions. The centerline passes through all points maximally distant from the perimeter of the airway at sequential planes orthogonal to the airway axis. E-tip = tip of the epiglottis; RG = retroglossal region (*i.e.*, oropharynx); RP = retropalatal region (*i.e.*, nasopharynx); VC = vocal cords (also indicated by the small x in the center of the airway).

Discussion

Using MR analysis of upper airway morphology, we demonstrated that placement of a sedated, spontaneously breathing child in the lateral position enlarges the upper airway. Although all noncartilaginous areas of the upper airway became significantly larger, the level at or below the tip of the epiglottis demonstrated the largest relative percent change. Isono *et al.*⁷ studied this phenomenon in paralyzed adult patients and reasoned that in the supine position, gravity caused the upper airway to be more constrained by surrounding anatomical structures when compared with the lateral position. More detailed examination of the MR images (fig. 4) revealed that the base of the tongue seemed to be in direct contact with the anterior surface of the epiglottis and thus may have been responsible for posterior displacement of the epiglottis with resultant narrowing of the airway in this region. In some children sedated with propofol, the region of most narrowing within the upper airway lies at the level of the epiglottis.¹³ Lateral positioning decreased this area of narrowing, presumably by a gravitational effect. However, our methodology was not able to determine the cause of the airway narrowing in the supine position, and there may be other factors that influence airway size, such as changes in tissue and airway compliance at any level of the upper airway that occur with the change in position. Our findings provide a possible explanatory mechanism for the alleviation of upper airway obstruction by application of manual anterior mandibular advancement (jaw thrust) in sedated children.¹⁴ Furthermore, our results provide further justification of lateral positioning in sleeping or sedated children with congenital laryngomalacia.

Clinically, these results indicate that less upper airway narrowing may occur when spontaneously breathing

Fig. 3. Comparison of average cross-sectional areas of the upper airway between supine and lateral positions as a function of location along the airway (*upper graph*). The *lower graph* demonstrates the percent change from the supine position and indicates that the region at or below the tip of the epiglottis changes the most from supine to lateral. The labels above the *upper graph* represent the ranges of upper airway levels across all subjects studied. The retropalatal region represents the nasopharynx and is defined as the area between the vomer and the base of the uvula. The retroglottal region represents the oropharynx and is defined as the area between the base of the uvula and the tip of the epiglottis. The region of the body of the epiglottis and arytenoids would be located below (*i.e.*, to the right on the graph) the bar labeled "tip of epiglottis." * $P < 0.05$. ‡ $P < 0.01$.



children undergo deep sedation in the lateral position. In pediatric anesthesia textbooks, the lateral position is often advocated for children after emergence from general anesthesia, based on clinical experience.¹⁵ Although a randomized clinical trial comparing supine and lateral positions has not yet been performed, some patients with sleep apnea syndrome demonstrate less upper air-

way obstruction when in the lateral position.^{4,5} Therefore, it is reasonable to conclude that semiconscious patients in the lateral position may demonstrate less upper airway obstruction.

Two of our subjects did not demonstrate an overall increase in upper airway volume after assumption of the lateral position. One was a 4-yr-old, 15-kg girl who was placed on her left side. Her diagnosis was a neck skin lesion that did not extend into the soft tissue of the neck. The reason her upper airway did not widen in the lateral position is otherwise unclear. The other patient was an 8-yr-old, 23-kg boy who was placed on his right side. This patient demonstrated larger than usual volumes in both supine and lateral positions when compared with the remainder of the study group (uppermost subject in fig. 1). Therefore, in retrospect, this subject had an unusually large upper airway of unknown etiology that may have influenced the results.

A possible limitation of this study is the lack of randomization of the order of the positions. In the context of the clinical situation, it was not practical to perform the clinically indicated MR scan initially supine, then turn half of the patients lateral and back to supine for the study scans. Because each patient

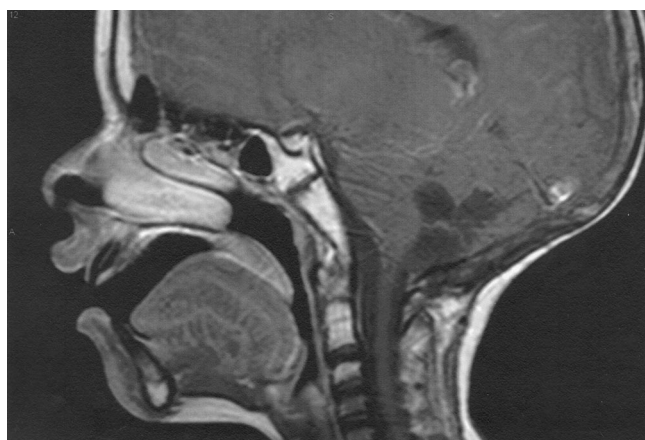

Fig. 4. Median sagittal magnetic resonance scan of the upper airway in a study subject, demonstrating most narrowing at the level of the epiglottis.

served as his or her own control, we did not believe there were important disadvantages to performing the initial scan supine in every subject. We cannot think of an anatomical or physiologic reason why the second scan performed in the study sequence would consistently result in a larger upper airway, as long as the depth of propofol sedation was maintained at a constant level. Another limitation of this study is the lack of external validity to other types of patient populations (*e.g.*, age less than 2 yr, sleep apnea) and different types of sedatives and the depth of sedation. These remain to be seen in future studies. Patients presenting for MR imaging of the head and neck were inherently predisposed to abnormalities in that region, and we were careful during subject selection to exclude patients with possible airway abnormalities or muscle weakness secondary to a brain tumor or neurofibromas. However, subclinical abnormalities cannot be ruled out.

In conclusion, using three-dimensional MR image analysis, we demonstrated that the upper airway of sedated, spontaneously breathing children widens significantly in the lateral position compared with the supine position. This widening occurred at all noncartilaginous areas of the upper airway and was most pronounced in the region at and below the tip of the epiglottis. Our empirical findings confirm the widespread clinical experience that sedated children experience less upper airway obstruction in the lateral position when compared with the supine position.

The authors thank Rosetta Chiavacci, B.S.N. (Department of Anesthesiology and Critical Care, The Children's Hospital of Philadelphia, Philadelphia, Pennsylvania), without whose expert assistance this work would not have been possible, and the magnetic resonance imaging technicians of The Children's Hospital of Philadelphia, whose dedication to the care of children is unparalleled.

References

1. Murat I, Chaussain M, Hamza C, Saint-Maurice J: The respiratory effects of isoflurane, enflurane and halothane in spontaneously breathing children. *Anaesthesia* 1987; 42:711-8
2. Ward DS, Temp JA: Neuropharmacology of the control of ventilation. *Anesthesia, Biologic Foundations*. Edited by Yaksh TL, Lynch C, Zapol WM, Maze M, Biebuyck JF, Saidman LJ. Philadelphia, Lippincott-Raven, 1998, pp 1367-94
3. Cote CJ, Notterman DA, Karl HW, Weinberg C, McCloskey JA: Adverse sedation events in pediatrics: A critical incident analysis of contributing factors. *Pediatrics* 2000; 105:805-14
4. Penzel T, Moller M, Becker HF, Knaack L, Peter JH: Effect of sleep position and sleep stage on the collapsibility of the upper airways in patients with sleep apnea. *Sleep* 2001; 24:90-5
5. Malhotra A, Trinder J, Fogel R, Stanchina M, Patel SR, Schory K, Kleverlaan D, White DP: Postural effects on pharyngeal protective reflex mechanisms. *Sleep* 2004; 27:1105-12
6. Arai YC, Fukunaga K, Hirota S, Fujimoto S: The effects of chin lift and jaw thrust while in the lateral position on stridor score in anesthetized children with adenotonsillar hypertrophy. *Anesth Analg* 2004; 99:1638-41
7. Isono S, Tanaka A, Nishino T: Lateral position decreases collapsibility of the passive pharynx in patients with obstructive sleep apnea. *ANESTHESIOLOGY* 2002; 97:780-5
8. Arens R, McDonough JM, Corbin AM, Hernandez ME, Maislin G, Schwab RJ, Pack AI: Linear dimensions of the upper airway structure during development: Assessment by magnetic resonance imaging. *Am J Respir Crit Care Med* 2002; 165:117-22
9. Udupa JK: Three-dimensional imaging techniques: A current perspective. *Acad Radiol* 1995; 2:335-40
10. Liu J, Udupa JK, Odhnera D, McDonough JM, Arens R: System for upper airway segmentation and measurement with MR imaging and fuzzy connectedness. *Acad Radiol* 2003; 10:13-24
11. Udupa JK, Herman GT: Medical image reconstruction, processing, visualization, and analysis: The MIPG perspective. *Medical Image Processing Group. IEEE Trans Med Imaging* 2002; 21:281-95
12. Arens R, McDonough JM, Costantino AT, Mahboubi S, Tayag-Kier CE, Maislin G, Schwab RJ, Pack AI: Magnetic resonance imaging of the upper airway structure of children with obstructive sleep apnea syndrome. *Am J Respir Crit Care Med* 2001; 164:698-703
13. Litman RS, Weissend EE, Shrier DA, Ward DS: Morphologic changes in the upper airway of children during awakening from propofol administration. *ANESTHESIOLOGY* 2002; 96:607-11
14. Meier S, Geiduschek J, Paganoni R, Fuehrmeyer F, Reber A: The effect of chin lift, jaw thrust, and continuous positive airway pressure on the size of the glottic opening and on stridor score in anesthetized, spontaneously breathing children. *Anesth Analg* 2002; 94:494-9
15. Cauldwell CB: Induction, maintenance, and emergence, *Pediatric Anesthesia*, 3rd edition. Edited by Gregory GA. New York, Churchill Livingstone, 1994, pp 227-59