

Endoscopic Study of Mechanisms of Failure of Endotracheal Tube Advancement into the Trachea during Awake Fiberoptic Orotracheal Intubation

Dana M. Johnson, B.S.,* Aaron M. From, B.S.,† Russell B. Smith, M.D.,‡ Robert P. From, D.O.,§ Mazen A. Maktabi, M.D.||

Background: Advancing the endotracheal tube (ETT) over a flexible bronchoscope (FB) during awake fiberoptic orotracheal intubation is often impeded. The goal of this study was to identify the sites and mechanisms that inhibit the passing of the ETT into the trachea.

Methods: Forty-five consenting patients underwent a clinically indicated awake fiberoptic orotracheal intubation. After topical anesthesia, nerve block, or both, an awake fiberoptic orotracheal intubation was performed. The placement of the FB and advancement of the ETT over the FB were videotaped using a second nasally inserted FB. An otolaryngologist later reviewed the videotaped data.

Results: The right arytenoid or the interarytenoid soft tissues inhibited advancement of the ETT in 42 and 11% of all patients, respectively. In all cases in which the FB was located on the right side of the larynx, failure of ETT advancement almost always occurred at the right arytenoid. Withdrawing the ETT and rotating it 90° counterclockwise resulted in successful intubation on the second, third, and fourth attempts in 26.6, 20, and 0.7% of patients, respectively.

Conclusion: The right arytenoid frequently inhibits advancement of the ETT over the FB into the trachea during awake fiberoptic orotracheal intubation. The FB position in the larynx before tube advancement and the orientation of the ETT are relevant factors in failure of advancement of the ETT into the trachea. The authors recommend positioning the FB in the center of the larynx and orienting the bevel of the ETT to face posteriorly during the first attempt at intubation.

DURING awake fiberoptic orotracheal intubation, advancement of the endotracheal tube (ETT) over the flexible bronchoscope (FB) into the trachea is frequently inhibited.¹ Previous reports have offered a number of suggestions²⁻⁶ as to the likely mechanisms that lead to inhibition of ETT advancement. Accordingly, a variety of recommendations, airway equipment, and ETT types

have been suggested to manage the clinical situation in which an ETT does not advance into the trachea during a fiberoptic intubation.²⁻⁶ Identification of the mechanisms and involved anatomical structures is critical in determining the proper management or modification of airway devices that will facilitate advancement of the ETT into the trachea during fiberoptic intubation. Using *in vivo* endoscopic visualization of the process of fiberoptic intubation, the goal of this study was to identify the sites and mechanisms that inhibit the passing of the ETT into the trachea during awake fiberoptic orotracheal intubation.

Materials and Methods

Patient Selection and Enrollment

The Human Subject Office of The University of Iowa (Iowa City, Iowa) reviewed and approved this research protocol. Forty-eight adult patients gave written informed consent to participate in this study. All of the enrolled patients required a clinically indicated awake fiberoptic orotracheal intubation before induction of general anesthesia. Indications for an awake fiberoptic orotracheal intubation were an anticipated difficult airway or an unstable cervical spine due to trauma or disease. Patients who declined to participate or had the following clinical states were excluded: known abnormal laryngeal structures (e.g., tumors), infectious and toxic conditions of the neck and airway, and traumatic conditions of the neck other than cervical spine fractures or dislocations.

Intubation Technique, Video Recording, and Data Collection

All of the cases (except for three) were neurosurgical cervical spine patients who had ankylosing spondylitis or unstable cervical spine because of disease or fractures. Three patients who underwent other surgical procedures were deemed to have a difficult airway because of morbid obesity. Therefore, our ability to optimally position the head and neck for intubation was limited because of applied traction, an unstable cervical spine, presence of a neck collar, morbid obesity, or positioning of the patient on the bed. All patients were kept awake with conscious sedation during the intubation because of the cervical spine pathology or the difficult airway. They were appropriately sedated with intravenous administration of increments of midazolam and fentanyl. During that process, we followed the guidelines for

This article is featured in "This Month in Anesthesiology." Please see this issue of ANESTHESIOLOGY, page 5A.

* Second-year Medical Student, † Fourth-year Medical Student, ‡ Assistant Professor, Department of Otolaryngology-Head and Neck Surgery, § Associate Professor, Department of Anesthesia, || Associate Professor, Director, Division of Neuroanesthesia, Department of Anesthesia, Roy J. and Lucille A. Carver College of Medicine, The University of Iowa.

Received from the Department of Anesthesia, The University of Iowa, Iowa City, Iowa. Submitted for publication March 31, 2004. Accepted for publication January 12, 2005. Support was provided solely from institutional and/or departmental sources. Dr. Smith has an unrestricted grant from KLS Martin, Jacksonville, Florida, to the Division of Head and Neck Surgery of the Department of Otolaryngology, The University of Iowa, Iowa City, Iowa. Presented at the Annual Meeting of the American Society of Anesthesiologists, Orlando, Florida, October 12-16, 2002. Jerrold Lerman, M.D., served as Handling Editor for this article.

Address reprint requests to Dr. Maktabi: University of Iowa Hospitals and Clinics, Department of Anesthesia, 200 Hawkins Drive, Iowa City, Iowa 52242. Address electronic mail to: mazen-maktabi@uiowa.edu. Individual article reprints may be purchased through the Journal Web site, www.anesthesiology.org.

conscious sedation by the American Society of Anesthesiologists. Briefly, during the procedure, sedation was administered incrementally in a fashion that kept patients comfortable and responsive to verbal commands. They were breathing spontaneously to keep peripheral pulse oximetry readings greater than 98% with or without supplemental oxygen administration.

In all patients, vasoconstriction and topical anesthesia of the nares were performed with cocaine (5%). This was followed by two to three sprays of aerosolized benzocaine (20% solution, 1/2-s spray, 20 mg each spray approximately). Viscous lidocaine (2%) gargle and atomized lidocaine solution (4%) were also used as topical anesthetics to the airway. Before the start of fiberoptic procedures, the efficacy of topical anesthesia was assessed with standard clinical methods: testing for gag reflex with the finger or the tongue depressor and testing for absence of touch sensation, and presence of voice changes. If topical anesthesia was judged inadequate, 2% lidocaine was injected to block the lingual branch of the glossopharyngeal or superior laryngeal nerves or both. In all patients, if there was evidence of coughing during laryngoscopy/tracheoscopy, additional midazolam or propofol was administered, and 3 ml lidocaine (4%) was injected *via* the bronchoscope onto the vocal cords or into the trachea (see Results for more details). The anesthesia residents who performed the fiberoptic intubation stood at the subject's side or head of the bed, depending on the patient's position on the bed or the presence of cervical spine traction devices. A senior anesthesia resident or faculty member held the tongue and helped the patient to maintain a forward jaw thrust to open the posterior aspect of the oropharynx. Finally, the attending anesthesiologist supervised the resident performing the intubation and administration of conscious sedation and ensured the general comfort, welfare, and stability of the vital signs of the patient.

In this study, two FBs were used: one was placed through the patient's mouth for awake fiberoptic orotracheal intubation, and the second was placed through the patient's nose by the principle investigator (M. A. M.) to view the transoral FB placement and passage of the ETT into the trachea. The nasally placed FB (Olympus BF-P240, Melville, NY), which was connected to a monitor and digital camcorder to videotape the intubation, was positioned in the laryngopharynx for a panoramic view of the larynx. Thereafter, anesthesia residents supervised by one of the coinvestigators (R. P. F.) performed the transoral fiberoptic laryngoscopy (Olympus GP-4), tracheoscopy, and intubation. Every effort was made to maintain the FB and ETT in the sagittal plane of the mouth during insertion. The Murphy eye of the ETT was initially oriented toward the right side in all patients. Only standard polyvinyl ETTs (Sheridan HVT; Hudson RCI, Temecula, CA) were used. The ID of the ETT used

was 7.0, 7.5, 8.0, or 8.5 mm, based on clinical criteria for selection of ETT size.

The image taken by the nasally placed FB was continuously recorded, but the television image was not visible to the intubating anesthesiologist during the placement of the FB and the advancement of the ETT. If advancement of the ETT was impeded during the first attempt, it was withdrawn over the FB, rotated 90° counter-clockwise, and readvanced toward the trachea.

The videotapes were later reviewed in random order by an independent faculty otolaryngologist (R. B. S.). This physician had no knowledge of the patient's medical histories and was not involved in their clinical care. He was not present during the intubation and his role was only to examine the videotapes and interpret the findings. Specifically, this otolaryngologist assessed the position of the FB in the larynx and the anatomical structure that inhibited ETT advancement if any was encountered. Other data collected included patient demographics (sex, age, height, and weight) and relevant airway history.

Data Analysis

The Student *t* test was used to compare the distributions of age, height, and weight between patients who has a successful intubation during the first pass and those who did not. Success rates are presented as proportions. Forty-eight patients participated in this study. Although this is a relatively large case series, with 48 subjects, the margin of error in the reported rates is less than 15%. For this to be as small as 5%, one would need 385 patients.

Results

Of the 48 consecutive patients consented to this study, 3 were not included: two could not tolerate the nasal FB placement, and in the third patient, the video equipment malfunctioned and no data were recorded. Of the participating 45 adult patients (17 females, 28 males), the age, height, and weight of all included patients were 52.9 ± 16.8 yr (mean \pm SD), 167.5 ± 10.7 cm, and 82.3 ± 21.4 kg, respectively.

In 21 patients (46.7%), the ETT entered the trachea during the first attempt at insertion. In 24 patients (53.3%), the ETT did not enter the trachea during the first attempt, and multiple attempts were needed. In these cases, the ETT was retracted and turned 90° counterclockwise, and intubation was eventually successful in all of the patients. The ETT entered the trachea on the second, third, and fourth attempts in 12, 9, and 3 patients, respectively. There were no statistically significant differences in age, weight, and height between the group of patients who had no inhibition to ETT passage compared with those who did have inhibition of ETT passage into the trachea (table 1).

Table 1. Demographic Data Comparison for Patients in Whom There Was No Obstruction to ETT Passage (Successful First Pass) Compared with Patients in Whom There Was Initial Obstruction (Failed First Pass)

	Successful First Pass	Failed First Pass	P Value
Number of patients	21	24	
Age, yr	51.7 ± 19.3	54.0 ± 14.6	0.65
Height, cm	166.9 ± 11.3	168.9 ± 10.3	0.69
Weight, kg	81.5 ± 20.9	82.9 ± 22.3	0.82

Age, height, and weight values are presented as mean ± SD. All values are statistically similar between the two groups.

ETT = endotracheal tube.

Five patients received bilateral superior laryngeal nerve blocks. The numbers of attempts that were required to thread the ETT into the trachea in these patients were one, two, two, three, and three times, respectively. Five other patients received blocks of the lingual branch of the glossopharyngeal nerve. In these patients, the numbers of attempts that were required to thread the ETT into the trachea were one, two, two, three, and four times, respectively. One patient received both types of blocks and a transtracheal injection of 4% lidocaine (3 ml). In this patient, the ETT entered the trachea at the first attempt. These patients received topical anesthesia as described in the Materials and Methods section as well.

In 19 patients with ETT failure of advancement (42%), the ETT was inhibited from entering the trachea by the right arytenoid (figs. 1A and B). In five cases (11%), advancement of the ETT was inhibited by the interarytenoid soft tissues. In no case was ETT advancement

inhibited by the vallecula, epiglottis, posterior pharyngeal wall, or true vocal cord.

The initial location of the FB (immediately before ETT advancement) was easily visualized in 75% of the cases. In cases in which the tube rested against the right arytenoid, passage of the ETT was obstructed at the right arytenoid or the interarytenoid soft tissues in 92 and 8% of these cases, respectively (table 2 and fig. 2). In cases in which the FB was centered between the arytenoids before ETT advancement, the ETT passed without inhibition in 60% of these cases. In the other 40% of the cases in which inhibition did occur, it was noted to occur either at the right arytenoid or the interarytenoid soft tissue with equal frequency. In cases in which inhibition occurred, the ETT was retracted and then rotated 90° counterclockwise (toward the patient's left), which directed the ETT bevel posteriorly. This maneuver allowed intubation to proceed without further obstruction in some cases, as stated above, whereas others still required multiple attempts before successful intubation (fig. 3 and table 3).

Discussion

The main finding of this study is that the right arytenoid and the interarytenoid soft tissues were the sites of resistance to advancement of the ETT during awake fiberoptic orotracheal intubation. The second finding was that the standard ETT did not pass into the trachea on the first attempt in 24 of 45 patients (53.3%). This is similar to previously reported values by Hakala *et al.*⁷

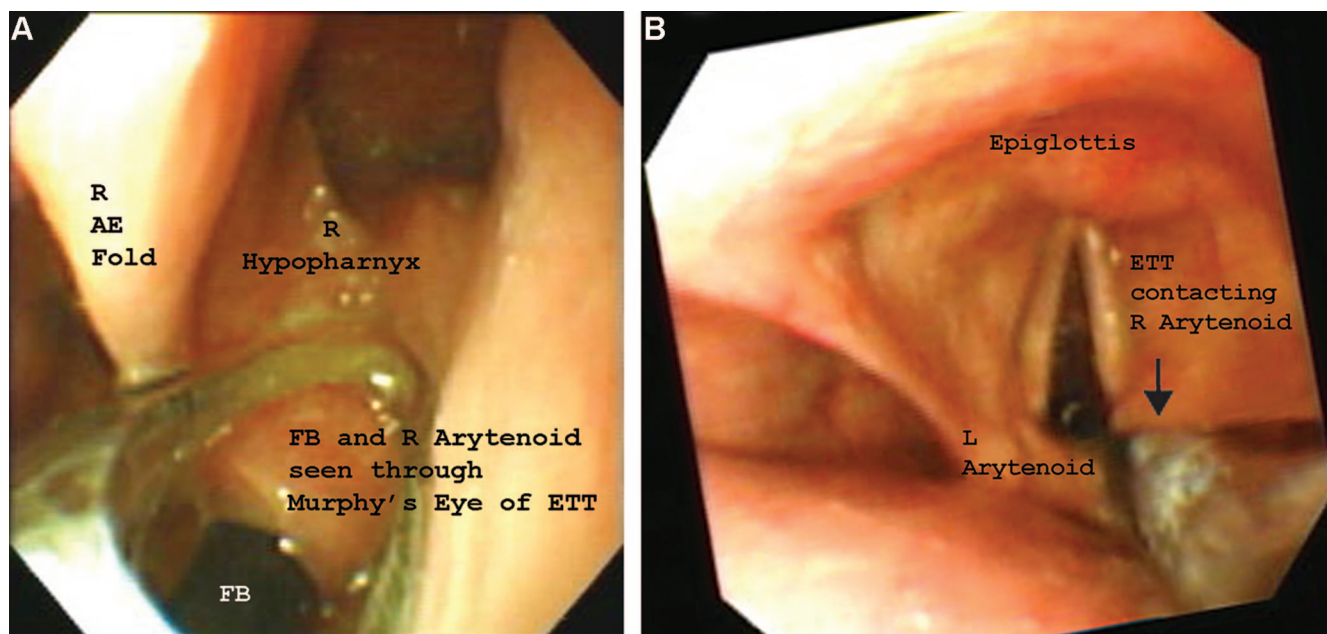


Fig. 1. Still images demonstrating the endotracheal tube (ETT) lodged against the right arytenoid in a right hypopharyngeal view where the right arytenoid is visible through the Murphy eye (A) and a panoramic view (B). AE Fold = aryepiglottic fold; FB = flexible bronchoscope; L = left; R = right.

Table 2. Fiberoptic Bronchoscope Position in the Larynx (Centered, Right Sided, Left Sided, or Cannot Assess) in Relation to ETT Passage (First-Time Pass, Stopped at Interarytenoid, Stopped at Right Arytenoid)

	Centered	Right Sided	Left Sided	Cannot Assess
First-time pass	12 (60%)	0	1 (100%)	8 (73%)
Stopped at interarytenoid	4 (20%)	1 (8%)	0	0
Stopped at right arytenoid	4 (20%)	12 (92%)	0	3 (27%)
All patients	20 (100%)	13	1	11

Number in parentheses represent percent of total patients in that column.

ETT = endotracheal tube.

and Brull *et al.*³: 20 of 30 patients (66.7%) and 12 of 20 patients (65%), respectively, when similar types of polyvinyl ETTs were used. However, anatomical structures that lead to failure of advancement were not identified in these studies.

Previous reports suggested that the tip of the standard ETT was often impinged at the level of the epiglottis or the arytenoid cartilages.^{2,3} The narrow space between the epiglottis and the posterior pharyngeal wall has also been suggested as a factor that leads to the failure of threading the ETT.² Using clinical and radiologic criteria, Randell *et al.*⁴ concluded that the size of the tongue and the length of the epiglottis seem to be important determinants of impingement of the ETT during fiberoptic intubation.⁴ Our study is the first to provide pictorial evidence of the laryngeal structures that obstruct passage of the ETT during fiberoptic intubation, with all cases of obstruction occurring at either the right arytenoid (42%) or the interarytenoid soft tissues (11%).

Inhibited advancement of the ETT during fiberoptic intubation is a factor that may lead to serious laryngeal injury. We recently reported three cases of serious laryn-

geal injury resulting from fiberoptic intubations with standard ETTs.⁸ When comparing types of ETTs, the greatest incidence of resistance to advancement of the ETT during fiberoptic intubations has been reported when the standard beveled ETT is used. This incidence decreases with the use of tubes with a modified tip such as a tapered tip ETT⁹ or the silicone-tipped intubating laryngeal mask airway tube.¹⁰ However, the intubating laryngeal mask airway tube is wire reinforced and therefore may not be suitable for use in patients where post-operative mechanical ventilation is planned. The Parker ETT has also been shown to have a lower failure rate when used for fiberoptic intubations.¹¹

The location of the FB in relation to the arytenoids immediately before intubation seems to be predictive of obstruction during advancement of the ETT. If the FB was located in contact with the right arytenoid (fig. 2), failure of ETT advancement was highly likely. FB positioning in the center between the arytenoids markedly

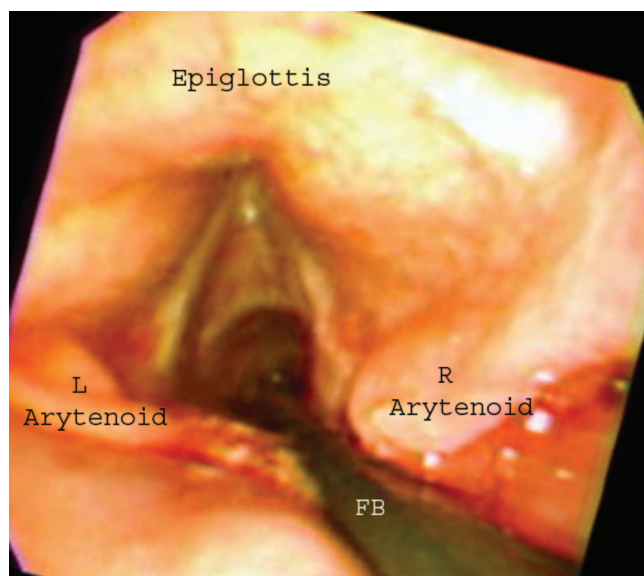


Fig. 2. Still image illustrates the initial flexible bronchoscope (FB) location just before endotracheal tube advancement. In intubations where the endotracheal tube became impeded by the right arytenoid cartilage, the initial location of the FB was very near to the right just before intubation. L = left; R = right.

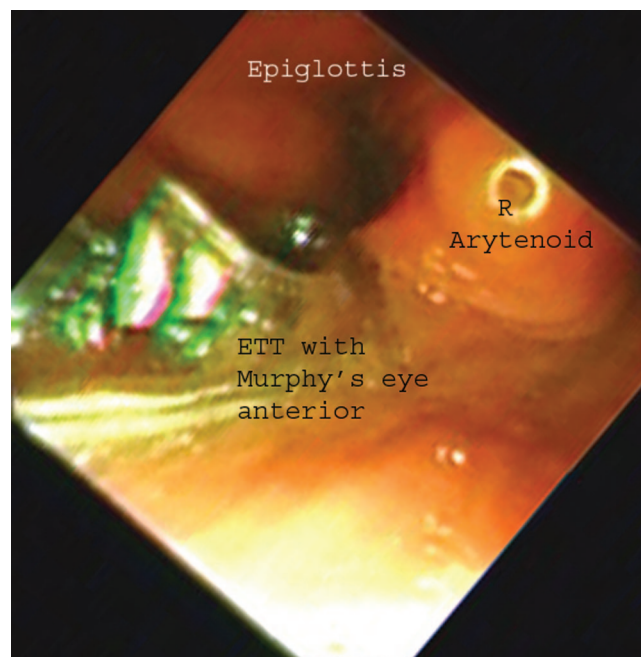


Fig. 3. Still image illustrates that turning the endotracheal tube (ETT) 90° counterclockwise directs the beveled edge of the ETT posteriorly. The tapered tip and Murphy eye face anteriorly toward the epiglottis while the beveled edge passes smoothly by the interarytenoid soft tissue. R = right.

Table 3. Number of ETTs and Their Corresponding IDs in Patients Who Required One versus Multiple Attempts to Advance the ETT into the Trachea

ID of ETT	Entered Trachea at First Attempt	More Than One Attempt to Enter Trachea
7.0	1	2
7.5	10	11
8.0	10	10
8.5	0	1

ETT = endotracheal tube.

improved the frequency that the ETT passed on the first attempt (60%). However, in four cases of the FB being positioned in the center between the arytenoids, the ETT still encountered resistance on the right arytenoid. In four other cases with the FB centered between the arytenoids, obstruction occurred posteriorly at the interarytenoid soft tissue. These findings suggest that although FB location was important, other factors may have also played a role in failure of ETT advancement during awake fiberoptic orotracheal intubation (table 2). For example, movement of the laryngeal structures during spontaneous breathing, swallowing, or spontaneous movement of the head of the patient during intubation may bring the right arytenoid in contact with the FB or with the ETT, resulting in impingement of advancement.

In this study, turning the ETT 90° counterclockwise during the second attempt at advancing the ETT resulted in successful insertion of the ETT into the trachea in 27% of the patients. In 27% of the patients, multiple attempts were still required after tube rotation. With the tube in a standard position (Murphy eye faced to the right of the patient), the tapered tip of the ETT is positioned such that it can easily meet resistance on the prominent edge of the right arytenoid. With 90° of counterclockwise rotation, the bevel of the ETT faces posteriorly, and the tapered tip and Murphy eye of the ETT are placed anteriorly between the FB and the anterior commissure. With the lack of prominent structures anteriorly and the obtuse angle of the bevel directed posteriorly toward the regions associated with tube obstruction, obstruction of the ETT should less likely occur (fig. 3). Turning the ETT 90° counterclockwise may also have moved the FB to the center or anterior part of the larynx, away from the right arytenoid, therefore making inhibition of advancement less likely to occur.

To keep the intubation process similar to that experienced during routine awake fiberoptic orotracheal intubation, there was no communication between the intubating anesthesiologist and the anesthesiologist who was observing and videotaping the intubation. If the nasally

placed FB image had been made available to the intubating anesthesiologist or if the observer had provided any guidance based on his or her view of the ETT in the pharynx, adjustments could have been made that would have altered the intubation and potentially enhanced success.

This study reports the results for 48 consecutive cases. This is comparable to similar reports by Hakala *et al.*⁷ and Brull *et al.*³ The margin of error in our estimates of rates is approximately 15%. To reduce this to 5%, we would have had to have studied 385 cases, which was not practical. However, this relatively large margin of error should not change the clinical implications of our results. Overall, approximately 50% of first attempts at inserting the ETT during a fiberoptic intubation will be unsuccessful. This seems to be much higher if the FB is placed against the right arytenoid cartilage.

In summary, the right arytenoid and the interarytenoid soft tissues are the most common sites of resistance to tube advancement during awake fiberoptic orotracheal intubation. Tube design and orientation are some of the factors contributing to inhibition of ETT advancement over the FB. Finally, FB position in the larynx is a risk factor for inhibition of advancement. Positioning the FB in the center between the arytenoids and rotating the ETT such that the bevel faces posteriorly in the larynx will help to reduce the incidence of failure of advancement and perhaps prevent laryngeal injury.

The authors thank William Clarke, Ph.D. (Professor of Biostatistics, The University of Iowa, College of Public Health, Iowa City, Iowa), for his valuable assistance and advice.

References

1. Ovassapian A: The flexible bronchoscope: A tool for anesthesiologists. *Clin Chest Med* 2001; 22:281-99
2. Ovassapian A, Yelich SJ, Dykes MH, Edward EB: Fiberoptic nasotracheal intubation: Incidence and causes of failure. *Anesth Analg* 1983; 62:692-5
3. Brull SJ, Wiklund R, Ferris C, Connelly NR, Ehrenwerth J, Silverman DG: Facilitation of fiberoptic orotracheal intubation with flexible tracheal tube. *Anesth Analg* 1994; 78:746-8
4. Randell T, Hakala P, Kyttä J, Kinnunen J: The relevance of clinical and radiological measurements in predicting difficulties in fiberoptic orotracheal intubation in adults. *Anaesthesia* 1998; 53:1144-7
5. Hakala P, Randell T: Comparison between two fiberscopes with different diameter insertion cords for fiberoptic intubation. *Anesthesia* 1995; 50:735-7
6. Marsh NJ: Easier fiberoptic intubation (letter). *ANESTHESIOLOGY* 1992; 76:860-1
7. Hakala P, Randell T, Valli H: Comparison between tracheal tubes for orotracheal fiberoptic intubation. *Br J Anaesth* 1999; 81:135-6
8. Maktabi MA, Hoffman H, Funk G, From RP: Laryngeal trauma during awake fiberoptic intubation. *Anesth Analg* 2002; 95:1112-4
9. Jones HE, Pearce AC, Moore P: Fiberoptic intubation: Influence of the tracheal tube design. *Anesthesia* 1993; 48:672-4
10. Greer JR, Smith SP, Strang T: A comparison of tracheal tube tip designs on the passage of an endotracheal tube during oral fiberoptic intubation. *ANESTHESIOLOGY* 2001; 94:729-31
11. Kristensen MS: The Parker Flex-Tip Tube versus a standard tube for fiberoptic orotracheal intubation: A randomized double-blind study. *ANESTHESIOLOGY* 2003; 98:354-8