

Dexmedetomidine as a Total Intravenous Anesthetic Agent

Michael A. E. Ramsay, M.D., F.R.C.A.,* David L. Luterman, M.D.†

DEXMEDETOMIDINE is a highly selective α_2 adrenoceptor agonist that has sedative and analgesic properties with associated reduction in opioid and anesthetic requirements.¹⁻¹¹ One significant advantage of dexmedetomidine is that in the clinical dose range there is no respiratory depression.¹²⁻¹⁴ The agonistic action on the α_2 adrenoceptors in the sympathetic ganglia modulates the release of catecholamines, resulting in a sympatholytic effect and reports of bradycardia and hypotension.¹⁵⁻¹⁹ As the dose of dexmedetomidine is increased, there is a direct action on the blood vessels causing vasoconstriction and a possible increase in blood pressure.^{3,18} This report describes three patients who presented for surgery with potential airway management challenges. Dexmedetomidine was administered to these patients in increasing doses until general anesthesia was attained. The effects of these high doses of dexmedetomidine on respiratory function and hemodynamics are described. The rate of dexmedetomidine infusion was administered based on actual patient body weights.

Case Reports

Case 1

A 66-yr-old, 85-kg woman presented with inspiratory stridor and was found to have a severe subglottic stenosis of her trachea. The stenosis was measured to be 1.5 cm below the vocal cords and to have a lumen diameter of 4 mm. Neodymium:yttrium-aluminum-garnet laser destruction of the tracheal stenosis was scheduled emergently. The patient was brought to the operating room and peripheral intravenous and arterial cannulae were inserted and electrocardiogram electrodes and pulse oximetry sensor were applied. A loading dose of dexmedetomidine 1 $\mu\text{g}/\text{kg}$ was infused over 10 min and then an infusion of 0.7 $\mu\text{g}\cdot\text{kg}^{-1}\cdot\text{h}^{-1}$ was delivered but rapidly increased over 10 min to 10

$\mu\text{g}\cdot\text{kg}^{-1}\cdot\text{h}^{-1}$ to attain an acceptable level of anesthesia that would allow the airway to be instrumented by direct laryngoscopy. Topical lidocaine was applied to the nasal mucosa, the back of the pharynx, and the upper surface of the glottis. A fiberoptic bronchoscope was passed through the nose and the tracheal stenosis was visualized. No supplemental oxygen was supplied. When the patient was completely unresponsive approximately 20 min after induction the laser was powered and the tracheal stenosis was ablated. The procedure took 30 min and during that time the airway had to be supported with a chin lift. The blood pressure declined from 150/80 mm Hg to 110/60 mm Hg and pulse rate was maintained between 70 and 75 beats/min. (figs. 1 and 2) After 20 min the infusion of dexmedetomidine was reduced to 5 $\mu\text{g}\cdot\text{kg}^{-1}\cdot\text{h}^{-1}$, but the patient began to exhibit signs of lightening from anesthesia and so the infusion was increased back to 10 $\mu\text{g}\cdot\text{kg}^{-1}\cdot\text{h}^{-1}$. The oxygen saturations were maintained at greater than 90% except when the upper airway was obstructed and a chin lift was necessary. (fig. 3) Once the chin lift was applied the saturations quickly returned to normal concentrations, and no supplementary oxygen was delivered. An arterial blood gas analysis performed in the middle of the procedure revealed an arterial partial pressure of carbon dioxide (PaCO_2) of 43 mm Hg and a partial pressure of oxygen (PaO_2) of 82 mm Hg.

The patient was taken to the recovery room and became immediately responsive to a loud audible stimulus or light glabellar tap (Ramsay Sedation Score of 4). She remained at this level of sedation for an hour and then reached a Ramsay Sedation Score of 3. When aroused the patient exhibited signs of good cognition, but quickly fell back to sleep when the stimulation ceased. She remained hemodynamically stable and at an Ramsay Sedation Score of 3 for another hour before fully recovering and being ready for discharge from the recovery room after a total time of 2 h.

Case 2

A 65-yr-old, 50-kg man was admitted with acute exacerbation of chronic respiratory failure secondary to emphysema. He required mechanical ventilation for 5 days and was then weaned to spontaneous ventilation and the endotracheal tube was removed. While breathing room air, his arterial PaO_2 was 55 mm Hg and PaCO_2 was 60 mm Hg. He was then scheduled to have extensive resections of facial skin cancers with full-thickness skin graft reconstruction. The patient arrived in the operating room tachycardic and hypertensive and vigorously refused local anesthesia. Sedation with dexmedetomidine was attempted with a loading dose of 1 $\mu\text{g}/\text{kg}$ followed by an infusion of 0.7 $\mu\text{g}\cdot\text{kg}^{-1}\cdot\text{h}^{-1}$. This did not provide adequate anesthesia so the infusion was increased to 5 $\mu\text{g}\cdot\text{kg}^{-1}\cdot\text{h}^{-1}$, and after a further 10 min the patient was anesthetized deeply enough to allow the surgery to take place. No supplemental oxygen was administered because of the close proximity of the electrical cautery.

Hemodynamically he became stable with heart rate slowing from 120 beats/minute to 65 beats/minute and blood pressure declining from 220/120 mm Hg to 120/65 mm Hg. Oxygen saturation, measured by a pulse oximeter, was maintained above 90% and respiratory rate declined from 30 breaths/min to 16 breaths/min. At the conclusion of the procedure local anesthesia was infiltrated into the surgical sites. The patient required no analgesia in the postanesthesia recovery unit and remained hemodynamically stable. He was discharged from the unit 2 h postoperatively.

This article is accompanied by an Editorial View. Please see: Ebert T, Maze M: Dexmedetomidine: Another arrow for the clinician's quiver. ANESTHESIOLOGY 2004; 101:568-70.

* Chairman, Department of Anesthesiology & Pain Management and † Attending Staff, Department of Pulmonary Medicine, Baylor University Medical Center, Dallas, Texas.

Received from the Department of Anesthesiology and Pain Management, Baylor University Medical Center, Dallas, Texas. Submitted for publication January 2, 2004. Accepted for publication April 12, 2004. Support was provided solely from institutional and/or departmental sources. Dr. Ramsay receives honoraria for lectures and is the recipient of a research grant from Abbott Laboratories, Chicago, Illinois.

Address reprint requests to Dr. Ramsay: Chief of Service, Department of Anesthesiology & Pain Management, Baylor University Medical Center, 3500 Gaston Avenue, Dallas, TX 75246. Address electronic mail to: docram@baylorhealth.edu. Individual article reprints may be purchased through the Journal Web site, www.anesthesiology.org.

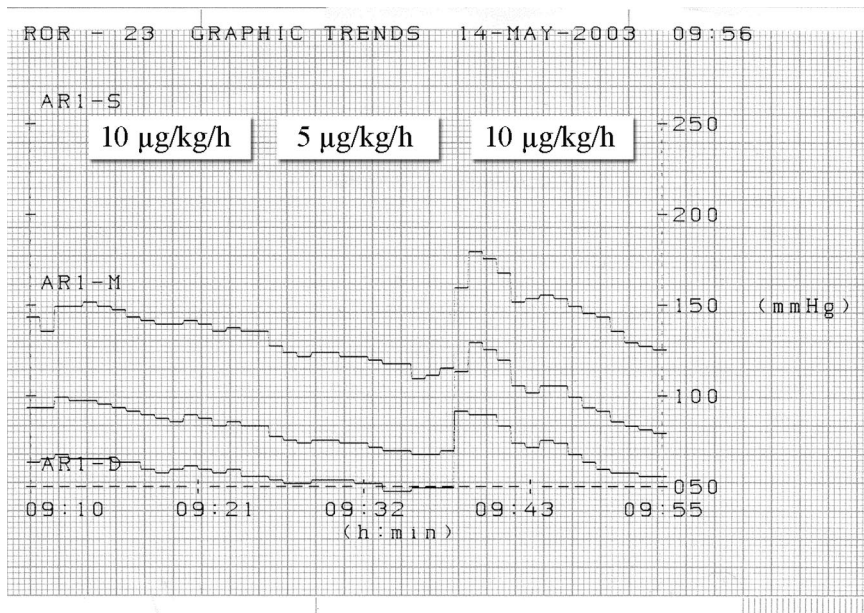


Fig. 1. Blood pressure changes during anesthesia in patient in Case 1.

Case 3

A 50-yr-old, 80-kg man presented for an evaluation of an upper airway obstruction. He had an artificial upper trachea in the form of a silastic Montgomery tracheal stent. This was placed 10 yr ago, after he had sustained multiple traumas that included a severe tracheal injury. The stent had been replaced approximately every year since then, and the tracheal stoma débrided at the same time. He required treatment for chronic pain and was receiving long-term opioid therapy. Previous anesthetics had been complicated by difficulties with airway management, as the upper airway was severely distorted by scar tissue. Postoperative pain management also was challenging because of his chronic opioid use.

The patient was brought to the operating room, routine monitors were applied, and peripheral venous and arterial cannulae were in-

serted. Dexmedetomidine was administered with a loading dose of 1 $\mu\text{g}/\text{kg}$ followed by an infusion of 0.7 $\mu\text{g}\cdot\text{kg}^{-1}\cdot\text{h}^{-1}$. The infusion was increased over 5 min to 5 $\mu\text{g}\cdot\text{kg}^{-1}\cdot\text{h}^{-1}$ and maintained at this rate for a further 5 min before the patient would tolerate the surgery. The patient then underwent rigid and fiberoptic bronchoscopy together with a laryngoscopy. The tracheal prosthesis was removed and the trachea was débrided. The patient breathed room air spontaneously throughout this part of the procedure and oxygen saturations were maintained above 92%. A new tracheal stent was inserted without difficulty. The patient then underwent bronchopulmonary lavage with saline to irrigate profuse purulent material present in the bronchi. Supplemental oxygen was required during this part of the procedure. The patient recovered comfortably, without requiring any opioid therapy and with hemodynamic stability. He was discharged home 3 h later from the recovery room.

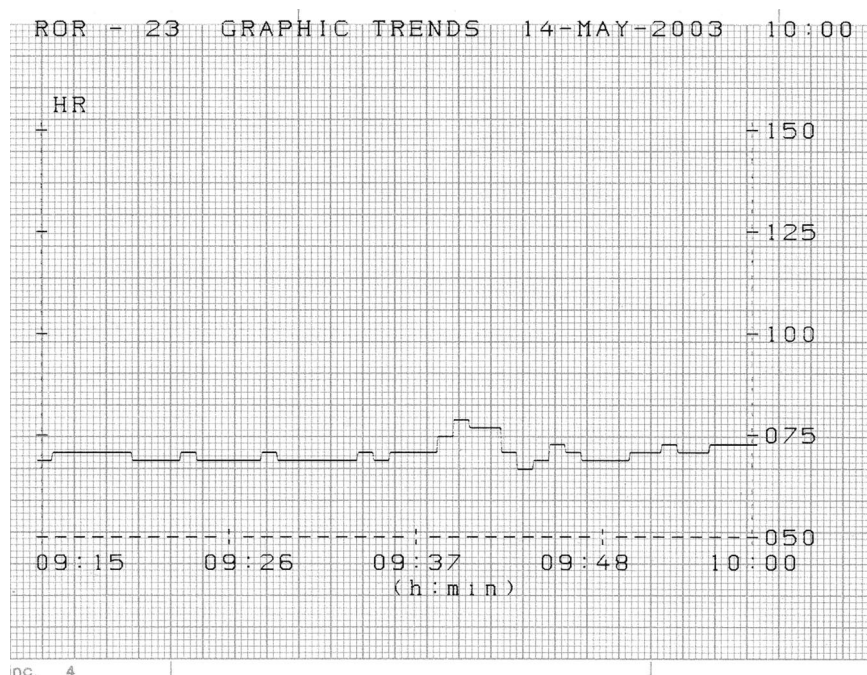


Fig. 2. Pulse rate changes during anesthesia in patient in Case 1.

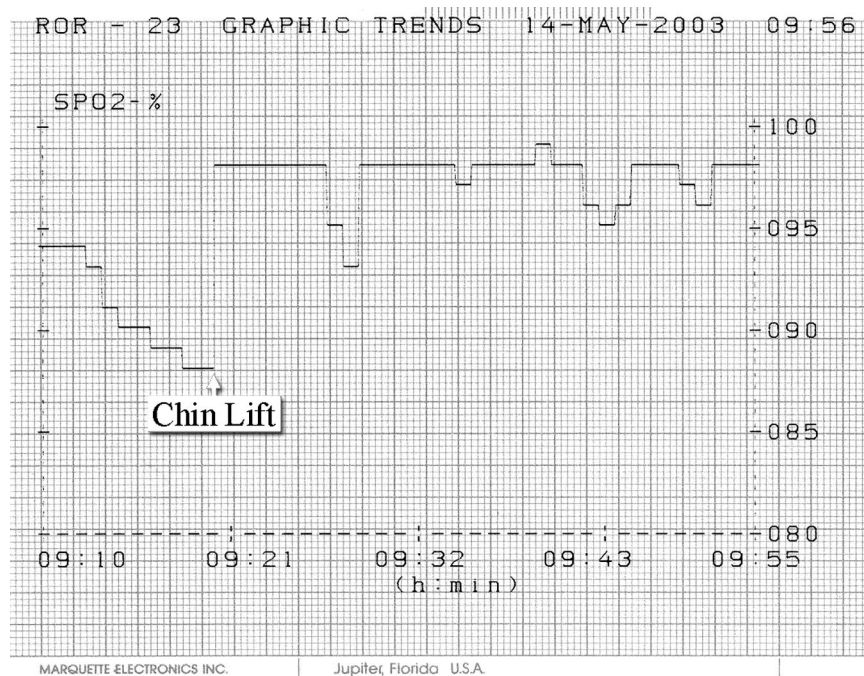


Fig. 3. Oxygen saturation changes during anesthesia in patient in Case 1.

Discussion

These case reports demonstrate that dexmedetomidine may be used as a total intravenous anesthetic agent in certain patients if doses are increased to a high enough level. Previous studies on assessing dexmedetomidine as a general anesthetic found that supplementary agents were necessary, but the doses of dexmedetomidine had not reached the high levels of administration reported here.²⁰ In the first case reported here, the dexmedetomidine was supplemented with topical anesthesia before surgical intervention. In the second patient, postoperative analgesia was supplemented with infiltration of local anesthesia. The attributes of dexmedetomidine of sedation, analgesia, and no respiratory depression demonstrated at lower doses appear to be sustained at anesthetic doses. However, control of the airway was lost in the first patient, requiring manual support in the form of a chin lift, although respiratory drive was maintained. The level of sedation at which airway control is lost has not been well studied; this may occur at lower doses of dexmedetomidine. The advantage in these patients was that the airway was maintained easily together with adequate respiratory drive such that supplemental oxygen was not required. There was no demonstrable respiratory depression as measured by pulse oximetry in the patients breathing room air; however, airway support was required in the first patient. The lack of respiratory depression was confirmed in patient 1 by an arterial blood gas analysis that recorded a normal P_{aCO_2} in the middle of the procedure. The blunting of the sympathetic nervous system in these patients produced satisfactory hemodynamics. No patient experienced hypotension or severe bradycardia, as

has been reported.¹⁹ This may have been that all three patients were extremely anxious initially and exhibited tachycardia and hypertension before induction of anesthesia. There was also no evidence of vasoconstriction and hypertension as the dose of dexmedetomidine was increased to high levels, as has also been reported.³ The dexmedetomidine infusion was increased rapidly over 5 to 10 min to gain faster control of the patients. The plan was to titrate the dose back down once good anesthesia had been obtained. However, it was not possible to achieve this in any of the patients, and patient 1 had to have the infusion increased back up to $10 \mu\text{g}\cdot\text{kg}^{-1}\cdot\text{h}^{-1}$ to allow the procedure to be completed.

The preservation of respiratory drive offers the opportunity that this anesthetic technique may present another method for providing anesthesia for the patient with a difficult airway. This needs to be studied more thoroughly, as the data available on dexmedetomidine mainly relates to its use as an anesthetic and opioid-sparing agent at much lower doses and when used in combination with other anesthetic, sedative, and analgesic agents. At these high doses there were no airway concerns other than one patient requiring a chin-lift, and no opioids were required even in the patient who was a chronic opioid user. The recovery period required for these patients was not significantly prolonged when compared to many conventional anesthetic techniques; it was between 2 and 3 h. All three patients were hemodynamically stable in the recovery unit. The cost of this technique is also potentially higher than that of conventional anesthetics, but the advantage of no loss of respiratory drive and good analgesia without the need for opioids may well justify this expense.

References

1. Kamibayashi T, Maze M: Clinical uses of α_2 -adrenergic agonists. *ANESTHESIOLOGY* 2000; 93:1345-9
2. Hall JE, Uhrich TD, Barney JA, Arain SR, Ebert TJ: Sedative, amnestic, and analgesic properties of small-dose dexmedetomidine infusions. *Anesth Analg* 2000; 90:699-705
3. Ebert TJ, Hall JE, Barney JA, Uhrich TD, Colincio MD: The effects of increasing plasma concentrations of dexmedetomidine in humans. *ANESTHESIOLOGY* 2000; 93:382-94
4. Jaakola ML, Salonen M, Lehtinen R, Scheinin H: The analgesic action of dexmedetomidine—a novel alpha 2-adrenoceptor agonist—in healthy volunteers. *Pain* 1991; 46:281-5
5. Weinbroum A, Ben-Abraham R: Dextromethorphan and dexmedetomidine: New agents for the control of perioperative pain. *Eur J Surg* 2001; 167:563-9
6. Jalonen J, Hynynen M, Kuitunen A, Heikkilä H, Perttilä J, Salmenperä M, Valtonen M, Aantaa R, Kallio A: Dexmedetomidine as an anesthetic adjunct in coronary artery bypass grafting. *ANESTHESIOLOGY* 1997; 86:331-45
7. Khan ZP, Ferguson CN, Jones RM: Alpha-2 and imidazoline receptor agonists: Their pharmacology and therapeutic role. *Anesthesia* 1999; 54:146-65
8. Bhana N, Goa KL, McKlellan KJ: Dexmedetomidine. *Drugs* 2000; 59:263-8
9. Khan ZP, Munday IP, Jones RM, Thornton C, Mant TG, Amin D: Effects of dexmedetomidine on isoflurane requirements in healthy volunteers. I. Pharmacodynamic and pharmacokinetic interactions. *Br J Anaesth* 1999; 83:372-80
10. Venn RM, Newman P, Grounds RM: A phase II study to evaluate the efficacy of dexmedetomidine for sedation in the medical intensive care unit. *Intensive Care Med* 2003; 29:201-7
11. Venn RM, Bradshaw CJ, Spencer R, Brealey D, Caudwell E, Naughton C, Vedio A, Singer M, Feneck R, Treacher D, Willats SM, Grounds RM: Preliminary UK experience of dexmedetomidine, a novel agent for postoperative sedation, in the intensive care unit. *Anaesthesia* 1999; 54:1136-42
12. Venn RM, Hell J, Grounds RM: Respiratory effects of dexmedetomidine in the surgical patient requiring intensive care. *Crit Care* 2000; 4:302-308
13. Venn RM, Karol M, Grounds RM: Pharmacokinetics of dexmedetomidine infusions for sedation of postoperative patients requiring intensive care. *Br J Anaesth* 2002; 88:669-75
14. Martin E, Ramsay G, Mantz J, Sum-Ping S: The role of the α_2 -adrenoceptor agonist dexmedetomidine in postsurgical sedation in the intensive care unit. *J Intensive Care Med* 2003; 18:29-41
15. Kersten J, Pagel P, Hettrick D, Warltier D: Dexmedetomidine partially attenuates the sympathetically mediated systemic and coronary hemodynamic effects of cocaine. *Anesth Analg* 1995; 80:114-57
16. Scheinin B, Lindgren L, Randell T, Scheinin H, Scheinin M: Dexmedetomidine attenuates sympathoadrenal responses to tracheal intubation and reduces the need for thiopentone and perioperative fentanyl. *Br J Anaesth* 1992; 68:126-31
17. Talke P, Richardson C, Scheinin M, Fisher D: Postoperative pharmacokinetics and sympatholytic effects of dexmedetomidine. *Anesth Analg* 1997; 85:1136-42
18. Talke P, Lobo E, Brown B: Systemically administered α_2 -agonist-induced peripheral vasoconstriction in humans. *ANESTHESIOLOGY* 2003; 99:65-70
19. Ingersoll-Weng E, Manecke GR, Thistlethwaite PA: Dexmedetomidine and cardiac arrest. *ANESTHESIOLOGY* 2004; 100:738-9
20. Aho M, Erkola O, Kallio A, Scheinin H, Kortilla K: Dexmedetomidine infusion for maintenance of anesthesia in patients undergoing abdominal hysterectomy. *Anesth Analg* 1992; 75:940-6

Anesthesiology 2004; 101:790-92

© 2004 American Society of Anesthesiologists, Inc. Lippincott Williams & Wilkins, Inc.

Reactivation of Phantom Limb Pain Immediately after Cervical Spinal Decompression

Ryoji Iida, M.D., Ph.D.,* Kazuhiko Munakata, M.D.,* Takahiro Suzuki, M.D., Ph.D.,† Shigeru Saeki, M.D., Ph.D.,‡ Setsuro Ogawa, M.D., Ph.D.§

IT is well known that phantom limb pain can reappear or be exacerbated transiently during spinal anesthesia in amputees.¹ However, to the best of our knowledge, the reappearance of phantom limb pain immediately after nonamputation surgery in an amputee has not been reported. We herein present a patient with chief complaint of reactivation of phantom limb pain the day immediately after cervical myelopathy surgery.

Case Report

A 65-yr-old man was scheduled to undergo surgery for cervical myelopathy resulting from spondylotic canal stenosis. Past medical history revealed four previous surgeries under general anesthesia, one of which required amputation as a result of a railway accident at the age of 49 yr. The injuries sustained from his fall from the railway platform required amputation below the left shoulder, below the right knee and at the midmetacarpal bones of the right first, second, and

third fingers. Approximately 1 month after the amputation he began to suffer from severe and painful phantom limb sensations localized to the right below-knee and the left below-shoulder regions. The sensations were described as cramped pain and were greater in the right below-knee region than in the left below-shoulder region. The patient had complained of intractable cramp pain for approximately 6 months, but the treatments administered during this period are not known. As a result of gradual decrease of phantom limb pain, the sensation changed from pain to numbness. The painless phantom limb sensation from the left below-shoulder and the right below-knee regions described as numbness gradually decreased in intensity and area of involvement during the past 15 yr but still persisted up to the present time. The patient had also complained of telescoping phenomenon of his left hand (a gradual transposition towards the stump) and that the location of his left hand gradually moved superiorly from his left waist region towards the thoracic region, whereas he did not experience telescoping of his right lower limb.

The patient was hospitalized in our hospital to undergo surgery for cervical degenerative myelopathy because of spondylotic canal stenosis with calcification of the posterior longitudinal ligament that was not directly attributed to the railway accident. The preoperative symptom was neck and back pain untreatable with medications accompanied by nausea and chest discomfort. Preoperative magnetic resonance imaging revealed flattening of the cervical spinal cord at the level of C5-6 and C6-7, where the herniated disc extruded towards the left anterior side of the cord. The operation was performed with a left anterior approach by subtotal corpectomy of C5/C6 and discectomy of C4/C5/C6/C7 with iliac strut graft fusion. The symptoms of cervical myelopathy improved postoperatively. Postoperative magnetic resonance imaging revealed improvement of the cord flattening.

The morning immediately after surgery the patient was aware of the presence of pain in his left upper arm, which gradually extended to the left elbow, wrist, and fingers during the day. He felt as if his left hand

* Staff Anesthesiologist, † Assistant Professor, ‡ Associate Professor, § Professor and Chair, Department of Anesthesiology, Surugadai Nihon University Hospital, Tokyo, Japan.

Received from the Department of Anesthesiology, Surugadai Nihon University Hospital, Tokyo, Japan. Submitted for publication December 27, 2003. Accepted for publication March 15, 2004. Support was provided solely from institutional and/or departmental sources.

Address reprint requests to Dr. Iida: Department of Anesthesiology, Surugadai Nihon University Hospital, 1-8-13 Kanda-Surugadai, Chiyoda-Ku, Tokyo 101-8309, Japan. Address electronic mail to: ryoiida@beach.ocn.ne.jp. Individual article reprints may be purchased through the Journal Web site, www.anesthesiology.org.

had moved away from his left thoracic region inferiorly towards his left waist region. Pain intensity gradually increased during the day, and by night the patient recognized it to be the same as the phantom limb pain that he had previously experienced. The reactivated pain was of the same quality and in the same location. It was an intractable, continuous, spontaneous cramp pain localized to the whole region of the left below-shoulder and was exacerbated with mobilization of the shoulder or application of pressure to the stump. The pain resulted in daily sleep disturbance while the pain intensity fluctuated. His initial treatment for the pain was with oral lornoxicam, a nonsteroidal antiinflammatory drug that brought no pain relief. He was first consulted by our pain clinic staff at day 6 after surgery. Sensory examination of the well-healed scar of the stump revealed the presence of hypoesthesia and hypoaesthesia. No palpable neuromas could be detected in the stump. He was treated with oral amitriptyline (20 mg per day) and dextromethorphan (45 mg per day) by our pain clinic staff. The phantom limb pain gradually subsided with this combination of drugs and completely subsided by the 15th day after surgery. At the same time the patient felt that his left hand had gradually returned from the thoracic region to the original location, the left waist region, as before surgery. The nonpainful phantom limb sensation of the left below-shoulder and the right below-knee regions persisted as numbness, described in text. The drugs were discontinued by the patient's own judgment 1 month after the operation. Follow-up evaluation revealed that the patient has been free of phantom limb pain for 6 consecutive months without any analgesics.

Discussion

The phantom limb pain that had once been completely relieved and remained asymptomatic for approximately 15 yr was reactivated after surgery for cervical myelopathy. The mechanisms involved in the reactivation are postulated to be associated with surgery. The surgical site of the cervical spine in this patient was close to the left dorsal horn neurons of the cervical spinal cord where the primary afferent nerves of the left upper limbs terminate in and where the secondary afferent nerves originate. Phantom limb pain of this patient was reactivated and limited only to the left upper limb. It is probable that mechanical stimuli or inflammatory responses resulting from the surgical stress to the cervical spine resulted in functional changes in the afferent pathway of the left upper limb. Several animal studies have revealed that injury-producing tissue damage increases excitability of the central nervous system^{2,3} and reduces inhibitory pain modulation.⁴ Moreover, it was demonstrated that electrical stimulation to the region of the thalamus in amputees that originally represented the missing limb could evoke phantom sensations including pain, in which it was indicated that the thalamic representation of the amputated limb remains functional in amputees with phantoms.⁵ Therefore, it is a possible explanation that functional changes in the central nervous system caused by surgical noxious stimuli to the cervical spine resulted in the reactivation of the phantom limb pain.

Electrophysiological improvement in the decompressed cervical spinal cord might have contributed to the reappearance of pain. Several studies revealed that evoked potentials in the spinal cord suppressed by cer-

vical cord compression recovered promptly after surgical decompression.⁶⁻⁸ Although we did not investigate this patient electrophysiologically, we could hypothesize the normalization of neural activities by marked improvement of the symptoms and findings in the postoperative magnetic resonance imaging. A similar case was described by Brihaye in 1958, in which painless phantom phenomenon from a right lower limb extinguished itself progressively, paralleling the aggravation of cervical radiculopathy because of a herniated disc and reappeared upon slow recovery from radiculopathy 6 months after excision of the herniated disc.⁹ For our patient, the electrophysiological improvement after cervical decompression probably influenced the neural activities of the central nervous system that might have contributed to the reappearance of phantom limb pain.

The phantom limb pain was relieved with oral amitriptyline and dextromethorphan. Both amitriptyline and dextromethorphan have antagonistic potencies for *N*-methyl-D-aspartate receptors in the central nervous system.¹⁰⁻¹² Oral dextromethorphan was reported to effectively attenuate postamputation phantom limb pain, in which it was discussed that dextromethorphan interrupted sensitization in the central nervous system by antagonizing *N*-methyl-D-aspartate receptors.¹² This is included as a possible explanation for our patient: that central sensitization induced by surgical stimuli was interrupted by the combined administration of these two drugs and remained suppressed even after discontinuation of these drugs.

In summary, the phantom limb pain that had once been completely relieved and remained asymptomatic for approximately 15 yr was reactivated after cervical spinal decompression. This case suggests that phantom limb pain suppressed for some length of time can be reactivated by surgery that involves aggravating stimulation involving the pain pathway. The possibility of reactivation of phantom limb pain may be taken into consideration when the balance of advantages and disadvantages of surgery is evaluated.

References

1. Sellick BC: Phantom limb pain and spinal anesthesia. *ANESTHESIOLOGY* 1985; 62:801-2
2. Woolf CJ: Evidence for a central component of post-injury pain hypersensitivity. *Nature* 1983; 306:686-8
3. Simone DA, Sorkin LS, Oh U, Chung JM, Owens C, LaMotte RH, Willis WD: Neurogenic hyperalgesia: Central neural correlates in responses of spinothalamic tract neurons. *J Neurophysiol* 1991; 66:228-46
4. Traub RJ: Spinal modulation of the induction of central sensitization. *Brain Res* 1997; 778:34-42
5. Davis KD, Kiss ZHT, Luo L, Tasker RR, Lozano AM, Dostrovsky JO: Phantom sensations generated by thalamic microstimulation. *Nature* 1998; 391:385-7
6. Kanchiku T, Taguchi T, Kaneko K, Fuchigami Y, Yonemura H, Kawai S: A correlation between MRI and electrophysiological findings in cervical spondylotic myelopathy. *Spine* 2001; 26:E294-9
7. Deecke L, Tator CH: Neurophysiological assessment of afferent and efferent conduction in the injured spinal cord of monkeys. *J Neurosurg* 1973; 39:65-74
8. Kojima Y, Yamamoto T, Ogino H, Okada K, Ono K: Evoked spinal potentials as a monitor of spinal cord viability. *Spine* 1979; 4:471-7

9. Brihaye J: Extinction of phantom limb in the amputated leg during medullary compression by cervical disc hernia: revival of phantom limb after surgical removal of hernia. *Acta Neurologica et Psychiatrica Belgica* 1958; 58:536-9

10. Watanabe Y, Saito H, Abe K: Tricyclic antidepressants block NMDA receptor-mediated synaptic responses and induction of long-term potentiation in rat hippocampal slices. *Neuropharmacology* 1993; 32:479-86

11. Eisenach JC, Gebhart GF: Intrathecal amitriptyline acts as an *N*-methyl-D-aspartate receptor antagonist in the presence of inflammatory hyperalgesia in rats. *ANESTHESIOLOGY* 1995; 83:1046-54

12. Abraham RB, Marouani N, Kollender Y, Meller I, Weinbroum AA: Dextromethorphan for phantom pain attenuation in cancer amputees: A double-blind crossover trial involving three patients. *Clin J Pain* 2002; 18:282-5

Anesthesiology 2004; 101:792-4

© 2004 American Society of Anesthesiologists, Inc. Lippincott Williams & Wilkins, Inc.

Perioperative Hemorrhage and Combined Clopidogrel and Aspirin Therapy

Michael Moore, M.B., F.R.C.A.R.S.I.,* Michael Power, M.B., F.F.A.R.C.S.I., F.A.C.P.†

CLOPIDOGREL has been introduced as another antiplatelet drug in combination with aspirin to decrease thrombotic events in patients with cerebrovascular and coronary artery disease. Patients are presenting for surgery taking a combination of both aspirin and clopidogrel. We report two cases of surgery and anesthesia complicated by bleeding associated with the combination of aspirin and clopidogrel.

Case Reports

Case 1

An 83-yr-old woman with known atherosclerotic cerebrovascular disease presented with a transient ischemic attack. Her medications included aspirin 300 mg once daily and bendrofluzide, lisinopril, and pravastatin for concomitant hypertension and ischemic heart disease.

Twenty-four hours after admission the patient, while receiving intravenous heparin, had another transient ischemic attack. Computerized tomography brain scan revealed a small new area of infarction near her right internal capsule. For this reason clopidogrel 75 mg daily was added and heparin was stopped. Magnetic resonance imaging of the brain revealed right parietal/temporal/frontal deep matter changes consistent with watershed infarction. Over the next 2 days she had fluctuating neurologic signs with periods of recovery. A carotid duplex scan showed a 70-80% stenosis of her right internal carotid artery. She was therefore scheduled for a right carotid endarterectomy. Preoperative platelet count was $258 \times 10^9/L$ ($150-400 \times 10^9/L$), activated partial thromboplastin time 36 s (normal range 23-35 s), and prothrombin time 14 s (normal range 10-14 s). Bleeding time was not performed.

Intraoperatively received 5,000 units of intravenous heparin before shunt insertion. The neck incision was noted to be "oozy," and a drain was inserted before wound closure. A coagulation screen revealed an activated partial thromboplastin time of >300 s that was corrected to normal with protamine. Anesthesia was discontinued and the endotracheal tube was removed uneventfully and the patient was transferred to the recovery room.

Over the next 2 h the patient had persistent bleeding from her neck wound despite a normal activated partial thromboplastin time. A he-

matoma developed that required evacuation under general anesthesia. She then returned to the recovery area, where she developed stridor with cyanosis. She was again transferred to the operating theater and underwent emergency intubation after inhalation induction. She was subsequently transferred to the intensive care unit. Wound hemostasis remained satisfactory.

The patient received ventilatory support for 3 days as a result of glottic edema. She also received 2 units of erythrocyte concentrate. On the third day, the endotracheal tube was removed uneventfully with minimal residual stridor. She made a successful recovery and was transferred to the ward for further management

Case 2

A 74-yr-old woman presented to the outpatient clinic with a history of hoarseness for 2-3 yr and dyspnea on exertion. Examination revealed a large multinodular goiter with tracheal compression. The patient was scheduled for subtotal thyroidectomy.

She had a background history of coronary artery disease with a myocardial infarction, coronary angioplasty, and stenting and subsequent therapy with clopidogrel 75 mg daily. The patient was advised to discontinue clopidogrel and aspirin for 1 week before surgery. The date of surgery was changed twice. Ultimately, on the day of surgery the patient remained on clopidogrel 75 mg once daily, aspirin 75 mg once daily, atorvastatin, isosorbide mononitrate, and sotalol hydrochloride.

Preoperative platelet count was $225 \times 10^9/L$ ($150-400 \times 10^9/L$), activated partial thromboplastin time 30 s (normal range 23-35 s), prothrombin time 12 s (normal range 10-14 s). Bleeding time was not performed.

Anesthesia and surgery were uneventful. The endotracheal tube was removed uneventfully and the patient was transferred to the recovery area.

In the recovery room, bleeding was noted from her wound, and approximately 45 mins after surgery she developed respiratory distress. As clips were being removed she developed cyanosis and asystole. After successful placement of the endotracheal tube with cardiopulmonary resuscitation and intravenous adrenaline, circulation was returned. In the operating theater, on clip removal, fresh blood and clots were removed from the neck wound. Several bleeding sites received diathermy. No bleeding vessel was seen. After hemostasis was secured two drains were inserted and the wound was closed. The patient was transferred to intensive care.

She required two units of packed cells because of her blood loss. On the third day the endotracheal tube was successfully removed. Four days later the drains and clips were removed.

Discussion

Clopidogrel hydrogen sulfate is a platelet aggregation inhibitor that was introduced as a secondary prevention

* Specialist Registrar, † Consultant Anesthetist and Intensivist, Department of Anesthesia and Intensive Care, Beaumont Hospital, Dublin, Ireland.

Received from the Department of Anesthesia and Intensive Care, Beaumont Hospital, Dublin, Ireland. Submitted for publication November 26, 2003. Accepted for publication March 17, 2004. Support was provided solely from institutional and/or departmental sources.

Address reprint requests to Dr. Moore: Specialist Registrar, Department of Anesthesia and Intensive Care, Beaumont Hospital, Dublin 9, Ireland. Address electronic mail to: michaelmoore@eircom.net. Individual article reprints may be purchased through the Journal Web site, www.anesthesiology.org.

therapy in patients at high risk of thrombotic events as a result of recent myocardial infarction or stroke or established vascular disease. A single daily dose of 75 mg is effective.¹

Platelets are activated by adenosine diphosphate. Clopidogrel selectively and irreversibly inhibits adenosine diphosphate induced binding of fibrinogen to platelets by causing a major reduction in the adenosine diphosphate induced activation of the membrane glycoprotein IIb/IIIa complex. It also inhibits platelet aggregation in response to collagen, thrombin, and shear stress and has a synergistic effect when combined with aspirin.² Clopidogrel thus prolongs bleeding time, inhibits platelet aggregation, and delays clot retraction. Bleeding time is significantly prolonged with both agents and reaches a maximum of 1.5-fold to twofold of baseline after 3 to 7 days.³ Platelets are inhibited for their lifespan.

In a recent study Serebruanu *et al.* examined the antiplatelet properties of clopidogrel and aspirin *versus* aspirin alone in patients with congestive heart failure with heightened platelet activity. Platelet studies were performed at baseline and after 30 days of therapy. After 30 days of monotherapy with aspirin 325 mg there were no changes in platelet characteristics as compared to baseline. However, the addition of clopidogrel 75 mg resulted in significant inhibition of platelet activity.⁴

The Clopidogrel Versus Aspirin in Patients at Risk of Ischemic Events trial found that long-term administration of clopidogrel 75 mg alone in patients with atherosclerotic vascular disease was more effective than aspirin alone in reducing the combined risk of ischemic stroke, myocardial infarction, or vascular death. The overall safety profile of clopidogrel appears to be as least as good as that of medium-dose aspirin with an added benefit of fewer gastrointestinal side effects than aspirin.⁵

The Clopidogrel in Unstable Angina to Prevent Recurrent Events Trial Investigators trial demonstrated an impressive benefit from combined clopidogrel and aspirin in reduction of mortality and Q wave myocardial infarction. However, discontinuation of clopidogrel and aspirin for less than 5 days resulted in an increased tendency of perioperative bleeding in patients undergoing coronary artery bypass graft compared with patients receiving aspirin alone.⁶

In reply to correspondence concerning the Clopidogrel in Unstable Angina to Prevent Recurrent Events trial, the authors state that for elective surgery, combined clopidogrel and aspirin therapy "may be stopped a few days before surgery to minimize the risks of bleeding."⁷

The increased morbidity associated with combined aspirin and clopidogrel therapy has also been reported in a recent study by Yende *et al.*⁸ They demonstrated that the combination of clopidogrel and aspirin before coronary artery bypass graft is associated with increased

frequency of reexploration for bleeding and an increased need for erythrocyte transfusion. The authors recommend platelet transfusion for bleeding in patients who have received clopidogrel before coronary artery bypass graft and that the discontinuation of these agents before surgery may reduce postoperative bleeding.

Furthermore, Chapman *et al.* described an elective abdominal aortic aneurysm repair complicated by diffuse hemorrhage resulting from combined therapy.⁹ The editor of the journal in which this was published replied with the knowledge of at least two other cases where combined therapy caused excessive blood loss during carotid endarterectomy.¹⁰

Recently, a study by Payne *et al.* investigating the effect of combined clopidogrel and aspirin on bleeding times in healthy volunteers found after 2 days treatment with clopidogrel 75 mg and 150 mg aspirin per day there was a significant 3.4-fold increase in bleeding time relative to baseline. The authors suggest that combination clopidogrel and aspirin therapy in major cardiovascular or general surgical patients may carry a significantly increased risk of bleeding.¹¹

Surgeons and anesthesiologists are now increasingly likely to encounter patients on combined clopidogrel and aspirin therapy presenting for elective and emergency surgery. These two cases demonstrate perioperative bleeding associated with continued combined aspirin and clopidogrel therapy. In both cases the bleeding was delayed in that it was not obvious until the end of surgery. As a result both patients required unanticipated emergency intubation and intensive care admission and needed unanticipated surgical reexploration and increased blood product transfusion.

The increased risk of intraoperative and postoperative bleeding should be of concern. Timely discontinuation of these agents before surgery to reduce perioperative bleeding must be balanced against the benefit of combined antiplatelet therapy in the prevention of thrombotic events.

References

1. D'Sa S, Machin SJ: Clopidogrel: a novel antiplatelet agent. *Hosp Med* 1999; 60:362-3
2. Calvin JE, Klein LW: The use of antiplatelet agents in acute cardiac care. *Crit Care Clin* 2001; 17:365-77
3. Quinn MJ, Fitzgerald DJ: Ticlopidine and clopidogrel. *Circulation* 1999; 100:1667-72
4. Serebruanu VL, Malinin AI, Jerome SD, Lowry DR, Morgan AW, Sane DC, Tanguay JF, Steinhubl SR, O'Connor CM: Effects of clopidogrel and aspirin combination versus aspirin alone on platelet aggregation and major receptor expression in patients with heart failure: The Plavix Use for Treatment of Congestive Heart Failure (PLUTO-CHF) Trial. *Am Heart J* 2003; 146:713-20
5. Clopidogrel Versus Aspirin in Patients at Risk of Ischaemic Events Steering Committee: A randomized, blinded, trial of clopidogrel versus aspirin in patients at risk of ischaemic events (CAPRIE). *Lancet* 1996; 348:1329-39
6. Yusuf S, Phil D, Zhao F, Mehta SR, Chrolavicius S, Tognoni G, Fox KK, The Clopidogrel in Unstable Angina to Prevent Recurrent Events Trial Investigators: Effects of clopidogrel in addition to aspirin in patients with acute coronary syndromes without ST-segment elevation. *N Engl J Med* 2001; 345:494-502
7. Yusuf S, Mehta S: Treatment of acute coronary syndromes. *N Engl J Med* 2002; 346:206-8

8. Yende S, Wunderlink RG: Effect of clopidogrel on bleeding after coronary artery bypass surgery. *Crit Care Med* 2001; 29:2271-5

9. Chapman TW, Bowley DM, Lambert AW, Walker AJ, Ashley SA, Wilkins DC: Haemorrhage associated with combined clopidogrel and aspirin therapy. *Eur J Vasc Endovasc Surg* 2001; 22:478-9

10. Beard JD: Haemorrhage associated with combined clopidogrel and aspirin therapy. *Eur J Vasc Endovasc Surg* 2001; 22:478-9

11. Payne DA, Hayes PD, Jones CI, Belham P, Naylor AR, Goodall AH: Combined therapy with clopidogrel and aspirin significantly increases the bleeding time through a synergistic antiplatelet action. *J Vasc Surg* 2002; 35:1204-9

Anesthesiology 2004; 101:794-5

© 2004 American Society of Anesthesiologists, Inc. Lippincott Williams & Wilkins, Inc.

Intravenous Ziprasidone for Treatment of Delirium in the Intensive Care Unit

Christopher C. Young, M.D., F.C.C.M.,* Eugenio Lujan, M.D.†

PATIENTS in the intensive care unit (ICU) are at high risk of developing delirium. Delirium is an independent determinant of hospital length of stay and may be associated with increased morbidity and mortality. Although estimates of the incidence of delirium in the ICU vary considerably, it is widely recognized as difficult to diagnose and treat. Standard therapy for delirium and agitation in the ICU is intravenous haloperidol. However, haloperidol is sometimes ineffective in managing delirious patients and large doses pose an increased risk of side effects. Newer "atypical" antipsychotic agents are equivalent to traditional agents in controlling psychomotor agitation in acutely psychotic patients.¹ It is not currently known whether they have a role in treating delirium in ICU patients. Ziprasidone (Geodon®; Pfizer Pharmaceuticals, New York, NY), one of the new atypical agents, is the only one that is currently available as a parenteral formulation. In this report, we describe the first successful use of ziprasidone *via* the intravenous route in an ICU patient with severe, life-threatening delirium that failed to respond to standard haloperidol therapy.

Case Report

A 47-yr-old, 112-kg man was admitted to the trauma/surgical ICU after placement of a free fibular graft to the left clavicle. His medical history was significant for hypertension treated with a β -blocker, elevated cholesterol, anxiety, and depression. Home medications included clonazepam, mirtazepine, risperidone, and acetaminophen/oxycodone. The patient drank alcohol, occasionally heavily, and had a 30-pack/yr cigarette smoking history.

On the first postoperative day, cisatracurium, propofol, and fentanyl infusions were discontinued, and the patient was extubated. Atenolol, clonazepam, and transdermal clonidine were prescribed. Several hours

later the patient became confused and agitated. He was unable to maintain attention and demonstrated disorientation and perceptual disturbances. Continuous intravenous hydromorphone, up to 2.5 mg/h and lorazepam 2 mg intravenously every 6 h and every 1 h as needed were given for pain and agitation. Despite escalating doses of intravenous lorazepam (4 mg bolus + 12 mg/h continuous infusion), the patient remained delirious and dangerously agitated. Intravenous haloperidol 2 mg, 5 mg, 10 mg, and 20 mg had no effect on the agitation. The viability of the fibular graft was at risk because of his delirium; he was therefore sedated and reintubated. Dexmedetomidine loading dose and continuous infusion were initiated while haloperidol and lorazepam were continued. Despite multiple combinations of sedative agents, the patient was either well-sedated and hypotensive (further worsening graft blood flow) or delirious and agitated, risking disruption of the vascular pedicle of the free fibular graft.

Because of the severity of delirium and absence of response to haloperidol, ziprasidone therapy was considered. Corrected QT interval (QTc) was found to be 470 ms; serum potassium and magnesium levels were determined to be normal. Ziprasidone 20 mg was given intravenously. QTc was 476 ms 5 min later and the patient's restlessness dramatically improved. Haloperidol, dexmedetomidine, and hydromorphone were gradually discontinued. QTc 4 h after ziprasidone administration decreased to 436 ms. The patient was extubated and ziprasidone and lorazepam were tapered *via* the oral route. Ziprasidone was discontinued 1 week later. The patient was transferred from the ICU on postoperative day 8 receiving oral methadone and lorazepam.

Discussion

Delirium is characterized by an acute change in cognition and disturbance in consciousness, usually resulting from an underlying medical condition or from medication or drug withdrawal. Estimates of the incidence of delirium in the ICU vary from 20-80%.² Patients suffering from delirium while hospitalized in the ICU have prolonged lengths of ICU and overall hospital stay, more frequent medical complications, and increased mortality.^{3,4}

The mainstay of therapy for agitation and delirium in the ICU is intravenous haloperidol, a potent antipsychotic agent that blocks dopaminergic receptors in the central nervous system.^{5,6} A recent clinical practice guideline published by the American College of Critical Care Medicine recommends haloperidol for treatment of agitation and delirium, although the level of recommendation is graded C.⁵

Haloperidol is associated with antidopaminergic side effects, including extrapyramidal effects and tardive dyskinesia, and can cause prolongation of the QT-interval on

* Assistant Professor of Anesthesiology, Division of Critical Care Medicine; † Fellow in Critical Care Medicine, Department of Anesthesiology, Duke University Medical Center, Durham, North Carolina.

Received from the Department of Anesthesiology and the Division of Critical Care Medicine, Duke University Medical Center, Durham, North Carolina. Submitted for publication December 31, 2003. Accepted for publication March 31, 2004. Support was provided solely from institutional and/or departmental sources. Dr. Young has served on the speaker's bureau for Abbott Pharmaceuticals (Abbott Park, Illinois).

Address reprint requests to Dr. Young: Department of Anesthesiology, Box 3094, Medical Center, Durham, NC 27710. Address electronic mail to: young024@mc.duke.edu. Individual article reprints may be purchased through the Journal Web site, www.anesthesiology.org.

electrocardiogram. QT-interval prolongation can lead to an increased risk of ventricular arrhythmias, including torsades de pointes.^{7,8} Sharma *et al.* found the incidence of torsades de pointes associated with intravenous haloperidol was significantly greater in patients receiving 35 mg or more over 24 h and in those with a QTc of >500 ms.⁹

Newer “atypical” antipsychotic agents have been recently introduced. Because these agents exert their effect mainly through modulation of nondopaminergic pathways, their use may result in diminished incidence of tardive dyskinesia. Ziprasidone can prolong the QT interval and thereby increase the risk of ventricular arrhythmias, including torsades de pointes.¹⁰ For this reason, ziprasidone is contraindicated in patients with corrected QT interval (QTc) prolongation >500 ms, recent myocardial infarction, or uncompensated heart failure. It can produce additive effects with other agents known to prolong QT interval and therefore, close hemodynamic monitoring, including five-lead electrocardiogram, is warranted. Ziprasidone should also be avoided in patients with congenital long QT syndrome and in patients with a history of cardiac arrhythmias. Food and Drug Administration-mandated studies of QT prolongation associated with neuroleptic administration demonstrated a mean increase of QTc of 20.3 ms for ziprasidone *versus* 4.7 ms with haloperidol.¹¹ In clinical trials of ziprasidone, the electrocardiograms of two of 2,988 patients (0.06%) who received ziprasidone and one of 440 (0.23%) who received placebo revealed QTc intervals exceeding the potentially clinical relevant threshold of 500 ms.¹²

Ziprasidone is the only atypical antipsychotic agent that is currently formulated for parenteral administration. Usual adult dosing is 10–20 mg intramuscularly as required to a maximum dose of 40 mg a day. Doses of 10 mg may be administered every 2 h; doses of 20 mg may be administered every 4 h. There appear to be no anticholinergic effects associated with its use. Half-life is 6–7 h.¹³ Use of the intramuscular preparation for more than 3 days has not been studied; every effort should be made to convert to oral dosing as early as possible. Intramuscular administration of ziprasidone in healthy volunteers demonstrated time to peak plasma level of 60 min.¹² More rapid control of symptoms, however, is often necessary in the treatment of a patient with severe agitation necessitating intravenous administration. Phase I clinical trials of intravenous ziprasidone administered as a 60-min infusion demonstrated pharmacokinetics similar to intramuscular administration. Further experience with intravenous administration is lacking.

Published studies support the use of atypical antipsychotics in the treatment of delirium in hospitalized, medically ill patients. Olanzapine, quetiapine, and risperidone have all been reported to improve the symptoms of

delirium in small, uncontrolled trials.¹⁴ The only published case report describing ziprasidone treatment in delirium utilized oral dosing in a patient with cryptococcal meningitis as a result of human immunodeficiency virus.¹⁵

This report is the first of the use of intravenous ziprasidone to control delirium in an agitated, critically ill patient in the ICU. Delirium remains a daunting clinical challenge in the practice of intensive care medicine. It can be difficult to diagnose and treat and is associated with worsened patient outcomes. The recent availability of newer atypical antipsychotic agents offers an alternative approach to the treatment of delirium. Because this is only the first report of the use of intravenous ziprasidone to treat ICU-related delirium refractory to standard haloperidol treatment, much further investigation remains. The use of such therapy is anecdotal and the risks—including QT prolongation and ventricular arrhythmia—must be considered. Only appropriately powered, prospective, randomized trials will be able to satisfactorily answer questions of safety and efficacy that this novel therapy raises.

References

1. Brook S, Lucey JV, Gunn KP: Intramuscular ziprasidone compared with intramuscular haloperidol in the treatment of acute psychosis. *J Clin Psych* 2000; 61:933–41
2. Ely EW, Inouye SK, Bernard GR, Gordon S, Francis J, May L, Truman B, Speroff T, Gautam S, Margolin R, Hart RP, Dittus R: Delirium in mechanically ventilated patients: Validity and reliability of the confusion assessment method for the intensive care unit (CAM-ICU). *JAMA* 2001; 286:2703–10
3. Ely EW, Gautam S, Margolin R, Francis J, May L, Speroff T, Truman B, Dittus R, Bernard R, Inouye SK: The impact of delirium in the intensive care unit on hospital length of stay. *Intensive Care Med* 2001; 27:1892–900
4. McCusker J, Cole M, Abrahamowicz M, Han L, Podoba JE, Ramman-Haddad L: Environmental risk factors for delirium in hospitalized older people. *J Am Geriatr Soc* 2001; 49:1327–34
5. Jacobi J, Fraser GL, Coursin DB, Riker RR, Fontaine D, Wittbrodt ET, Chalfin DB, Mascia MF, Bjerke HS, Coplin WM, Crippen DW, Fuchs BD, Kelleher RM, Marik PE, Nasraway SA Jr., Murray MJ, Peruzzi WT, Lumb PD, Task Force of the American College of Critical Care Medicine (ACCM) of the Society of Critical Care Medicine (SCCM), American Society of Health-System Pharmacists (ASHP), American College of Chest Physicians: Clinical practice guidelines for the sustained use of sedatives and analgesics in the critically ill adult. *Crit Care Med* 2002; 30:119–41
6. Riker RR, Fraser GL, Cox PM: Continuous infusion of haloperidol controls agitation in critically ill patients. *Crit Care Med* 1994; 22:433–40
7. Metzger E, Friedman R: Prolongation of the corrected QT and torsades de pointes cardiac arrhythmia associated with intravenous haloperidol in the medically ill. *J Clin Psychopharmacol* 1993; 13:128–32
8. Wilt JL, Minnema AM, Johnson RF, Rosenblum AM: Torsades de pointes associated with the use of intravenous haloperidol. *Ann Intern Med* 1993; 119:391–4
9. Sharma ND, Rosman HS, Padhi D, Tisdale JE: Torsades de pointes associated with intravenous haloperidol in critically ill patients. *Am J Cardiol* 1998; 81:238–40
10. Glassman AH, Bigger JT: Anti-psychotic drugs: prolonged QTc interval, torsade de pointes, and sudden death. *Am J Psychiatry* 2001; 158:1774–82
11. Psychopharmacological Drugs Advisory Committee: Briefing document for Zeldox capsules (Ziprasidone HCl). Rockville, MD: Food and Drug Administration of the United States Department of Health and Human Services; July 19, 2000. NDA-825: 1–173
12. Pfizer Pharmaceuticals, Inc. Geodon [package insert]. New York, NY: Pfizer, 2002
13. Caley CF, Cooper CK: Ziprasidone: The fifth atypical antipsychotic. *Ann Pharmacother* 2002; 36:839–51
14. Schwartz TL, Masand PS: The role of atypical antipsychotics in the treatment of delirium. *Psychosomatics* 2002; 43:171–4
15. Leso L, Schwartz TL: Ziprasidone treatment of delirium. *Psychosomatics* 2002; 43:61–2

See www.torsades.org for a listing of agents known to prolong QT interval; URL accessed March 23, 2004.