

## Metabolic Acidosis Associated with Propofol in the Absence of Other Causative Factors

Bethanie K. Burow, M.D.,\* Michael E. Johnson, M.D., Ph.D.,† Douglas L. Packer, M.D.‡

PROPOFOL is commonly used for intensive care unit sedation and prolonged procedures in the adult population where both deep sedation and quick emergence are required. Several recent reports have described a “propofol infusion syndrome,” occurring in both pediatric<sup>1–7</sup> and adult<sup>2,8–10</sup> patients receiving prolonged high-dose infusions of propofol ( $> 75 \mu\text{g} \cdot \text{kg}^{-1} \cdot \text{min}^{-1} \times > 24 \text{ h}$ ). The syndrome is characterized as a severe metabolic acidosis, sometimes associated with myocardial dysfunction, rhabdomyolysis, or death. Although some reports have documented high anion gap, lactic acidosis, others have documented only a metabolic acidosis without further characterization. All cases of propofol infusion syndrome reported thus far have occurred in critically ill patients receiving multiple other drugs, creating some controversy as to whether propofol alone was its cause.<sup>11–13</sup> We now report a case of metabolic acidosis, without ventilatory depression or hypoxia, in an otherwise healthy patient receiving propofol as the sole anesthetic agent during an ablation for atrial fibrillation. Approval for this case review was obtained from the institutional review board of the Mayo Clinic College of Medicine.

### Case Report

A 31-yr-old woman (weight, 99.2 kg; height, 162 cm) with chronic atrial fibrillation was scheduled to undergo radiofrequency ablation for pulmonary vein isolation. She had a history of atrial fibrillation since the age of 22 yr and was minimally symptomatic, with no evidence of rate-related ventricular dysfunction or thromboembolic events. Except for occasional gastric reflux, she was otherwise healthy. She had reported “waking up early” during a previous anesthetic. Echocardi-

ography showed normal ventricular function with a left ventricular ejection fraction of 55% and mild atrial enlargement. Medications were limited to 50 mg atenolol daily (stopped 4 days before ablation), 325 mg aspirin daily, and oral contraceptives. Preoperative laboratory results were unremarkable, including 11.5 g/dl hemoglobin, 0.9 mg/dl creatinine, 138 mEq/l  $\text{Na}^+$ , and 4.9 mEq/l  $\text{K}^+$ .

The initial anesthetic plan was to use propofol as the sole sedative, based on its rapid metabolism and the clinical impression that propofol suppresses arrhythmogenic foci during radiofrequency ablation to a lesser extent than other available anesthetic agents. Monitoring included electrocardiography, pulse oximetry, continuous carbon dioxide monitoring of gas sampled at the nares, a femoral arterial catheter, and a urinary catheter. Because of the potential for respiratory depression with prolonged deep sedation in a nonintubated patient, arterial blood gas analyses were obtained intermittently during the procedure.

Sedation was induced with  $25 \mu\text{g} \cdot \text{kg}^{-1} \cdot \text{min}^{-1}$  propofol with supplemental oxygen by facemask at 4 l/min. The Diprivan® Injectable Emulsion formulation of propofol (AstraZeneca, Wilmington, DE) was used throughout, containing 10 mg/ml propofol and 0.005% disodium edetate. The exact vial sizes used were not recorded on the written anesthesia record. Based on our practice patterns at that time, the propofol infusion was almost certainly administered directly from a 100-ml infusion vial sterily spiked with a solution administration set leading to an infusion pump. The source of supplemental boluses was not specified on the written record but would have been either from the 100-ml infusion vial already in use or from a 20-ml glass vial opened separately. Our practice is to discard unused propofol at the end of each case, so that vials would have been opened fresh for this case. The case reported was the first case of the day, and vials would have been open no longer than 1 h before the case. Lot numbers and expiration dates for the vials of propofol used could not be identified on retrospective inspection.

The rate of propofol infusion was quickly increased to assist with patient immobility and ranged from 50 to  $125 \mu\text{g} \cdot \text{kg}^{-1} \cdot \text{min}^{-1}$  throughout the procedure, together with intermittent boluses. The course of propofol therapy and arterial blood gases during the procedure is shown in figure 1. The average rate at which propofol was administered was  $83 \mu\text{g} \cdot \text{kg}^{-1} \cdot \text{min}^{-1}$ , over a period of 395 min. An acidosis progressively developed, which was entirely metabolic. Pulse oximetry documented oxygen saturation ( $\text{SpO}_2$ ) greater than 95% at all times, and arterial oxygen tension ( $\text{PaO}_2$ ) and arterial carbon dioxide tension ( $\text{PaCO}_2$ ) showed no evidence of hypoxia or respiratory depression on any arterial blood gas. There was no prolonged hypotension, and the average urine output was 250 ml/h throughout the procedure. Blood loss was minimal. The only other drug therapies used while propofol was administered were heparin, cefazolin, and 2 mg midazolam given as 1 mg at 51 min and  $2 \times 0.5 \text{ mg}$  at 180 min after the start of anesthesia.  $\text{Na}^+$  and  $\text{K}^+$  at 51 and 194 min were 142 and 4.2 mEq/l and 142 and 4.0 mEq/l, respectively.

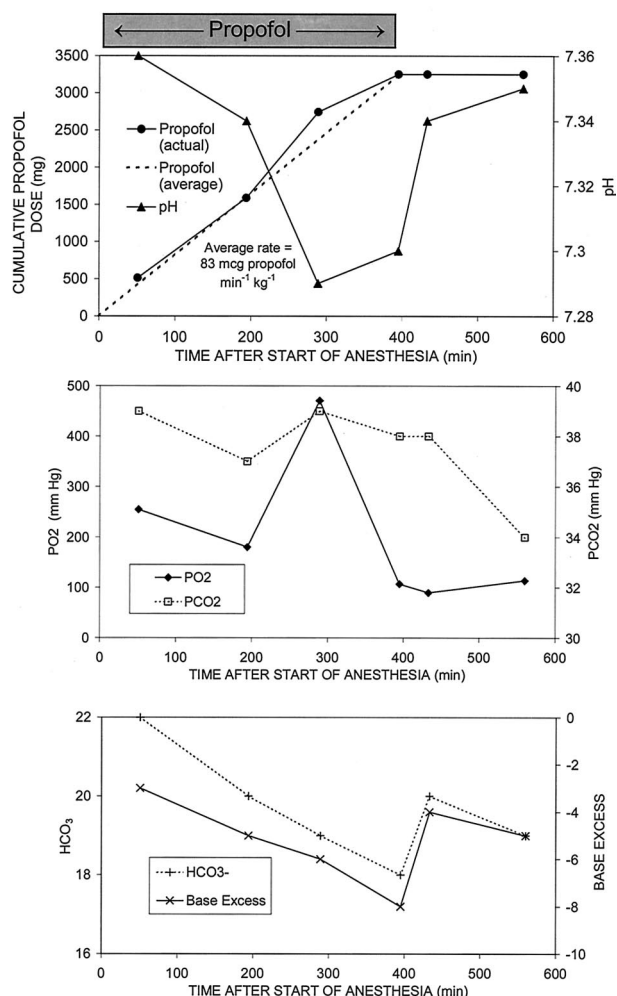
At 395 min, the pH was 7.30, and base excess was  $-8$ . Because of patient restlessness and movement despite heavy sedation, intermittent airway obstruction requiring manual positioning to correct, and concern about an evolving metabolic acidosis with high-dose propofol, the patient was intubated and mechanically ventilated. The propofol infusion was discontinued, and no further propofol boluses were given. Total intravenous fluid to this point was between 2 and 3 l saline, 0.9%. A fentanyl infusion at  $17\text{--}34 \text{ ng} \cdot \text{kg}^{-1} \cdot \text{min}^{-1}$  with 75%  $\text{N}_2\text{O}$  was begun and continued for the rest of the procedure. Sodium bicarbonate 15 mEq was given at 475 min, but the largest change in pH and base excess toward normal occurred between discontinuation of propofol at 395 min and the blood gas sampled at 433 min. By 560 min,

This article is accompanied by an Editorial View. Please see: Funston JS, Prough DS: Two reports of propofol anesthesia associated with metabolic acidosis in adults. ANESTHESIOLOGY 2004; 101:6–8.

\* Resident, Transitional Year, Gundersen Lutheran Medical Center, LaCrosse, Wisconsin. † Assistant Professor of Anesthesiology, ‡ Professor of Medicine, Mayo Clinic College of Medicine, Rochester, Minnesota.

Received from the Anesthesiology Department, Mayo Clinic College of Medicine. Submitted for publication October 15, 2003. Accepted for publication February 3, 2004. Supported by the Mayo Foundation, Rochester, Minnesota. Presented in preliminary form at the Midwest Anesthesia Residents Conference, Omaha, Nebraska, March 10, 2002; the Third International Interdisciplinary Congress “EuroNeuro 2002,” Munich, Germany, September 12–14, 2002; and the 30th Annual Meeting of the Society of Neurosurgical Anesthesia and Critical Care, Orlando, Florida, October 11, 2002.

Address correspondence to Dr. Johnson: Mayo Clinic Anesthesiology SMH 2-MB, 200 Southwest First Street, Rochester, Minnesota 55905. Address electronic mail to: johnson.michael@mayo.edu. Individual article reprints may be purchased through the Journal Web site, www.anesthesiology.org.



**Fig. 1. Propofol administration and changes in arterial blood gas values in subject of case report. Propofol was stopped at 395 min, and the patient was intubated and mechanically ventilated at 400 min. Note subsequent improvement in pH, bicarbonate ( $\text{HCO}_3^-$ ), and base excess beyond that predicted by mild decrease in partial pressure of carbon dioxide ( $\text{PCO}_2$ ). Note also partial pressure of oxygen ( $\text{PO}_2$ ) greater than 100 mmHg during propofol administration. The increased  $\text{PO}_2$  at 289 min was due to supplemental mask oxygen administered during manual correction of transient airway obstruction.**

the metabolic acidosis had partially resolved. At the end of the procedure at 720 min, the trachea was extubated without complications. Total intravenous fluid during the procedure was 5.85 l saline, 0.9%. No further arterial blood gas analyses were obtained on the day of the procedure. After the procedure, the patient had normal physical examination results and no complaints. Laboratory values obtained 2–4 days after the procedure were unremarkable:  $\text{Na}^+$ , 137–139 mEq/L;  $\text{K}^+$ , 3.5–3.9 mEq/L;  $\text{Cl}^-$  103–106 mEq/L; venous  $\text{HCO}_3^-$  25–26 mEq/L; anion gap, 8.

## Discussion

We report the development of significant, reversible, metabolic acidosis without ventilatory depression or hypoxia in a healthy patient receiving high-dose propofol and no other drugs likely to cause metabolic acidosis. The mechanism for this mild probable propofol infusion

syndrome remains unclear. There was no evidence of renal failure causing decreased excretion of endogenous acids or increased loss of bicarbonate. Moreover, venous bicarbonate, creatinine, and anion gap values obtained after the procedure were normal, showing the absence of underlying chronic renal disease.

Increased lactic acid production caused by low cardiac output or a regional steal syndrome must be considered because propofol is both a cardiac depressant and vasoactive,<sup>14</sup> and cardiac failure has been reported with the propofol infusion syndrome.<sup>1,2</sup> However, cardiac failure with propofol is usually a late, fatal development after metabolic acidosis, rather than an early cause of metabolic acidosis. This patient's hemodynamics, urine output, and stable renal status argue against cardiovascular failure as the proximate cause of her metabolic acidosis.

Another potential cause of this patient's metabolic acidosis is impaired hepatic lactate metabolism. In several cases of propofol infusion syndrome, the development of a fatty or enlarged liver has been reported, and a case of isolated severe hepatotoxicity associated with propofol has also been reported.<sup>15</sup> The patient reported here did not have liver function laboratory tests, but she had no clinical evidence of hepatic disease before or after the procedure.

There is both *in vitro*<sup>16</sup> and clinical<sup>7</sup> evidence that high doses of propofol can inhibit mitochondrial respiration, which could cause metabolic acidosis. The glucuronide and sulfate products of phase II propofol metabolism are unlikely to be toxic, but the intermediate dihydroxylated products are poorly characterized and potentially interconvertible to toxic quinones. Propofol quinone has been synthesized, and preliminary evidence has been presented of its mitochondrial toxicity.<sup>17</sup> Both a direct and a metabolite mitochondrial toxicity of propofol would be consistent with the idiosyncratic appearance of the propofol infusion syndrome, requiring both a sustained, high-dose infusion and as yet undetermined genetic variants of propofol clearance and metabolism.

Sepsis can lead to metabolic acidosis and could occur with contaminated propofol because its lipid emulsion is a good culture medium.<sup>18</sup> Here, the lack of fever and sustained hypotension and the uneventful postoperative recovery argue against sepsis in this patient. No exogenous acid load was administered to this patient; she received only the Diprivan<sup>®</sup> formulation of propofol (pH 7.5–8.0), rather than a generic formulation (pH 4.5–6.4; Baxter Healthcare Corporation, New Providence, NJ).

Rapid administration of large volumes of 0.9% intravenous saline can cause dilutional acidosis.<sup>19,20</sup> Unfortunately, the concentration of serum chloride, which would have clarified the contribution of saline administration to this patient's acidosis, was not determined during the acidosis. However, comparison to published studies of dilutional acidosis suggests that 0.9% saline is unlikely to account for all of this patient's acidosis. In adult gynecologic surgery patients receiving 6 l saline, 0.9%, over 2 h, base

excess decreased to  $-6.7$  mm by 2 h.<sup>20</sup> Such dilutional changes require rapid administration of volumes beyond the ability of native homeostatic mechanisms to compensate.<sup>19</sup> At the time of intubation, our patient had received at most 3 l saline, 0.9%, over 6.5 h, with a base excess of  $-8$ . Hence, compared with that study,<sup>20</sup> our patient had a more negative base excess despite receiving half the saline volume over more than triple the time period, with more time for urinary response to a putative dilutional acidosis. Furthermore, her acidosis improved after the propofol was stopped, although she received a similar volume (at least 2.85 l) of 0.9% saline over the final 5.5 h of the anesthetic.

In conclusion, the case reported here is significant because it is the first documented example of propofol potentially causing metabolic acidosis in the absence of any other drug likely to cause acidosis and without any other reasonable causative factors. It suggests that propofol infusion syndrome is in fact due to propofol or a propofol metabolite, is reversible in its early stages, and is consistent with previous cautions to avoid high-dose, prolonged infusions of propofol.<sup>1,2</sup> It also illustrates the utility of monitoring arterial blood gases in cases where the advantages of propofol infusion greater than  $75 \mu\text{g} \cdot \text{kg}^{-1} \cdot \text{min}^{-1}$  for more than a few hours seem to outweigh its risks.

## References

- Bray RJ: Propofol infusion syndrome in children. *Paediatr Anaesth* 1998; 8:491-9
- Cremer OL, Moons KG, Bouman EA, Kruijswijk JE, de Smet AM, Kalkman CJ: Long-term propofol infusion and cardiac failure in adult head-injured patients. *Lancet* 2001; 357:117-8
- Cray SH, Robinson BH, Cox PN: Lactic acidemia and bradyarrhythmia in a child sedated with propofol. *Crit Care Med* 1998; 26:2087-92
- Hanna JP, Ramundo ML: Rhabdomyolysis and hypoxia associated with prolonged propofol infusion in children. *Neurology* 1998; 50:301-3
- Hatch DJ: Propofol-infusion syndrome in children. *Lancet* 1999; 353:1117-8
- Kelly DF: Propofol-infusion syndrome. *J Neurosurg* 2001; 95:925-6
- Wolf A, Weir P, Segar P, Stone J, Shield J: Impaired fatty acid oxidation in propofol infusion syndrome. *Lancet* 2001; 357:606-7
- Perrier ND, Baerga-Varela Y, Murray MJ: Death related to propofol use in an adult patient. *Crit Care Med* 2000; 28:3071-4
- Stelow EB: Propofol-associated rhabdomyolysis with cardiac involvement in adults: Chemical and anatomic findings. *Clin Chem* 2000; 46:577-81
- Badr AE, Mychaskiw G II, Eichhorn JH: Metabolic acidosis associated with a new formulation of propofol. *ANESTHESIOLOGY* 2001; 94:536-8
- Nimmo GR, Mackenzie SJ, Grant IS: Haemodynamic and oxygen transport effects of propofol infusion in critically ill adults. *Anaesthesia* 1994; 49:485-9
- Kelly DF, Goodale DB, Williams J, Herr DL, Chappell ET, Rosner MJ, Jacobson J, Levy ML, Croce MA, Maniker AH, Fulda GJ, Lovett JV, Mohan O, Narayan RK: Propofol in the treatment of moderate and severe head injury: A randomized, prospective double-blinded pilot trial. *J Neurosurg* 1999; 90:1042-52
- Reed MD, Blumer JL: Propofol bashing: The time to stop is now! *Crit Care Med* 1996; 24:175-6
- Ririe DG, Lundell JC, Neville MJ: Direct effects of propofol on myocardial and vascular tissue from mature and immature rats. *J Cardiothorac Vasc Anesth* 2001; 15:745-9
- Anand K, Ramsay MA, Crippin JS: Hepatocellular injury following the administration of propofol. *ANESTHESIOLOGY* 2001; 95:1523-4
- Schenkman KA, Yan S: Propofol impairment of mitochondrial respiration in isolated perfused guinea pig hearts determined by reflectance spectroscopy. *Crit Care Med* 2000; 28:172-7
- Johnson ME, Fauq AH, Uhl CB: Effect of propofol and propofol quinone on hydroxyl radical generation (abstract). *Free Radic Biol Med* 2002; 33(suppl 1):S202
- Bennett SN, McNeil MM, Bland LA, Arduino MJ, Villarino ME, Perrotta DM, Burwen DR, Welbel SF, Pegues DA, Stroud L, Zeitz PS, Jarvis WR: Postoperative infections traced to contamination of an intravenous anesthetic, propofol. *N Engl J Med* 1995; 333:147-54
- Prough DS, White RT: Acidosis associated with perioperative saline administration: Dilution or delusion? *ANESTHESIOLOGY* 2000; 93:1167-9
- Scheingraber S, Rehm M, Schmisch C, Finsterer U: Rapid saline infusion produces hyperchloremic acidosis in patients undergoing gynecologic surgery. *ANESTHESIOLOGY* 1999; 90:1265-70

Anesthesiology 2004; 101:241-3

© 2004 American Society of Anesthesiologists, Inc. Lippincott Williams & Wilkins, Inc.

## Lactic Acidosis during Propofol-Remifentanyl Anesthesia in an Adult

Jean-Corentin Salengros, M.D.,\* Charles-Eric Velghe-Lenelle, M.D.,† Renaud Bollens, M.D.,‡ Edgar Engelman, M.D.,§ Luc Barvais, M.D., Ph.D.¶

PROPOFOL became available for commercial use in the current lipid emulsion formulation 20 yr ago.<sup>1</sup> Its superior

properties in terms of anesthetic recovery were quickly recognized, and its use became widespread.<sup>2</sup> The drug has a remarkable safety record in anesthetic practice when used as an intravenous induction agent or for intravenous maintenance of anesthesia. The widespread use of propofol for short-term (< 24 h) sedation in intensive care units (ICUs) has led to an increased interest in long-term use (> 72 h).<sup>3</sup> The use of propofol in this context, particularly at high doses (e.g., for cerebral metabolic suppression in brain trauma), has been associated with a range of toxic reactions, including metabolic acidosis, rhabdomyolysis, myocardial failure and death.<sup>4-6</sup> The role of propofol in these reactions has been debated vigorously in the literature.<sup>7-9</sup> We present the case of a severe nonfatal metabolic acidosis related to short-term propofol administration during anesthesia in an adult patient.

This article is accompanied by an Editorial View. Please see: Funston JS, Prough DS: Two reports of propofol anesthesia associated with metabolic acidosis in adults. *ANESTHESIOLOGY* 2004; 101:6-8.

\* Staff Anaesthesiologist, † Assistant Professor, § Associate Professor, ¶ Professor and Head of Department, Department of Anaesthesiology, ‡ Staff Urologist, Department of Urology, CUB Hôpital ERASME.

Received from the Departments of Anaesthesiology and Urology, CUB Hôpital ERASME, Brussels, Belgium. Submitted for publication November 10, 2003. Accepted for publication February 3, 2004. Support was provided solely from institutional and/or departmental sources.

Address correspondence to Dr. Salengros: Department of Anaesthesiology, Hôpital ERASME, 808, Route de Lennik, 1070 Brussels, Belgium. Address electronic mail to: Jean.Salengros@ulb.ac.be. Individual article reprints may be purchased through the Journal Web site, [www.anesthesiology.org](http://www.anesthesiology.org).

Anesthesiology, V 101, No 1, Jul 2004



## Case Report

A 64-yr-old, 71-kg man was scheduled to undergo laparoscopic radical prostatectomy for treatment of prostatic adenocarcinoma. The patient had a history of an uneventful, bilateral, inguinal hernia repair during general anesthesia. He had recently been treated with 40 mg pantoprazole daily for a gastric ulcer and was taking 80 mg gliclazide twice daily for mature-onset diabetes. The patient was in excellent condition before surgery. The usual preoperative test results were strictly normal.

The evening before surgery, the patient received 20 mg hypodermic enoxaparin and 0.5 mg oral alprazolam. On the morning of surgery, he took his 40 mg oral pantoprazole and received an intramuscular injection of 5 mg midazolam.

The patient was anesthetized with a total intravenous technique using 1% propofol (Diprivan-prefilled syringes, sealed until use; produced by AstraZeneca S.p.A., Caponago, Italy, and packaged by AstraZeneca UK Limited, Macclesfield, Cheshire, United Kingdom) and remifentanyl, with muscle relaxation being achieved by continuous administration of mivacurium (total amount of propofol: 2500 mg; total amount remifentanyl: 6 mg, both infused over approximately 4.5 h).

Surgery went on without any problems, but, after approximately 3 h of anesthesia, the patient suddenly became tachycardic (100–110 beats/min) although his heart rate had been between 45 and 60 beats/min until then. The blood gases, then realized, showed the following: pH, 7.43; partial pressure of oxygen ( $P_{O_2}$ ), 210 mmHg; partial pressure of carbon dioxide ( $P_{CO_2}$ ), 36.9 mmHg; lactate, 1.45 mm; bicarbonate ( $HCO_3^-$ ), 25.1 mm; base excess, 1.6 mm; glucose, 113 mg/dl; hemoglobin, 13.0 mg/dl.

The surgical procedure continued uneventfully. The patient remained stable hemodynamically, and no arrhythmias were noted. The patient was normothermic (36.5°C), was not bleeding actively, and had a diuresis of approximately 1.5 ml · kg<sup>-1</sup> · h<sup>-1</sup>.

The subsequent blood gases, tested 1 h later, showed a moderate metabolic acidosis: pH, 7.28;  $P_{O_2}$ , 177 mmHg;  $P_{CO_2}$ , 43.5 mmHg; lactate, 6.99 mm;  $HCO_3^-$ , 20.8 mm; base excess, -5.1 mm; glucose, 136 mg/dl; hemoglobin, 12.1 mg/dl.

Acidosis increased in the following hour despite volume administration with crystalloids (1 l normal saline) and colloids (1 l hydroxyethyl starch, 6%). The blood gases were as follows: pH, 7.26;  $P_{O_2}$ , 155 mmHg;  $P_{CO_2}$ , 41.9 mmHg; lactate, 8.2 mm;  $HCO_3^-$ , 19.1 mm; base excess, -6.9 mm; glucose, 125 mg/dl; hemoglobin, 10.7 mg/dl.

By that time, surgery had ended, and because the source of the acidosis was unclear, transesophageal echocardiography was performed, which showed good left and right contractility, adequate ventricular filling, and an adequate cardiac output of approximately 8.5 l/min. Furthermore, the abdominal cavity was searched for any septic source or hepatic necrosis, without success. It was then decided to transfer the patient, sedated and intubated, to the ICU. The last blood gases showed the following: pH, 7.28;  $P_{O_2}$ , 162 mmHg;  $P_{CO_2}$ , 39.6 mmHg; lactate, 8.57 mm;  $HCO_3^-$ , 18.9 mm; base excess, -6.7 mm; glucose, 129 mg/dl; hemoglobin, 10.7 mg/dl. The total amount of fluids given during the procedure consisted of 3 l normal saline and 1 l hydroxyethyl starch, 6%.

Because the source of the lactic acidosis was believed to be the propofol infusion, in the ICU, the mode of sedation was changed to intravenous midazolam. Morphine was added to treat postoperative pain. The patient experienced mild pyrexia during the following hour. Blood cultures were taken, and antibiotic therapy was started empirically (2 g intravenous amoxicillin clavulanate every 8 h and 500 mg intravenous amikacin every 8 h).

No alterations in blood parameters were observed except the metabolic acidosis (lactate, 8.9 mm); there were no signs of rhabdomyolysis (creatinine kinase, 149 U/l [normal, 0–190 U/l]), no signs of heart ischemia (creatinine kinase MB < 15 U/l [normal, 0–24 U/l]; troponin I < 0.4 U/l [normal, 0–0.4 U/l]), no alterations in hepatic enzymology (aspartate aminotransferase, 20 U/l [normal, 0–53 U/l]; alanine amino-

transferase, 26 U/l [normal, 0–53 U/l]), no signs of sepsis, and no ketone bodies in the urine.

During the subsequent hours, the clinical condition of the patient improved, and the acidosis resolved completely without any other particular treatment than a change in the mode of sedation and discontinuation of the propofol infusion. The patient was then allowed to wake up, and the trachea was extubated approximately 6 h after admission to the ICU. He made a complete recovery. The results of the blood cultures taken during the ICU admission were negative.

## Discussion

Since 1990, multiple reports in the pediatric literature have raised questions as to whether propofol, given as a long-term infusion, has been responsible for the death of certain pediatric patients.<sup>4–6</sup> In 1992, five cases of metabolic acidosis, bradyarrhythmia, and fatal myocardial failure were reported in children receiving intensive care treatment for upper respiratory tract infections necessitating positive-pressure ventilation.<sup>4</sup> The patients were aged 4 weeks to 6 yr and had received average propofol infusion rates of 7.5–10 mg · kg<sup>-1</sup> · h<sup>-1</sup> for 66–115 h. The total dose of propofol administered over a prolonged period was well outside of past experience with propofol in the anesthetic setting, and the role of propofol in causing death *versus* the usually ascribed sepsis or viral myocarditis in sick patients was intensely debated.<sup>4,7,8</sup>

Other correspondence has attempted to discount the reports of adverse effects of propofol.<sup>9</sup> One study demonstrated that propofol in lower dosages (not exceeding 67 µg · kg<sup>-1</sup> · min<sup>-1</sup>) could safely be used for sedation of critically ill children.<sup>10</sup>

Nevertheless, there seem to be a lethal “syndrome” associated with prolonged (> 24–48 h), high-dose (> 150 µg · kg<sup>-1</sup> · min<sup>-1</sup>) propofol infusion in children. This *propofol infusion syndrome* is defined as sudden, or relative sudden, onset of marked bradycardia, resistant to treatment, with progression to asystole plus one of the following: (1) the presence of lipemia, (2) a clinically enlarged liver secondary to fatty infiltration, (3) the presence of severe metabolic acidosis, or (4) the presence of muscle involvement with evidence of rhabdomyolysis or myoglobinuria.<sup>11</sup>

However, until recently, there have been few reports of propofol infusion syndrome in adults. In 1996, Marinella<sup>12</sup> reported the case of a 30-yr-old woman with asthma exacerbation complicated by acute respiratory failure necessitating mechanical ventilation and sedation that was achieved by intravenous infusion of propofol. After only 2 h of infusion, the patient showed a worsening anion gap, metabolic acidosis, and increased serum lactate. Propofol was discontinued because it was believed that it might have caused metabolic acidosis. Serial measurements showed that pH,  $HCO_3^-$ , and anion gap values subsequently normalized, and the patient was extubated without any problems.

In 2000, Perrier *et al.*<sup>13</sup> reported what was believed to be the first case of death related to propofol infusion in an adult. An 18-yr-old man involved in an automobile accident required sedation with propofol. Based on his weight, he received propofol infusion at a rate of  $5.8 \text{ mg} \cdot \text{kg}^{-1} \cdot \text{h}^{-1}$  for the first 39 h and  $7.6 \text{ mg} \cdot \text{kg}^{-1} \cdot \text{h}^{-1}$  for the remaining 59 h of his ICU stay. On posttrauma day 3, the patient's creatine kinase was increased. On post-trauma day 5, he had atrial fibrillation with rapid ventricular response. Soon after, a left bundle branch block with bradycardia developed. Clinical status was complicated by progressive metabolic acidosis, lipemia, and an increased serum potassium concentration. Myocardial failure ensued, and the patient died secondary to pulseless electrical activity and asystole.

Another report described a dose-dependent association between long-term propofol infusion and cardiac failure in critically ill adults.<sup>14</sup>

In 2001, Badr *et al.*<sup>15</sup> reported a case of metabolic acidosis associated with the use of a new formulation of propofol. The generic propofol used in this case was different in formulation (pH and preservative) than the Diprivan brand we used in our case.

During a recent pediatric case in the ICU setting,<sup>16</sup> important metabolic analysis were performed. The hypothesis to explain this propofol infusion syndrome is consistent with an impairment in free fatty acids oxidation, namely reduced mitochondrial entry of long-chain acylcarnitine esters due to inhibition by propofol of the transport protein carnitine palmitoyl transferase I, and failure of the respiratory chain at complex II, resulting in an imbalance between energy demand and supply, which may lead to lactic acidosis and ultimately to cardiac and peripheral muscle necrosis.

The so-called propofol infusion syndrome mimics the mitochondrial myopathies, in which there are specific defects in the mitochondrial respiratory chain associated with specific mitochondrial DNA abnormalities, resulting in a abnormal lipid metabolism in cardiac and skeletal muscle. These individuals, who are probably genetically susceptible, remain well until stressed by infection or starvation, although subclinical biochemical abnormalities of mitochondrial transport can be demonstrated. During the management of their critical disease, diversion of metabolism to fat substrates may cause "propofol

infusion syndrome." Because adults have larger carbohydrate stores and require lower doses of propofol for sedation, this may account for the relative rarity of this syndrome in adults. It is unclear whether the dose or duration of propofol infusion alters this effect.

No metabolic analyses were performed in the current patient to try to explain the propofol-related metabolic acidosis.

To our knowledge, this is the first case report of severe nonfatal metabolic acidosis probably due to propofol administration in a previously healthy and non-intensive care patient anesthetized with relative low doses of propofol for a short period of time in the perioperative period.

## References

1. Glen JB, Hunter SC: Pharmacology of an emulsion formulation of ICI 35,868. *Br J Anaesth* 1984; 56:617-26
2. Shafer A, Doze VA, Shafer SL, White PF: Pharmacokinetics and pharmacodynamics of propofol infusions during general anesthesia. *ANESTHESIOLOGY* 1988; 69:348-56
3. Kelly DF, Goodale DB, Williams J, Herr DL, Chappell ET, Rosner MJ, Jacobson J, Levy ML, Croce MA, Maniker AH, Fulda GJ, Lovett JV, Mohan O, Narayan RK: Propofol in the treatment of moderate and severe head injury: A randomized, prospective double-blinded pilot trial. *J Neurosurg* 1999; 90:1042-52
4. Parke TJ, Stevens JE, Rice ASC, Greenaway CI, Bray RJ, Smith PJ, Waldmann CS, Verghese C: Metabolic acidosis and fatal myocardial failure after propofol infusion in children: Five cases reports. *BMJ* 1992; 305:613-6
5. Cray SH, Robinson BH, Cox PN: Lactic acidemia and bradyarrhythmia in a child sedated with propofol. *Crit Care Med* 1998; 26:2087-92
6. Hanna JP, Ramundo ML: Rhabdomyolysis and hypoxia associated with prolonged propofol infusion in children. *Neurology* 1998; 50:301-3
7. Markovitz BP: Rare events often happen infrequently: Propofol complications revisited. *Crit Care Med* 2000; 28:1367-8
8. Strickland RA, Murray MJ: Fatal metabolic acidosis in a pediatric patient receiving an infusion of propofol in the intensive care unit: Is there a relationship? *Crit Care Med* 1995; 23:405-9
9. Susla G: Propofol toxicity in critically ill pediatric patients: show us the proof (editorial). *Crit Care Med* 1998; 26:1959-60
10. Cornfield DN, Tegtmeyer K, Nelson MD, Milla CE, Sweeney M: Continuous propofol infusion in 142 critically ill children. *Pediatrics* 2002; 110:1177-81
11. Vasile B, Rasulo F, Candiani A, Latronico N: The pathophysiology of propofol infusion syndrome: A simple name for a complex syndrome. *Intensive Care Med* 2003; 29:1417-25
12. Marinella MA: Lactic acidosis associated with propofol (communication to the editor). *Chest* 1996; 109:292
13. Perrier ND, Baerga-Varela Y, Murray MJ: Death related to propofol use in an adult patient. *Crit Care Med* 2000; 28:3071-4
14. Cannon ML, Glazier SS, Bauman LA: Metabolic acidosis, rhabdomyolysis and cardiovascular collapse after prolonged propofol infusion. *J Neurosurg* 2001; 95:1053-6
15. Badr AE, Mychaskiw IIG, Eichhorn JH: Metabolic acidosis associated with a new formulation of propofol. *ANESTHESIOLOGY* 2001; 94:536-8
16. Wolf A, Weir P, Segar P, Stone J, Shield J: Impaired fatty acid oxidation in propofol infusion syndrome. *Lancet* 2001; 357:606-7

## Spinal Alcohol Neurolysis for Intractable Thoracic Postherpetic Neuralgia after Test Bupivacaine Spinal Analgesia

Gabriela R. Lauretti, M.D., M.Sc., Ph.D.,\* Wilder R. Trevelin, M.D.,† Luis-Cleber P. Frade, M.D.,‡  
Izabel C. P. R. Lima, M.D., Ph.D.‡

PAIN caused by herpes zoster is classified as acute herpetic pain and postherpetic neuralgia (PHN). Acute herpetic pain is inflammatory and nociceptive, whereas PHN is a combination of neuropathic and maintained sympathetic pain, which contributes to ongoing pain.<sup>1</sup> Therefore, the treatment differs. Acute herpetic pain treatment includes antiviral drugs, nerve blocks, sympathetic blockade, and opioids, whereas PHN requires antidepressants, anticonvulsants, antiarrhythmic drugs, corticosteroids, gabapentin, topical capsaicin, topical clonidine, or local anesthetics and beside nerve blocks.<sup>1-6</sup>

Although there are various treatments for PHN, in some patients who are resistant to conventional therapies, intractable or poorly responsive symptoms can develop, which can lead to a devastating impact on a patient's quality of life. For these cases, different approaches such as endoscopic transthoracic sympathetomy,<sup>7</sup> 60 mg intrathecal methylprednisolone,<sup>8</sup> or even the removal of the painful skin<sup>9</sup> have been suggested.

We report six cases of patients with long-standing history of refractory PHN managed with spinal thoracic alcohol neurolysis after the spinal test block (tables 1-3).

### Case Reports

#### Case 1

A 82-yr-old woman weighing 72 kg was evaluated for reports of 2-yr excruciating and burning pain secondary to herpes zoster on the trunk with sequelae on the skin from right T7 to T10 but painful skin at T9-T12 on the same side. The scarred area was hypoesthetic; nevertheless, the patient reported severe allodynia to tactile stimuli and hyperalgesia from T9 to T12 extension area. She also reported paroxysmal lancinating pain occurring at least twice a week.

The symptoms were poorly responsive to the daily combination of 300 mg tramadol, 75 mg amitriptyline, 600 mg gabapentin, 600 mg carbamazepine, 2 g dipyrone, and 200 mg ketoprofen. Either topical

application of clonidine cream or capsaicin alleviated 30% of the burning sensation for nearly 4 h. Topical application of 5 mg/day nitroglycerine did not have any effect. Sequential weekly intercostal blocks from T9 to T12 with 30  $\mu$ g clonidine, 5 mg dexamethasone, and 70 mg lidocaine were also tried simultaneously, with poor response. An epidural catheter was then inserted at the T9-T10 interspace, and the patient was discharged home, taking 90  $\mu$ g epidural clonidine daily combined with 180 mg lidocaine (divided into three applications per day). After 5 weeks, the catheter was removed because of patient dissatisfaction. Higher doses of clonidine resulted in somnolence.

After peripheral vein catheterization and standard monitoring, the patient underwent test thoracic spinal analgesia at the T9-T10 interspace, with 0.2-ml increment doses of 0.5% isobaric bupivacaine. The puncture was done at the lateral position, with the painful pain side facing up, and freedom from pain was obtained with 0.6 ml isobaric bupivacaine, 0.5%. The patient was kept in the lateral position for an additional 30 min and was sent home after eating and drinking.

A week later, the patient returned, enthusiastic and with no reports of side effects or pain. She underwent spinal neurolysis under the same conditions of the spinal test, with the final dose of 0.6 ml alcohol, 100%. The final alcohol volume was 0.6 ml because the previous bupivacaine test dose indicated ideal analgesia from T9 to T12, without side effects. Just after the alcohol injection, the patient reported a transient thoracic burning sensation; however, no medication was necessary because it was short lived—near 3 min. Just before withdrawal of the needle, 0.3 ml normal saline was injected into the needle to avoid any alcohol damage to the muscle or ligaments through the needle way. The patient was discharged home, taking 600 mg gabapentin and 75 mg amitriptyline daily. Thirteen months later, she had no allodynia or hyperalgesia, but she reported local thoracic hypoesthesia and pruritus (visual analog scale [VAS] score, 3 cm). There were no motor deficits, and the VAS score for residual steady burning pain was 2 cm.

#### Case 2

The patient reported pain from T6 to T12 dermatomes and underwent test thoracic spinal analgesia at the T9-T10 interspace with 0.2-ml increment doses of 0.5% isobaric bupivacaine, while in the lateral position, with the painful pain side facing up. Freedom from pain was obtained with 0.8 ml isobaric bupivacaine, 0.5%. The patient was kept in the lateral position for an additional 30 min. Evaluation 1 h later revealed dermatome anesthesia varying from T4 to L1 dermatomes.

A week later, the patient returned, with no side effects or pain; however, we decided to use the final dose of 0.4 ml alcohol, 100%, for the spinal neurolysis as the skin area of anesthesia after the bupivacaine spinal test block ranged from T4 to L1, and was unnecessary for this patient (who had neuropathic pain from T6 to T12). A volume of 0.3 ml normal saline was injected into the needle before withdrawal. The patient was discharged home, taking 2.5 mg methadone daily combined with 5 mg meloxicam, 150 mg ranitidine, and 50 mg amitriptyline. A week later, he was free from pain from T6 to T9; however, acute herpes zoster had developed at the T11 and T12 dermatomes. Daily oral acyclovir was initiated and continued for 15 days, with good response. Two months later, the patient reported pain at T11-T12, left side, with a VAS score of 10 cm, and he underwent intercostal neu-

\* Associate Professor of Anesthesiology, † Postgraduate Student in Anesthesiology, ‡ Physician Assistant in Pain, Faculty of Medicine of Ribeirão Preto, University of São Paulo.

Received from the Hospital das Clínicas, Department of Biomechanics, Medicine and Rehabilitation of Members of the Faculty of Medicine of Ribeirão Preto, University of São Paulo, São Paulo, Brazil. Submitted for publication November 18, 2003. Accepted for publication February 11, 2004. Support was provided solely from institutional and/or departmental sources.

Address correspondence to Dr. Lauretti: Rua-Campos Sales, 330, apto. 44, Ribeirão Preto, São Paulo, Brazil, 14015-110. Address electronic mail to: gllauretti@fmrp.usp.br. Reprints will not be available from the authors. Individual article reprints may be purchased through the Journal Web site, www.anesthesiology.org.



**Table 1. Demographic Data**

Patient No.	Age, yr	Weight, kg	Sex	Color of Skin	Duration of PHN	Dermatome Thoracic Scar Extension	Dermatome Thoracic Pain Extension	Side of Thoracic Pain
1	82	72	F	Black	2 yr	T7–T10	T9–T12	Right
2	72	62	M	White	5 yr	T6–T12	T6–T12	Left
3	65	76	M	White	2 yr	T6–T8	T5–T8	Left
4	75	68	M	White	8 months	T3–T4	T2–T5	Left
5	66	76	M	White	3 yr	T6–T7	T5–T8	Left
6	67	52	M	White	4 months	T3–T4	T3–T4	Left

PHN = postherpetic neuralgia.

rolysis at the 11th and 12th thoracic levels with 0.5 ml phenol, 7.5%. After 11 months, he reported residual pain with a VAS score of 1 cm and had no sign of motor deficits.

### Case 3

Postherpetic neuralgia varied from the T5 to T8 dermatomes. The patient's history included hypertension, angina, and acute myocardial infarction. He underwent test thoracic spinal analgesia at the T5–T6 interspace with 0.1-ml increment doses of 0.5% isobaric bupivacaine. Freedom from pain was obtained with 0.3 ml isobaric bupivacaine, 0.5%. The patient was kept in the lateral position for an additional 30 min. After evaluation at 6 h, he had no signs of chest pain or bradycardia. A week later, he returned, with no reports of side effects, motor deficits, or pain, and underwent spinal neurolysis with 0.3 ml alcohol, 100%. He was discharged home, taking 2.5 mg methadone daily combined with 5 mg meloxicam, 100 mg ranitidine, and 12.5 mg amitriptyline. After 10 months, the patient was completely free of pain.

### Case 4

Postherpetic neuralgia varied from the T2 to T5 dermatomes. The patient underwent test thoracic spinal analgesia at the T3–T4 interspace with 0.1-ml increment doses of 0.5% isobaric bupivacaine. Freedom from pain was obtained with 0.3 ml isobaric bupivacaine, 0.5%. The patient was kept in the lateral position for an additional 30 min. A week later, he reported that 24 h after the test block, the burning pain restarted (VAS score, 5 cm). He underwent spinal neurolysis with 0.3 ml alcohol, 100%. Currently, the patient has no complaints of shooting pain and is undergoing weekly stellate ganglion block combined with 400 mg carbamazepine daily plus 50 mg amitriptyline. He classifies the remaining burning pain as 4 cm on the VAS scale.

### Case 5

Postherpetic neuralgia varied from the T5 to T8 dermatomes. The patient had a history of hypertension and angina. He underwent test

thoracic spinal analgesia at the T6–T7 interspace with 0.1-ml increment doses of 0.5% isobaric bupivacaine. Freedom from pain was obtained with 0.3 ml isobaric bupivacaine, 0.5%. The patient was kept in the lateral position for an additional 30 min. A week later, he returned, with no reports of side effects, motor deficits, or pain, and he underwent spinal neurolysis with 0.3 ml alcohol, 100%. He was discharged home, taking 50 mg amitriptyline. After 9 months, he is completely free of pain.

### Case 6

Postherpetic neuralgia varied from the T3 to T4 dermatomes. At the time the patient underwent test thoracic spinal analgesia at the T3–T4 interspace with 0.1-ml increment doses of 0.5% isobaric bupivacaine, he was confused about the intensity of the pain. The total dose of 0.2 ml isobaric bupivacaine, 0.5%, was injected at the time. The patient was kept in the lateral position for an additional 30 min. A week later, he returned, reporting pain with a VAS score of 8 cm, and did not undergo spinal neurolysis because of the poor response to the test block. After 4 months, he is still experiencing pain with a VAS score of 8 cm. He is currently under a sequential epidural blockade, taking oral amitriptyline, clonidine, and corticosteroids, and is poorly responsive.

## Discussion

Postherpetic neuralgia is a difficult condition to treat, and effective management requires a multimodal approach, including pharmacologic and nonpharmacologic treatments.<sup>10</sup> Nevertheless, of the various treatments, none produce definitive effects, and unfortunately, patients can be resistant to conventional therapies, perhaps because of the new pattern of coetaneous innervations in the skin affected with PHN.<sup>11</sup> Immunofluorescence of the most painful area revealed a reduction in density of innervation of the epidermis, in the dermal–epidermal junction, and in the eccrine sweat glands of the compro-

**Table 2. Pain Characteristics before 0.5% Isobaric Bupivacaine Test Block–100% Alcohol Neurolysis**

Patient No.	Characteristic of Pain	Scar Sensation	Other Local Sensations	Paroxysmal Lancinating Pain
1	Severe, steady burning (VAS 10 cm)	Hypoesthetic burning	Allodynia, hyperalgesia	At least twice a week (VAS 10 cm)
2	Burning and shooting (VAS 10 cm)	Hypoesthetic	Allodynia, hyperesthesia	Absent
3	Steady burning (VAS 10 cm)	Hypoesthetic burning	Allodynia, hyperalgesia	Absent
4	Burning and shooting (VAS 9 cm)	Hypoesthetic	Allodynia, hyperesthesia, hyperalgesia	Daily
5	Steady burning (VAS 10 cm)	Anesthesia	Hyperesthesia	Absent
6	Burning (VAS 7 cm)	Hypoesthesia	Allodynia hyperalgesia	Absent

VAS = visual analog pain scale (0–10 cm).

**Table 3. Pain Characteristics after 0.5% Isobaric Bupivacaine Test Block–100% Alcohol Neurolysis**

Patient No.	Alcohol, ml	Sensory Changes	Other Local Sensations	Paroxysmal Lancinating Pain	Remaining Pain	Other Considerations
1	0.6	Absence of allodynia or hyperalgesia	Hypoesthesia pruritus (VAS 3 cm)	Absent	Steady burning (VAS 2 cm)	No side effects
2	0.4	Absence of allodynia or hyperalgesia from T6 to T9	Anesthesia from T6 to T9; hypoesthesia at T10	Absent	Allodynia and hyperalgesia from T11 to T12 (VAS 7 cm)	T11–T12 intercostal neurolysis, pain (VAS 1 cm)
3	0.3	Absence of allodynia or hyperalgesia	Anesthesia	Absent	Anesthesia (VAS 0 cm)	No side effects
4	0.3	Burning (VAS 5 cm) after test block	Hyperesthesia, hyperalgesia	Absent	No shooting, burning pain (VAS 4 cm)	Weekly stellate ganglion block
5	0.3	Absence of hyperesthesia	—	Absent	Anesthesia (VAS 0 cm)	No side effects
6	None	No changes after test block	Allodynia hyperalgesia	Absent	Steady burning (VAS 8 cm)	Failed response to test block

VAS = visual analog pain scale (0–10 cm).

mised skin.<sup>11</sup> It has been suggested that a minimum of 650 neurites/mm<sup>2</sup> skin surface area is necessary to avoid PHN.<sup>12</sup> Destruction of the primary nociceptive neurons can reduce more than four times the skin density primary neurons,<sup>11</sup> and the intrathecal measurement of interleukin 8 could be indicative of the duration of neuralgia.<sup>8</sup>

We describe six patients with PHN, of whom five (cases 1–5) were successfully treated with correspondent thoracic spinal neurolysis of the affected skin, with individually incremented low doses of 100% alcohol. Subarachnoid neurolysis using ethanol to selectively destroy the posterior roots of the spinal cord has been described as a method for providing pain relief.<sup>3,4</sup> Apart from the selective destruction of dorsal roots, even at nontoxic concentrations, ethanol has a direct effect on insular free Ca<sup>2+</sup> smooth muscle, associated with vasoconstriction;<sup>13</sup> however, none of our patients showed any signs of motor injury.

In fact, the criteria for intrathecal neurolysis in our practice include (1) midthoracic neuralgia not responsive to conventional therapies and (2) previous intrathecal test block with isobaric bupivacaine (similar baricity compared with the alcohol solution) to direct to a more appropriate volume of alcohol to be used and possible side effects. In the presence of respiratory difficulty, cardiac arrhythmia, urinary or bowel incontinence, or absence of response, neurolysis is contraindicated, as in the patient in case 6, where the spinal test block had no benefit, suggesting that different ways to treat the pain should be attempted.

Complications after subarachnoid neurolysis with hyperbaric phenol reported in the literature include unexpected contralateral brachial weakness, which developed toward the conclusion of the procedure and fortunately resolved spontaneously.<sup>14</sup> Of importance, the site of administration for the neurolytic agent in our patients is always the midthoracic level (between the 5th

and the 10th thoracic levels), responsible mainly for the motor activity of the intercostal muscles. Weakness or irreversible cord injury of the extremities is a complication of the procedure that has been attributed to spread of the neurolytic agent to the anterior roots.<sup>15</sup> Even in the presence of rostral spread and intercostal muscle paralysis, the diaphragm muscle that is innervated spinally at the 3rd to the 5th cervical level would maintain by itself appropriate respiratory function in most patients.

In addition to spinal neurolysis, acute herpes zoster developed in the second patient, in the two consecutive lower thoracic levels (T11 and T12). The varicella zoster virus remains dormant in dorsal root and can be reactivated by declining specific cellular immunity leading to herpes zoster, and patients aged older than 50 yr are at increased risk to develop such a complication.<sup>16</sup> In this specific case, intercostal neurolysis was successfully performed at the 11th and 12th thoracic levels with 0.5 ml phenol, 7.5%, after the antiviral treatment. It has been suggested that the antiviral agent acyclovir combined with epidural blocks is an effective treatment for pain.<sup>17</sup> A higher volume of phenol has been associated with irreversible complications. Immediate paraplegia has been described after intercostal neurolysis with 6 ml aqueous phenol solution, 7.5%, at the 10th thoracic level. A lumbar puncture performed 3.5 h after the intercostal block showed a phenol concentration of 87.5 mg/ml. The authors suggested that the most likely explanation was the diffusion of the phenol through the intervertebral foramina, reaching the spinal space and therefore damaging the motor and sensory roots.<sup>18</sup> A different alternative to the intrathecal route includes epidural assessment. After death secondary to the primary disease, necropsy of the spinal cord and roots demonstrated no abnormality, and only the laminar structure of the dura had been destroyed at the outer



one third.<sup>19</sup> Patient 4 had sympathetically maintained pain, and was successfully treated with additional stellate ganglion block.<sup>20</sup>

In conclusion, we have described an easier alternative to treat unresponsive PHN, with no side effects. The importance of the technique lies in the previous test with a substance similar in baricity to alcohol (isobaric bupivacaine), guiding the proper indication, and in a more specific volume of 100% alcohol administered to avoid sequelae or side effects.

## References

1. Hashizume K: Herpes zoster and post-herpetic neuralgia. *Nippon Rinsho* 2001; 59:1738-42
2. Hirata K, Higa K: Pain treatment of herpes zoster. *Nippon Rinsho* 2000; 58:951-6
3. Bajwa ZH, Ho CC: Herpetic neuralgia: Use of combination therapy for pain relief in acute and chronic herpes zoster. *Geriatrics* 2001; 56:18-24
4. Wu CL, Marsh A, Dworkin RH: The role of sympathetic nerve blocks in herpes zoster and post herpetic neuralgia. *Pain* 2000; 87:121-9
5. Backonja M, Glanzman RL: Gabapentin dosing for neuropathic pain: Evidence from randomized, placebo-controlled trials. *Clin Ther* 2003; 25:81-104
6. Scheinfeld N: The role of gabapentin in treating diseases with cutaneous manifestations and pain. *Int J Dermatol* 2003; 42:491-5
7. Matsumoto I, Oda M, Shintani H: Use of endoscopic transthoracic sympathectomy in intractable postherpetic neuralgia of the chest. *Chest* 2002; 122: 715-7
8. Kotani N, Kushikata T, Hashimoto H, Kimura F, Muraoka M, Yodono M, Asai M, Matsuki A: Intrathecal methylprednisolone for intractable postherpetic neuralgia. *N Engl J Med* 2000; 343:1514-9
9. Petersen KL, Rice FL, Suess F, Berro M, Rowbotham MC: Relief of post-herpetic neuralgia by surgical removal of painful skin. *Pain* 2002; 98:119-26
10. Johnson L: Effective pain management of post-herpetic neuralgia. *Nurs Times* 2003; 99:32-4
11. Rowbotham MC, Yosipovitch G, Connolly MK, Finlay D, Forde G, Fields HL: Cutaneous innervation density in the allodynic form of postherpetic neuralgia. *Neurobiol Dis* 1996; 3:205-14
12. Oaklander AL: The density of remaining nerve endings in human skin with and without postherpetic neuralgia after shingles. *Pain* 2001; 92:139-45
13. Johnson ME, Sill JC, Brown DL, Halsey TJ, Uhl CB: The effect of the neurolytic agent ethanol on cytoplasmic calcium arterial smooth muscle and endothelium. *Reg Anesth* 1996; 21:6-13
14. Garcia E, Patt RB, Ginsberg LE: Effective but near disastrous subarachnoid neurolysis for mechanical root pain in a paraplegic cancer patient. *Clin J Pain* 1996; 12:243-9
15. McGarvey ML, Ferrante FM, Patel RS, Maljian JA, Stecker M: Irreversible spinal cord injury as a complication of subarachnoid ethanol neurolysis. *Neurology* 2000; 54:1522-4
16. Gross G, Schofer H, Wasslew S, Friese K, Timm A, Guthoff R, Pau HW, Malin JP, Wutzler P, Doerr HW: Herpes zoster guideline of the German Dermatology Society (DDG). *J Clin Virol* 2003; 26:277-89
17. Hwang SM, Kang YC, Lee YB, Yoon KB, Ahn SK, Choi EH: The effects of epidural blockade on the acute pain in herpes zoster. *Arch Dermatol* 1999; 135:1359-64
18. Kowalewski R, Schurch B, Hodler J, Borgeat A: Persistent paraplegia after an aqueous 7.5% phenol solution to the anterior motor root for intercostals neurolysis: A case report. *Arch Phys Med Rehabil* 2002; 83:283-5
19. Hayashi I, Odashiro M, Sasaki Y: Two cases of epidural neurolysis using ethyl alcohol and histopathologic changes in the spinal cord. *Masui* 2000; 49: 877-80
20. Maier C, Gleim M: Diagnostic and treatment measures in patients with sympathetically maintained pain. *Schmerz* 1998; 12:282-303

Anesthesiology 2004; 101:247-58

© 2004 American Society of Anesthesiologists, Inc. Lippincott Williams & Wilkins, Inc.

## Methemoglobinemia from Hydrogen Peroxide in a Patient with Acatalasemia

Yoshikazu Hamada, M.D.,\* Yoshiyuki Kameyama, M.D.,\* Toru Iizuka, M.D.,† Taku Ishizaki, M.D.,† Takahisa Nishiyama, M.D.,† Atsushi Isshiki, M.D.‡

**ACATALASEMIA** is an autosomal recessive constitutional disorder caused by the absence of catalase activity. It was discovered by Takahara<sup>1</sup> in 1946. *Catalase* is an enzyme that catalyzes the conversion of hydrogen peroxide to water and oxygen. In acatalasemia, the catalase is absent in the mucosa, skin, muscle, sternal marrow, appendix, and liver tissue.<sup>2</sup> We describe our experience with a case of acatalasemia associated with methemoglobinemia that was caused by hydrogen peroxide solution during anesthesia.

### Case Report

The patient was a 71-yr-old man who had been given a diagnosis of laryngeal cancer and was scheduled to undergo complete laryngectomy.

\* Assistant Professor, † Instructor, ‡ Professor and Chairman.

Received from the Department of Anesthesiology, Tokyo Medical University, Shinjuku-ku, Tokyo, Japan. Submitted for publication September 17, 2003. Accepted for publication February 23, 2004. Support was provided solely from institutional and/or departmental sources. Presented at the 43rd Annual Meeting of the Japan Society of Anesthesiologists, Okayama, Japan, March 29, 1996.

Address correspondence to Dr. Hamada: Department of Anesthesiology, Tokyo Medical University, 6-7-1 Nishishinjuku, Shinjuku-ku, Tokyo 160-0023, Japan. Address electronic mail to: yhamada@tokyo-med.ac.jp. Individual article reprints may be purchased through the Journal Web site, [www.anesthesiology.org](http://www.anesthesiology.org).

tomy with neck dissection. His family history was not relevant to the current disorder.

General anesthesia was induced with thiopental and vecuronium and maintained with 50% oxygen, 50% nitrous oxide, and 1-2% isoflurane. During induction of anesthesia, the percutaneous oxygen saturation (SpO<sub>2</sub>) was 100%, and hemodynamic variables were stable. The oral cavity and larynx were disinfected with 300 ml of a 1:2 dilution of 3% hydrogen peroxide; the neck was disinfected with 7% povidone iodine. Approximately 10 min after starting the operation (approximately 20 min after disinfection), the SpO<sub>2</sub> rapidly decreased to 80%, and the blood in the surgical field turned blackish brown. Arterial blood gas measurement and hemoglobin analysis revealed dissociation between the partial pressure of arterial oxygen (PaO<sub>2</sub>, 235 mmHg) and the arterial oxygen saturation (SaO<sub>2</sub>, 87.5%, actually measured value). The methemoglobin concentration was 11%, and methemoglobinemia was diagnosed, although its cause was unclear. The patient was intravenously given 2,000 mg ascorbic acid, and surgery was resumed. While the patient was breathing 100% oxygen, the SaO<sub>2</sub> increased to 89.7% and the PaO<sub>2</sub> increased to 435 mmHg; the methemoglobin concentration decreased to 7.5%.

However, on removing the surgical drape from the face, an extensive area of edema, vacuoles, and erosions was found on the cheeks, lips, oral cavity, and pharyngeal mucosa. Awakening was normal. The methemoglobin concentration on postoperative day 3 was normal (0.5%).

When hydrogen peroxide was applied to a sample of the patient's blood, bubbling was weaker than that with the blood of a healthy subject, and the blood sample turned dark brown. When the patient's

forearm was scratched and hydrogen peroxide was applied, vacuoles developed after 15 min. These results led to a differential diagnosis of (1) absence of reduced nicotinamide adenine dinucleotide methemoglobin-converting enzyme; (2) absence of glyceraldehyde-3-phosphate dehydrogenase, glucose-6-phosphate dehydrogenase, or pyruvate oxidase; (3) absence of glutathione reductase or glutathione peroxidase; or (4) abnormal catalase activity.<sup>3</sup> Erythrocyte catalase activity measured by the method described by Beutler<sup>4</sup> was markedly decreased (28 U/g hemoglobin; normal range, 129,000–177,000 units/g hemoglobin). The diagnosis was acatalasemia.

## Discussion

Because acatalasemia is an autosomal recessive disorder, pedigree analysis was performed with the cooperation of the patient's family. The patient's parents were half cousins. His mother had hypocatalasemia with approximately half of the catalase activity of a normal person. The patient's father had already died but was assumed to have had acatalasemia or hypocatalasemia. The patient's spouse was normal, but all three of their children had hypocatalasemia. The underlying genetic abnormality was found to be Japanese type on gene analysis.<sup>5</sup> There are approximately 50 known unrelated Japanese-type acatalasemia families, characterized by the near total loss of catalase activity because of a splicing mutation.

Catalase serves to protect the cells from the toxic effects of hydrogen peroxide by catalyzing its decomposition into molecular oxygen and water.<sup>6</sup> In acatalasemia patients, hydrogen peroxide does not decompose, and it acts as an oxidant of hemoglobin, resulting in methemoglobinemia. In healthy patients, hydrogen peroxide causes the formation of oxygen bubbles, without any change in blood color. An important feature of our case was that a blood sample turned blackish brown or chocolate colored on the addition of hydrogen peroxide, without the formation of oxygen bubbles. Approximately half of all patients with acatalasemia have pro-

gressive gangrenous stomatitis during childhood, whereas the other half are asymptomatic, as in the current case. Progressive gangrenous stomatitis develops because of inability to process hydrogen peroxide produced by oral flora. In the current case, the hydrogen peroxide used to wash the oral cavity disturbed mucosal cells and penetrated to the capillaries, where it converted hemoglobin to methemoglobin. The increase in methemoglobin resulted in localized oxygen deficiency, causing the formation of edema and ulcers in the oral cavity and pharynx.<sup>1</sup> Methemoglobinemia is diagnosed when the methemoglobin concentration increases to the equivalent of at least 1% of the total hemoglobin concentration such as in acatalasemia patients. Our case was classified as acquired methemoglobinemia. Early diagnosis was facilitated by discoloration of blood, measurement of percutaneous oxygen saturation, and analysis of hemoglobin.<sup>7</sup> Methylene blue is the first-line antidote for methemoglobinemia, provided there is no glucose-6-phosphate dehydrogenase deficiency. We used ascorbic acid as an antioxidant of methemoglobin because the cause was unclear during surgery.

The possibility of acatalasemia should be borne in mind by physicians who use oxidizing agents such as hydrogen peroxide at the time of anesthesia.

## References

1. Takahara S: Acatalasemia in Japan. *Saishin Igaku* 1969; 24:1251–8
2. Ogata M: Acatalasemia. *Hum Genet* 1991; 86:331–40
3. Tanishima K: Hereditary methemoglobinemia. *Tanpakushitsu Kakusan Koso* 1987; 32:870–6
4. Beutler E: Red cell metabolism: A manual of biochemical methods, 3rd edition. Orlando, Grune & Stratton, 1984, pp105–6
5. Kishimoto Y, Murakami Y, Hayashi K, Takahara S, Sugimura T, Sekiya T: Detection of a common mutation of the catalase gene in Japanese acatalasemic patients. *Hum Genet* 1992; 88:487–90
6. Paniker NV, Iyer GYN: Erythrocyte catalase and detoxication of hydrogen peroxide. *Can J Biochem* 1965; 43:1029–39
7. Groeper K, Katcher K, Tobias JD: Anesthetic management of a patient with methemoglobinemia. *South Med J* 2003; 96:504–9