

Influence of Sensory and Proprioceptive Impairment on the Development of Phantom Limb Syndrome during Regional Anesthesia

Xavier Paqueron, M.D.,* Morgan Leguen, M.D.,† Marc E. Gentili, M.D.,‡ Bruno Riou, M.D., Ph.D.,§ Pierre Coriat, M.D.,|| Jean Claude Willer, M.D., Ph.D.#

Background: The relation between impairment of sensorimotor function and occurrence of phantom limb syndrome (PLS) during regional anesthesia has not been described. This study assessed the temporal relation between PLS and the progression of sensorimotor impairment during placement of a brachial plexus nerve block.

Methods: Fifty-two patients had their arm randomly placed either alongside their body (group A) or in 90° abduction (group B) immediately after brachial plexus nerve block placement. Responses to pin prick, cold, heat, touch, proprioception, and voluntary movement were assessed every 5 min for 60 min. Meanwhile, patients described their perceptions of the size, shape, and position of their anesthetized limb.

Results: Phantom limb syndrome occurred 19 ± 9 min after nerve block placement. Proprioception was impaired and abolished after 22 ± 9 and 43 ± 17 min, respectively ($P < 0.05$ vs. PLS onset). When PLS occurred, responses to pin prick, cold, heat, and proprioception were abolished in 96, 94, 87, and 4% of patients, respectively. Patients were more likely to feel their anesthetized limb in adduction and in abduction in groups A and B ($P < 0.05$ vs. group A), respectively. After PLS had become motionless, two stereotyped positions were identified: arm adduction, elbow flexion, hand over the abdomen (68% of group A patients) and arm abduction, elbow flexion, hand held close to the homolateral ear (48% of group B patients).

Conclusions: This study provides a better understanding of the determinants of PLS by showing that the final position of PLS is related both to the abolition of proprioception and the initial position of the anesthetized limb.

DEVELOPMENT of a perceptual alteration of limb position during regional anesthesia is the major symptom emerging from a series of abnormal sensations occurring during the course of deafferentation induced by local anesthetics.¹ These abnormal sensations have been named, perhaps abusively, *phantom limb sensations* or *phantom limb syndrome*² by analogy with amputees in whom sensations occur in their missing limb. Patients

frequently report perception of position of the anesthetized limb that does not match its real position, and this illusory position moves and changes until the limb becomes motionless. At this point, most patients report the final phantom position of their anesthetized limb in a similar and stereotyped position.

Several previous studies devoted to phantom limb syndrome during regional anesthesia have reported that the former is related to the functional alteration of large-diameter sensory fibers and to the disappearance of sensorimotor afferences to the central nervous system (and particularly proprioception) while a central cerebral activity persists.^{2,3} Indeed, several observations suggest that impairment of proprioceptive information could participate in the genesis of the phantom limb syndrome induced by regional anesthesia. First, the position in which the phantom limb is felt has frequently been shown to be close to the position of the actual limb before anesthesia.⁴ Second, a relation between phantom limb syndrome and alteration of proprioception during spinal anesthesia has been suggested.⁵ However, no systematic study has been conducted to assess the impairment of the different sensorimotor functions and the occurrence of phantom limb syndrome during the installation of an anesthetic peripheral nerve block. Further, local anesthetic-induced deafferentation induces a whole set of illusory perceptions, such as perceptual distortion of size and shape,¹ which have not been described and paralleled with description of phantom limb syndrome and of sensorimotor impairment.

The first aim of this study was to analyze the relation between the occurrence of phantom limb syndrome and the alteration of the different sensations during the installation of an anesthetic block, particularly focusing on the alteration of proprioception and small-diameter sensory fibers. Based on our previous study, it seems that the abnormal sensations induced by regional anesthesia are mainly correlated with a decrease in A δ - and C-fiber activity.¹ Regional anesthesia also provides a unique model of progressive and reversible transient deafferentation, sharing many striking similarities with phantom limb syndromes of amputees. The second aim of this study was to take advantage of the fact that transient deafferentation induced by local anesthetics is ideal for studying peripheral phenomenology of deafferentation because it is a unique progressive model of transient and selective blockade of peripheral fibers, in contrast with amputees in whom interactions occur between periph-

* Assistant Professor, † Resident in Anesthesiology, || Professor of Anesthesiology, Chairman, Department of Anesthesiology, § Professor of Anesthesiology, Chairman, Department of Emergency Medicine and Surgery, # Professor of Neurology, Chairman, Department of Clinical Neurophysiology, Centre Hospitalier Universitaire Pitié-Salpêtrière. ‡ Staff Anesthesiologist, Department of Anesthesiology, Centre Médico-Chirurgical Saint Vincent.

Received from the Department of Anesthesiology, Department of Emergency Medicine and Surgery, Department of Clinical Neurophysiology, Centre Hospitalier Universitaire Pitié-Salpêtrière, Assistance Publique Hôpitaux de Paris, Université Pierre et Marie Curie, Paris, France, and the Department of Anesthesiology, CMC Saint Vincent, Saint Grégoire, France. Submitted for publication September 15, 2003. Accepted for publication November 23, 2003. Support was provided solely from departmental sources.

Address correspondence to Dr. Paqueron: Département d'Anesthésie-Réanimation, Centre Hospitalier Universitaire Pitié-Salpêtrière, 47 Boulevard de l'Hôpital, 75651 Paris Cedex 13, France. Address electronic mail to: xavier.paqueron@psl.ap-hop-paris.fr. Individual article reprints may be purchased through the Journal Web site, www.anesthesiology.org.

eral phenomenon, neuromas, stump pain, alteration of spinal cord processing, and central reorganization. Therefore, we assessed in patients undergoing peripheral regional anesthesia the temporal relation between sensory and motor function impairment and the occurrence of illusions of size and position usually reported. Multimodal sensory testing and assessment of motor function were performed at regular intervals after injection of a local anesthetic, and the temporal relation between the reporting of abnormal sensations of size (swelling sensation) and position (phantom limb sensation) by the patients and the progression of sensory and motor impairment were analyzed.

Materials and Methods

Patients gave informed consent according to the principles of the Helsinki convention. This study was approved by the local institutional review board (Comité Consultatif pour la Protection des Personnes dans la Recherche Biomédicale, Pitié-Salpêtrière, Paris, France). Fifty-two patients (34 men, 18 women, aged 21–92 yr, with a median age of 53 yr) undergoing orthopedic surgery under regional anesthesia (*i.e.*, brachial plexus peripheral nerve block) were enrolled in the study. Exclusion criteria were the existence of neurologic disease, diabetes mellitus, cutaneous infection at the site of needle puncture, or a level of pain above 30 on a visual analog scale ranging from 0 (no pain) to 100 (maximal imaginable pain). No patient received any sedative or anxiolytic drug before or during the study period.

Peripheral Nerve Blocks

All patients were anesthetized using the same infraclavicular brachial plexus nerve block technique.⁶ All blocks were guided by a nerve stimulator and performed with the arm placed alongside the body, the forearm and hand lying on the abdomen. The needle puncture site was located in the infraclavicular fossa. After cutaneous landmarks had been marked on the skin and the skin had been disinfected, a 100-mm insulated needle connected to a nerve stimulator was used to identify one of the following nerves of the brachial plexus according to the specific motor-evoked response: radial, median, or ulnar nerves. An amount of 30 ml ropivacaine, 0.75%, was administered as a single injection after a specific motor-evoked response had been obtained at a stimulating intensity of 0.5 mA or less.

Assessment of Sensory and Motor Functions

Immediately after the block was performed, the anesthetized limb was hidden from the patient's sight. Half of the patients had their anesthetized arm randomly placed alongside their body (position A), whereas in the other half, patients had their arm placed in 90° abduction

(position B). The sensations elicited by pin prick, cold (compress soaked with alcohol at 16°C), heat (glass test tube containing water at 42°C), and gentle rubbing stimuli; the accuracy of position sense (perception of the mobilization of a joint within the deafferented area); and the strength of voluntary movement were assessed immediately after the end of block placement and then every 5 min for 60 min in the territory of the last nerve blocked. Sensory and motor impairment were also assessed in all other territories of the anesthetized limb 15, 30, and 45 min after the end of block placement to evaluate the overall quality of the block before the beginning of surgery. Sensory and motor functions were assessed on a three-point scale, with 2 corresponding to a normal sensation or movement, 1 corresponding to a blunted sensation or moderately impaired movement, and 0 corresponding to an absence of sensation or movement.

Proprioception was assessed in two ways: first, by moving a limb segment from its original position and by asking the patient to show its new position by using the opposite joint.¹ Second, positions A and B were reversed in all patients when their phantom limb had become motionless, and 5 min later, patients were asked to show with their contralateral unanesthetized limb how they perceived the position of their anesthetized limb.

Assessment of the Phantom Limb Syndrome and Associated Body Image Distortions

Just after the end of block placement, patients were told that they might experience various alterations in the perception of size, shape, and position of their anesthetized limb. Then, every 5 min, patients were encouraged to report their sensations. The investigator systematically asked the patient to focus on his or her perception of the shape and position (the term *phantom limb syndrome* defined solely the occurrence of a postural illusion) of the specific anesthetized body part. The patient's subjective report was fully transcribed. The perceptual alterations of shape and position of the limb described by the patient were drawn on a schematic body template to best represent his or her sensations. Movements of the phantom limb were also recorded and depicted until the limb became motionless. At this point, patients were shown their hidden anesthetized limb to assess the phenomenon of fusion and recurrence of the phantom sensation after it had been hidden again. In addition, the affective impression of these body image distortions was assessed by observing spontaneous emotional expressions and by asking the patients whether the perceptual changes were experienced as unpleasant, worrisome, distressing, indifferent, pleasant, or amusing.

Statistical Analysis

Data were expressed as mean \pm SD. Comparison of two means was performed using the Student *t* test, and

comparison of two percentages was performed by using the chi-square test (correct perception of the upper arm position). Comparison between two variables was performed using the least-squares method. All *P* values were two-sided, and a *P* value of less than 0.05 was considered significant. Analyses were performed using NCSS 6.0 software (Statistical Solutions Ltd., Cork, Ireland).

Results

Incidence of Perceptual Distortions of Position and Size and Shape of the Deafferented Areas

Perceptual distortions of position of body parts of the deafferented limb occurred in all but 2 patients (50 of 52; 96%). The average onset times of the perceptual illusion of shape or size and of phantom limb syndrome were 8 ± 4 and 19 ± 9 min after the end of nerve block placement, respectively. The individual analysis revealed that in every patient, the development of a phantom limb syndrome followed the perceptual illusion of alteration of shape or size. The mean interval between the onset of these two sensations was 11 ± 9 min (fig. 1).

Relation between Phantom Limb Syndrome and Sensorimotor Impairment

The time course of sensory and motor impairment is shown in figure 2. Responses to pin prick, cold, and heat were altered (score of 1) first, whereas the sensation of touch and then eventually of position sense later became impaired. Abolition (score of 0) of the different sensations followed the same order. Proprioception, when measured by mobilizing a joint within the anesthetized area, was impaired and abolished 22 ± 9 min ($P < 0.05$ vs. onset time of phantom limb syndrome) and 43 ± 17 min, respectively, after the end of block placement ($P < 0.05$ vs. onset time of phantom limb syndrome).

The occurrence of phantom limb syndrome did not coincide either with the impairment of proprioception, measured by the perception of the mobilization of a joint within the deafferented area, or its abolition, because the perceptual alteration of the limb's position occurred in a majority of patients (54%) in whom the perception of the mobilization of a joint within the deafferented area remained normal ($P < 0.05$ vs. impaired sensations), compared with those in whom it was either altered (42%) or abolished (4%). Conversely, at the time of occurrence of a phantom limb syndrome, sensations elicited by pin prick, cold, and heat were abolished in 50 patients (96%), 49 patients (94%), and 45 patients (87%), respectively (fig. 2B). However, no correlation was found between time of onset of phantom limb syndrome and impairment of sensations for pin prick, cold, and heat, whereas a weak but significant correlation existed between both the impairment ($r = 0.44$, $P < 0.05$) and the abolition ($r = 0.32$, $P < 0.05$) of proprioception

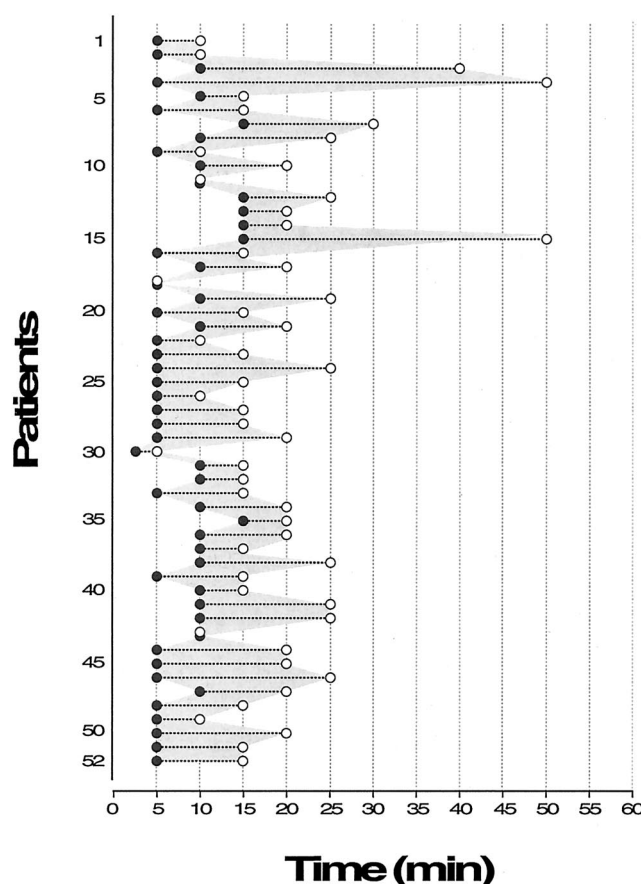


Fig. 1. Temporal relation between the occurrence of the perceptual illusion of size (filled circles) and the occurrence of the postural illusion or phantom limb sensation (open circles). This graph depicts individual data on the 52 patients enrolled in the study. The assessment of these sensations was performed every 5 min over a 60-min period. Note that the illusion of size and shape (i.e., swelling) preceded the occurrence of the perceptual distortion of position or phantom limb sensation in all the patients, with the exception of three patients (Nos. 11, 18, and 43) in whom both sensations occurred at the same time.

measured by mobilizing a joint within the anesthetized area and the occurrence of phantom limb syndrome (fig. 3). Moreover, a significant correlation was also observed between the abolition of the perception of the mobilization of a joint within the deafferented area and the time at which the phantom limb became motionless ($r = 0.64$, $P < 0.05$).

Affective Characteristics of the Perceptual Distortions of the Deafferented Areas

When they occurred, both perceptual distortions of body shape and position were more pronounced in the distal parts of the anesthetized limb. These abnormal perceptions were more vivid in the fingers, hand, and wrist in all patients presenting perceptual distortions, whereas the arm and forearm were usually not abnormally perceived by the patient. Only 2 patients (4%) immediately reported that perceptual distortions of position and shape involved their entire anesthetized limb.

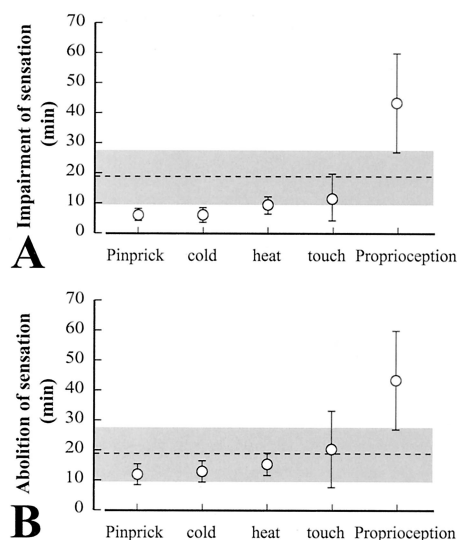


Fig. 2. Time to impairment (A) and to abolition (B) of the sensations elicited by pin prick, cold, heat, gentle rubbing (touch), and mobilization of a joint within the deafferented area (proprioception) and onset of phantom limb syndrome (dashed line). The dashed line and the gray area correspond to the mean delay to phantom limb syndrome and its SD, respectively. When the phantom limb syndrome occurred, the only perceptions abolished were pin prick, cold, and heat. Values are presented as mean \pm SD.

Subsequently, as their upper limb became increasingly anesthetized, patients usually felt the perceptual distortions extend to their forearm and arm. At this time, the perceptual distortion of shape remained more vivid distally, in the fingers, hand, and wrist, whereas the perceptual distortion of position dominated at the level of the forearm, shoulder, arm, and elbow. Furthermore, 32 patients (61%) reported to the investigator a definite feeling that their anesthetized arm had been cut off or amputated, which preceded the occurrence of the perceptual distortion of position.

Different affective reactions of the patients regarding the perceptual distortions of position of size and shape were observed. Eighteen patients (35%) reported that this sensation was indifferent, 9 patients (17%) found it amusing, and 25 patients (48%) found such a sensation unpleasant or uncomfortable. Among these latter patients, the initial sensations were amusement and indifference in 12 and 9 patients, respectively. However, none of the patients reported a painful phantom limb syndrome, even in case of emergency surgery for upper limb trauma.

Perception of a Progressive Spatial Shift of the Position of the Phantom Limb Syndrome

We observed that each initial position (A or B) of the anesthetized limb induced the dominance of one type of misperception of position because patients reported a different initial perception of the position of their deafferented limb if they had been installed in position A

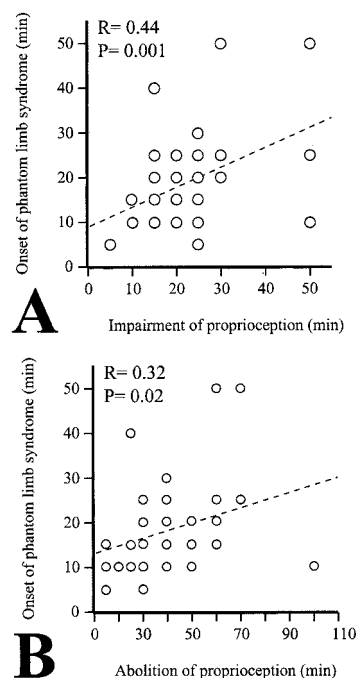


Fig. 3. Correlations between the onset of phantom limb syndrome and the impairment of proprioception (A) or the abolition of proprioception (B). Proprioception was assessed by the perception of the mobilization of a joint within the anesthetized area and was scored on a three-point scale, with 2 corresponding to a normal sensation, 1 corresponding to an impaired sensation, and 0 corresponding to the abolition of sensation.

(anesthetized arm placed alongside the body) or B (anesthetized arm placed in 90° abduction) after the end of the nerve block placement (fig. 4). In the group of patients whose arm was placed in position A ($n = 26$), patients were more likely to feel their anesthetized limb alongside their body or in adduction, as 14, 6, and 6 patients described sensations of neutral position, adduction, and abduction, respectively. Conversely, in the group of patients whose arms were placed in position B ($n = 26$), patients were more likely to perceive their anesthetized limb in abduction, as 8, 1, and 14 patients described their limb in a neutral position, in adduction, and in abduction, respectively ($P < 0.05$ vs. position described by patients placed in position A). In both positions, the majority of patients also described elevation of their anesthetized limb. In position A, 1, 6, and 14 patients reported that they felt their hand, hand and forearm, or entire arm was lifted, respectively. In position B, 3, 9, and 10 patients stated that they felt their hand, hand and forearm, or entire arm was lifted, respectively ($P =$ not significant vs. position described by patients set in position A).

After the onset of phantom limb syndrome, most patients experienced the sensation of a shift in the position of their anesthetized limb. Eventually, their phantom limb became motionless, or fixed, in a position always different from the one initially described. Only 3 of 52 patients (6%) experienced an anesthetized limb that was

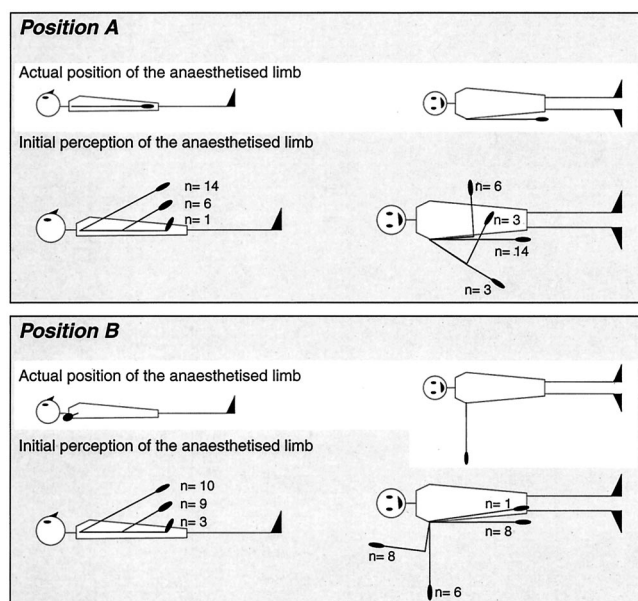


Fig. 4. Perception of the position of the phantom limb at the time of its appearance, according to the initial position of the anesthetized limb. Immediately after the end of block placement, the anesthetized limb was hidden from the patient's sight. Half of the patients had their anesthetized arm randomly placed alongside their body (*position A*), whereas in the other half, patients had their arm placed in 90° abduction (*position B*). Note that the initial position of the anesthetized limb induced the dominance of one type of misperception of position. In the group placed in position A ($n = 26$), patients were more likely to feel their anesthetized limb alongside of their body or in adduction, whereas in group B ($n = 26$), patients were more likely to perceive their anesthetized limb in abduction ($P = 0.0127$ vs. position A). Also in both positions, the majority of patients reported elevation of their anesthetized limb.

immediately motionless. Similar to the initial position, the perception of the final position of the anesthetized limb also differed in both position A and B groups. Regardless of the group, two stereotyped positions were dominant: 19 patients (37%) reported adduction of their arm with elbow flexion and their forearm and hand lying over their abdomen, and 19 other patients (37%) described abduction of their arm and forearm with elbow flexion and elevation of the limb, with their hand held close to their homolateral ear. Eighteen patients (68%) in group A felt their forearm and hand lying over their abdomen, whereas 15 patients (58%) in group B felt their hand close to their ear.

Switching of Positions

After limb positions had been switched, 31% (8 of 26) of the patients in each group (A and B) perceived their anesthetized limb in a new modified position. However, none of these patients could accurately describe the actual position of their limb.

Fusion and Recurrence

When patients were shown their hidden anesthetized limb, all patients reported that the position of their

phantom limb immediately merged with position of their real arm. Similarly, all of the patients described a recurrence of the perceptual distortion of their limb position after it had been hidden again.

Discussion

Current hypotheses to explain phantom limb syndrome related to anesthesia are based on little evidence and few systematic studies. The current study is the first to have ever precisely and simultaneously assessed the relation between the illusions of shape, postural illusions (*i.e.*, phantom limb sensation), and the time course of the impairment and abolition of the different types of sensorimotor functions during deafferentation induced by regional anesthesia. Previously, Melzack and Bromage² provided a unique and precise description of perceptual distortion of position during regional anesthesia, but their description of these abnormal sensations remained isolated and not related to the installation of the anesthetic block. Their study strongly suggested that the perceptual distortion of position occurs after the anesthetic block has become very intense, but the current study suggests that phantom limb syndrome occurs more rapidly than initially described.²

Methodologic Limitations

The main limitation of our study is that it is based partly on the patients' subjective reports. Because the sensations investigated usually were not spontaneously reported by the patients but rather were reported when they were asked to direct their attention to their anesthetized limb, suggestions from the investigator may have influenced the patients' answers. This limitation cannot be overcome in studies on the awareness of one's body parts. Therefore, the inquisitive character of our study was necessary to draw the patient's perceptual experience of his or her body out of its "natural obscurity."⁷ The qualitative nature of our multimodal sensory assessment is another limitation because the time course of sensory block is less accurately precisely described by such a method than by threshold determinations.^{8,9} However, the simplicity and rapidity of the qualitative assessment allowed parallel measurement of both sensory impairment and body position distortions at close intervals, which was a main objective of this study.

Sensorimotor Impairment and Perceptual Distortion of Position

Proprioception is a complex notion that accounts for the perception of the parts of the body in relation to each another, or the sense of position. This perception relies on the activity of Ruffini nerve endings located in the synovium of the joints and their central representation in the thalamus and somatosensory cortex. Studies

on mechanical muscle and tendon vibrations have shown that the perception of limb position is also influenced by muscle afferent signals and that a sensation of an illusory motion of a stationary limb can be provoked by vibrating a tendon.¹⁰ Further, postural hallucinations may occur in patients with spinal cord lesions as a result of the alteration of large myelinated fibers running in the posterior columns.¹¹ These observations, reported in previous studies suggesting that the abolition of proprioception generates phantom limb sensations during regional anesthesia, support the hypothesis that the abolition of proprioception is involved in the genesis of phantom limb syndrome during regional anesthesia.^{2,4,5} Historically, several reasons led to the linking phantom limb syndrome occurring during the installation of regional anesthesia with the abolition of proprioception. First, phantom limb sensation was initially described in cases of deep sensory nerve block.² Second, visual information greatly alters the perception of postural illusions during regional anesthesia because the illusory sensation of position is immediately corrected by the sight of the anesthetized limb.^{1,2,4} Third, at least two studies suggest that proprioceptive memory, related to the last position of the limb before regional anesthesia, is involved in the position where the phantom limb is perceived.^{4,5} In our study, perception of the sense of position was abolished in only 1 patient of 52, whereas in the remaining 51 patients, it remained either normal or impaired (42%) at the time of occurrence of phantom limb sensation. Then, when proprioception was assessed by testing the perception of the passive motion of a joint within the anesthetized-deafferented area, we observed that perceptual distortion of position occurred before the impairment of proprioception. However, proprioceptive performances of the mobilization of a joint are relatively poor and do not represent an accurate assessment of the proprioceptive function.¹² Proprioception could have been more accurately assessed either by tendon vibration or by measuring somesthetic evoked potentials. However, their recording, if more precise, requires specific tools not easy to use accurately in a busy operating room setting and would also have been more time consuming, contrarily to our simple clinical assessment method.^{8-10,13} However, the significant correlations found between P1, P0, and the occurrence of the phantom limb syndrome might signify that, at the time of occurrence of the phantom limb syndrome, although the perception of the sense of position remained normal, large-diameter sensory fibers responsible for the transmission of proprioceptive information were already impaired. Switching the position of the anesthetized limb after the phantom limb had become motionless provides further information on the relation between proprioception and phantom limb sensations. Almost all patients perceived some movement in their shoulder while positions were being reversed by the investigator (from po-

sition A to position B or *vice versa*), but only 31% felt (and described) their anesthetized limb (phantom limb) in a different position after the reversal. Infraclavicular block does not anesthetize the axillary nerve, which partly innervates the shoulder, enabling the perception of shoulder movement in 90% of patients.⁴ Theoretically, the new shoulder position would provide the brain with information on the actual position of the anesthetized limb and would allow patients to perceive their anesthetized limb in a new position, even though the major part of their arm was totally anesthetized. However, although the shoulder remained unanesthetized, this was not the case, with 69% of patients describing their phantom limb in the same position after the reversal of positions. It may be of importance to note that, at the time of reversal of limb position, the patients presented total abolition of perception of the sense of position within the anesthetized area. Furthermore, at the time the phantom limb became motionless, a correlation was found with abolition of perception of the mobilization of a joint within the deafferented area. Melzack and Bromage have previously reported that during the course of installation of a brachial plexus nerve block, many patients perceive motion in their phantom limb, with some even being able to voluntarily move their phantom limb. Moreover, these authors demonstrated that the phantom limb could move only until the electromyographic recording showed total disappearance of muscular activity.² This finding suggests that motor impairment is involved in the perception of motion of the phantom limb but cannot explain its genesis. The remaining minimal motor activity might participate, *via* the muscular and tendinous afferent pathways involved in the perception of the position sense and in proprioception, in the perception of motion of the deafferented limb.^{10,13} Their results, as well as the data presented herein, suggest that a complete motor block and the subsequent abolition of proprioception secondary to the disappearance of any afferent signal from muscular origin might explain how the phantom limb becomes motionless during the course of regional anesthesia. Only visual information could correct the postural illusion of the anesthetized limb, as all of the patients in the current study described fusion between their phantom limb and the actual position of their anesthetized arm when it was unmasked. The role of the visual image of the body has already been well illustrated by the observation that mirrors can induce synesthesia in a phantom limb¹⁴ and by the fact that illusions of ownership of a rubber hand can be elicited by synchronized visual and tactile stimuli in healthy subjects.¹⁵ Electrophysiologic recordings in the monkey have shown that the position of a limb may be represented in the premotor cortex by means of a convergence of visual and proprioceptive cues onto the same neurons,¹⁶ but here, normal proprioceptive information originating from the unanesthetized shoulder joint was

unable to thwart phantom limb sensations during axillary plexus nerve block. If the combination of proprioceptive and visual information at the cortical level may explain why the view of the anesthetized limb could abolish the phantom limb sensation induced by regional blocks,^{2,4,17} current data suggest that visual information is of major importance when large myelinated A β fibers have been totally blocked by the local anesthetic, or as in the case of two patients with severe sensory polyneuropathy involving specifically large myelinated fibers who completely lost the sensations of touch and position sense described by Gallagher and Cole.¹⁸

Proprioceptive Memory

It has long been acknowledged that the last input received by the proprioceptive system before regional anesthesia becomes locked in the memory,¹⁹ and it has been shown that the previous perception of leg posture is retained during spinal anesthesia. This supports the theory that sensory perception is a series of short-term memories that are constantly renewed by the ongoing sensory inputs.²⁰ However, when the sensory input is intercepted, short-term memory just before the interception becomes long-term memory. The current study supports the fact that proprioceptive memory relies on the last perceptions because the position in which the anesthetized limb was placed immediately after the block had been performed determined the position of the postural illusion. The phantom limb was more likely to be perceived with elbow flexion and the arm on the abdomen when the arm was placed straight alongside the body, whereas it was more likely to be perceived with elbow flexion and the hand close to the ipsilateral ear when the arm was placed straight and in 90° abduction. Nevertheless, these different perceptions of the phantom limb might be the consequence of the fact that the shoulder joint remained unanesthetized in this study, indicating that the perception of limb position after an axillary block is partly determined by persisting sensory inputs from the shoulder joint.⁴ More recently, Isaacson *et al.*⁵ have proposed a spinal model to study proprioceptive memory. Their hypothesis is that proprioceptive memory involves a dynamic neuroplasticity imprinting process influenced by limb position before regional anesthesia takes effect, rather than the classic body schema described by Bromage and Melzack. In their study, the misperception of leg position was related to the interval between spinal anesthesia and the assessment of the leg position. Our results also support the fact that the position of the limb before anesthesia determines the final perception of the phantom limb because we provide evidence that the position of the anesthetized limb before the performance of the regional anesthesia determined the global position of the postural illusion. We also observed that the perceived movements of the phantom limb were independent of its initial position,

with the motion of phantom limb being stereotyped. Therefore, we propose that the theory of proprioceptive memory might explain the initial position of the limb before anesthesia and determine the global position of the phantom limb sensation. However, this theory does not explain the temporospatial shift in position of the phantom limb from the moment this postural illusion occurs up to the moment it becomes motionless or fixed. The current data cannot explain this observation, but it suggests that deafferentation unmasks a fixed postural pattern. However, the current results do not provide further information on whether this flexed perceptual representation of the deafferented body areas derives from a fixed body schema or is a memory of an archaic tetrapod schema disinhibited by anesthesia.

Conclusion

In conclusion, the current study provides the first description of both the time course of the impairment of sensorimotor functions and the phantom limb syndrome induced by regional anesthesia. We confirm that perceptual distortions induced by regional anesthesia occur early and are not only restricted to the misperception of position, but also involve the misperception of size and shape of the anesthetized limb, which is related to the impairment of small-diameter sensory fibers. Our results suggest that the occurrence of the phantom limb syndrome might be related to the impairment of proprioception. However, a puzzling observation in our study is that the onset of the phantom limb syndrome closely follows the abolition of the sensations elicited by heat, cold, and pin prick, whereas touch and position sense remained unaltered, perhaps calling into question the involvement of small-diameter sensory C and A δ fibers in the genesis of phantom limb syndrome. Finally, our study provides a better understanding of the determinants of the position of phantom limb syndrome because we showed that the final position of the phantom limb is related both to the abolition of proprioception and to the initial position of the anesthetized limb, supporting the previously proposed notion of proprioceptive memory. We also demonstrated that the progressive shift in the perception of the phantom limb was independent of the initial position of the anesthetized limb and corresponded to a stereotyped imaginary spatial motion of the anesthetized limb.

References

1. Paqueron X, Leguen M, Rosenthal D, Coriat P, Willer JC, Danziger N: The phenomenology of body image distortions induced by regional anaesthesia. *Brain* 2003; 126:702-12
2. Melzack R, Bromage PR: Experimental phantom limbs. *Exp Neurol* 1973; 39:261-9
3. Bromage PR, Melzack R: Phantom limbs and the body schema. *Can Anaesth Soc J* 1974; 21:267-74
4. Gentili ME, Verton C, Kinirons B, Bonnet F: Clinical perception of phantom

limb sensation in patients with brachial plexus block. *Eur J Anaesthesiol* 2002; 19:105-8

5. Isaacson S, Funderburk M, Yang J: Regulation of proprioceptive memory by subarachnoid regional anesthesia. *ANESTHESIOLOGY* 2000; 93:55-61

6. Jandard C, Gentili ME, Girard F, Ecoffey C, Heck M, Laxenaire MC, Bouaziz H: Infraclavicular block with lateral approach and nerve stimulation: extent of anaesthesia and adverse effects. *Reg Anesth Pain Med* 2002; 27:37-42

7. O'Shaughnessy B: Proprioception and the body image, *The Body and the Self*. Edited by Bermudez JL, Marcel A, Eilan N. Cambridge, Massachusetts, MIT Press, 1995, pp 175-205

8. Brennum J, Nielsen PT, Horn A, Arendt-Nielsen L, Secher NH: Quantitative sensory examination of epidural anaesthesia and analgesia in man: Dose-response effect of bupivacaine. *Pain* 1994; 56:315-26

9. Curatolo M, Petersen-Felix S, Arendt-Nielsen L: Sensory assessment of regional analgesia in humans: A review of methods and applications. *ANESTHESIOLOGY* 2000; 93:1517-30

10. Lackner JR: Some proprioceptive influences on the perceptual representation of body shape and orientation. *Brain* 1988; 111:281-97

11. Nathan PW, Smith MC, Cook AW: Sensory effects in man of lesions of the posterior columns and of some other afferent pathways. *Brain* 1986; 109:1003-41

12. Refshauge KM, Chan R, Taylor JL, McCloskey DI: Detection of movements imposed on human hip knee ankle and toe joints. *J Physiol (Lond)* 1995; 488:231-41

13. Roll JP, Vedel JP, Ribot E: Alteration of proprioceptive messages induced by tendon vibration in man: A microneurographic study. *Exp Brain Res* 1989; 76:213-22

14. Ramachandran VS, Rogers-Ramachandran D: Synaesthesia in phantom limbs induced with mirrors. *Proc R Soc Lond B Biol Sci* 1996; 263:377-86

15. Botvinick M, Cohen J: Rubber hands "feel" touch that eyes see (letter). *Nature* 1998; 39:756

16. Graziano MS: Where is my arm? The relative role of vision and proprioception in the neuronal representation of limb position. *Proc Natl Acad Sci U S A* 1999; 96:10418-21

17. Wallgren GR: Phantom experience at spinal anaesthesia. *Ann Chir Gynecol Fenn* 1954; 43(suppl):486-500

18. Gallagher S, Cole J: Body image and body schema in a deafferented subject. *J Mind Behav* 1995; 16:369-90

19. Prevoznick SJ, Eckenhoff JE: Phantom sensation during spinal anesthesia. *ANESTHESIOLOGY* 1964; 25:767-70

20. Crick F, Koch C: Towards a neurobiological theory of consciousness. *Semin Neurosci* 1990; 2:263-75