

## Spontaneous Occurrence of the Disposition to Malignant Hyperthermia

Henrik Rueffert, M.D.,\* Derk Olthoff, M.D.,† Christine Deutrich, M.D.‡

ONE characteristic of malignant hyperthermia (MH) is the autosomal-dominant mode of inheritance. This implies that at least one parent of an affected patient should be predisposed to MH. In this report, we describe two families in which MH susceptibility developed spontaneously through a neomutation. These families attracted attention because both parents of an MH-susceptible individual were diagnosed as MH-negative in the *in vitro* contracture test (IVCT).

The IVCT was performed with halothane and caffeine according to the protocol of the European MH Group.<sup>1</sup> This test may provide the following diagnoses: MH-susceptible (MH-positive), MH-negative, or MH-equivocal (possible MH-positive).

Cluster regions of the skeletal ryanodine receptor gene (RYR1), in which MH-related mutations have been identified, were amplified by polymerase chain reaction and subsequently analyzed by the direct sequencing technique previously described.<sup>2</sup> Chromosome 19 microsatellite markers were amplified by polymerase chain reaction using labeled fluorescent-tag primers (D19S228, 19S421, RYR.PCR1, D19S422, D19S223, as recommended by the European MH Group, genetic section§) and were checked by fragment gel analysis in the ABI PRISM 377 DNA sequencer (Applied Biosystems, Foster City, CA).

### Case Report

A 12-year-old girl related to the first family was referred to our MH investigation unit because of elevated resting creatine kinase levels (700 U/l) and rapid exhaustion after intensive exercise. The suspected MH disposition was confirmed by an MH-susceptible diagnosis in the *in vitro* halothane/caffeine muscle test. MH had been transmitted from the mother, who was found to be MH-susceptible 2 months later. Interestingly, both grandparents showed normal responses in the halothane/caffeine muscle test (MH-negative diagnosis) and had undergone previous general anesthetics with no clinical complications. A familial genetic screening for MH-related mutations in the RYR1 gene revealed an Arg2435His mutation (G7304→A) in all MH-susceptible family

members, but not in the MH-negative individuals. This substitution is one of the mutations regarded as causative of MH, according to the guidelines of the European MH Group for molecular genetic detection of MH susceptibility.<sup>3</sup> To exclude the possibility of false paternity of the grandfather, we performed haplotyping with chromosome 19 microsatellite markers. The results of this segregation analysis proved that a true relationship between the investigated generations was almost certain (fig. 1).

In the second family, a 15-year-old girl developed a tachycardia of 140 beats/min, 45 min after induction of anesthesia. Carbon dioxide rose to 90 mmHg, followed by a metabolic acidosis (pH 7.21) and a maximal serum creatine kinase elevation of 1655 U/l. General anesthesia for an operation on the spinal column was induced with thiopental, alfentanil, and vecuronium, and was maintained with isoflurane. When MH was suspected to be the possible cause of the symptoms, the isoflurane supply was interrupted and the symptoms rapidly declined. Dantrolene was not administered. The susceptibility to MH was confirmed by the IVCT 3 months later, and the histopathologic examination of a muscle biopsy also revealed the presence of central core disease. A RYR1 Ile2453Thr (T7358→C) substitution was identified by DNA testing. The patient's mother, who also showed pathologic responses in the IVCT (MH-susceptible), carried the same Ile2453Thr mutation, but both grandparents showed a diagnostic constellation similar to that of family 1: both were found to be MH-negative in the IVCT, and neither carried the familial mutation.

The response of the muscle specimens from MH-susceptible and MH-negative individuals in the IVCT is shown in table 1, supplemented by sequencing gel traces of normal and mutated RYR1 alleles in figure 2.

### Discussion

It is a known phenomenon of the routine MH diagnosis that in a few MH families, the results of the IVCT do not agree with the theoretical autosomal-dominant mode of inheritance of the disorder. This is sometimes a problem for MH investigators, who must interpret such findings accurately while accounting for the patient's cultural background and personality.

Various reasons must be considered for those constellations in which both parents of an MH-susceptible patient show a normal response in the IVCT. An incorrect biologic paternity appears to be the most likely reason for the nontransmission of the MH disposition from a direct ancestor (frequencies of up to 10% in the general population were found in a study by the University of Virginia Commonwealth at Richmond). However, MH investigators should deal very carefully with any questions of paternity so as to not to get involved in or initiate a family crisis. In the families presented here, the paternity became plausible by the microsatellite marker segregation.

The second theoretical possibility is an incorrect result of the IVCT. However, the *in vitro* halothane/caffeine muscle

\* Staff Anesthesiologist, † Professor and Director, ‡ Assistant Professor, Department of Anesthesiology.

Received from the Department of Anesthesiology and Intensive Care Medicine, University Hospital, Leipzig, Germany. Submitted for publication April 29, 2003. Accepted for publication September 2, 2003. Support was provided solely from institutional and/or departmental sources.

Address reprint requests to Dr. Rueffert: University Hospital of Leipzig, Department of Anesthesiology and Intensive Care Medicine, Liebigstr. 20a, D-04103, Leipzig, Germany. Address electronic mail to: ruef@medizin.uni-leipzig.de. Individual articles may be purchased through the Journal Web site, [www.anesthesiology.org](http://www.anesthesiology.org).

§ Available at [www.emhg.org](http://www.emhg.org). Accessed April 25, 2003.

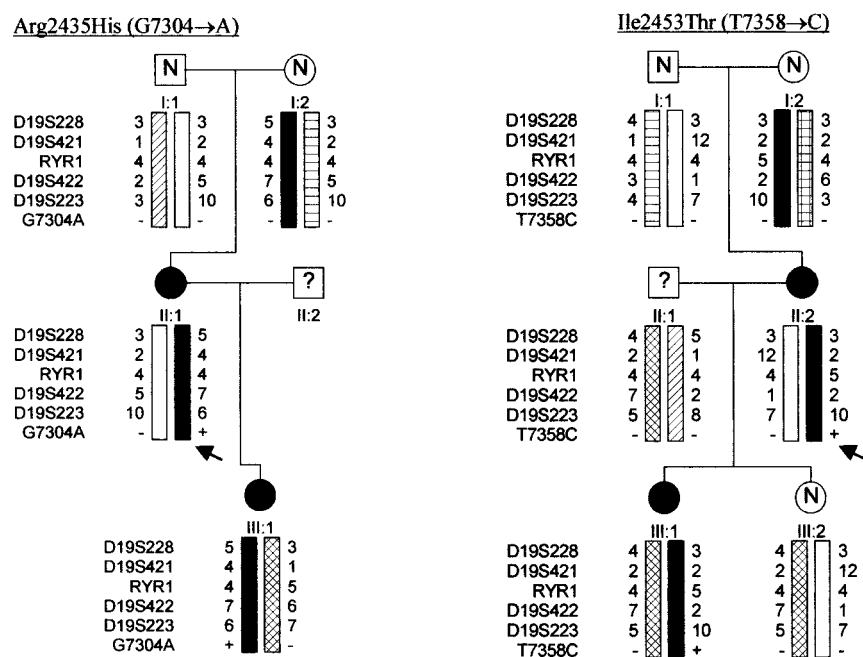


Fig. 1. The segregation of the RYR1 mutations and chromosome 19.13.1 markers in the two investigated MH families. The presence/absence of the mutation is indicated by a + or – sign. The arrows indicate the occurrence of a neomutation in the corresponding generation. Regarding IVCT results, the filled circles indicate MH-susceptible-negative; the open circles with N indicate MH-negative diagnosis, and the white boxes with question marks indicate patients whose status has not been determined.

test is a well-established method, elaborated by MH experts to determine an MH disposition preclinically and to ensure the greatest possible safety for the patients. This is reflected in the high sensitivity (99% and 97%, respectively) of the test according to both available protocols.<sup>1,4–6</sup>

An alternative mode of transmission of the MH disposition, e.g., recessive forms, may be a third reason for MH-normal parents, but so far this has not been described for MH.

Deduced from the results of the segregation of mutations Arg2435His (G7304→A) and Ile2453Thr (T7358→C), both located in the central MH hot spot region of the RYR1 gene<sup>7</sup> as well as of the microsatellite markers, it was highly likely that the MH-susceptibility in the presented families was spontaneously caused by a neomutation. The susceptibility was then transmitted in

the known autosomal-dominant manner. Other hitherto described *de novo* mutations in the RYR1 gene have occurred exclusively in families with a sporadic central core disease, and were found only in the C-terminal domain (MH/central core disease region 3).<sup>8</sup>

Although both identified mutations also appear to correlate with central core disease (see the genetic European MH Group list for the Arg2435His and case report of the Ile2453Thr mutation carrier), there is some functional evidence concerning their possible causative nature for MH.<sup>9–11</sup>

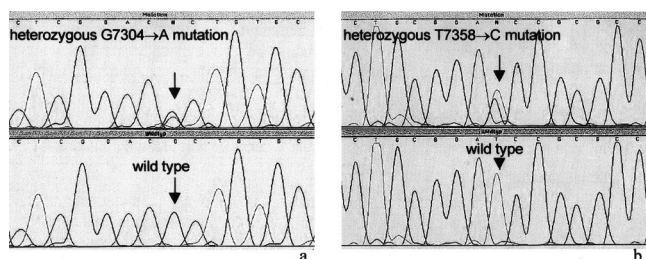
The molecular genetic findings in these two families demonstrate that sporadic forms of MH are of clinical relevance, and that MH may also develop in the normal population. This must be considered when interpreting unclear IVCT constellations and in forensic matters.

Table 1. Results of the *In Vitro* Contracture Tests

Family Mutation (RYR1)/Patient	Threshold Concentration (mM)		Contracture Force (mN) at		Diagnosis
	Halothane	Caffeine	0.44 mM Halothane	2.0 mM Caffeine	
G7304A					
I:1	0.88	> 4.0	0.0	0.0	MHN
I:2	> 0.88	4.0	0.0	0.0	MHN
II:1	0.22	1.0	27	15	MHS
II:2	—	—	—	—	—
III:1	0.22	1.5	16	8	MHS
T7358C					
I:1	> 0.88	> 4.0	0.0	0.0	MHN
I:2	> 0.88	> 4.0	0.0	0.0	MHN
II:1	—	—	—	—	—
II:2	0.11	0.5	17.0	14.0	MHS
III:1	0.22	1.5	8.0	7.0	MHS
III:2	> 0.88	4.0	0.0	0.0	MHN

Roman numerals indicate familial generation; arabic numerals indicate number of individuals.

MHN = malignant hyperthermia-negative; MHS = malignant hyperthermia-susceptible; RYR1 = skeletal ryanodin receptor gene.



**Fig. 2.** The sequencing gel traces of regions of RYR1 exon 45 (a) and 46 (b), in which the G7304→A (Arg2435His) and the T7358→C (Ile2453Thr) were detected.

## References

1. European Malignant Hyperthermia Group: A protocol for the investigation of malignant hyperpyrexia (MH) susceptibility. *Br J Anaesth* 1984; 56:1267-9
2. Rueffert H, Olthoff D, Deutrich C, Froster UG: Determination of a positive malignant hyperthermia (MH) disposition without the in vitro contracture test in families carrying the RYR1 Arg614Cys mutation. *Clin Genet* 2001; 60:117-24
3. Urwyler A, Deufel T, McCarthy T, West S: Guidelines for molecular genetic detection of susceptibility to malignant hyperthermia. *Br J Anaesth* 2001; 86:283-7
4. Larach MG: Standardization of the caffeine halothane muscle contracture test. North American Malignant Hyperthermia Group. *Anesth Analg* 1989; 69:511-5

5. Allen GC, Larach MG, Kunselman AR: The sensitivity and specificity of the caffeine-halothane contracture test: A report from the North American Malignant Hyperthermia Registry. The North American Malignant Hyperthermia Registry of MHAUS *Anesthesiology* 1998; 88:579-88

6. Ørding H, Brancadoro V, Cozzolino S, Ellis FR, Glauber V, Gonano EF, Halsall PJ, Hartung E, Heffron JJ, Heytens L, Kozak-Ribbens G, Kress H, Krivosic-Horber R, Lehmann-Horn F, Mortier W, Nivoche Y, Ranklev-Twetman E, Sigurdsson S, Snoeck M, Stieglitz P, Tegazzin V, Urwyler A, Wappler F: In vitro contracture test for diagnosis of malignant hyperthermia following the protocol of the European MH Group: Results of testing patients surviving fulminant MH and unrelated low-risk subjects. The European Malignant Hyperthermia Group. *Acta Anaesthesiol Scand* 1997; 41:955-66

7. McCarthy TV, Quane KA, Lynch PJ: Ryanodine receptor mutations in malignant hyperthermia and central core disease. *Hum Mutat* 2000; 15:410-17

8. Monnier N, Romero NB, Leral J, Landrieu P, Nivoche Y, Fardeau M, Lunardi J: Familial and sporadic forms of central core disease are associated with mutations in the C-terminal domain of the skeletal muscle ryanodine receptor. *Hum Mol Genet* 2001; 10:2581-92

9. Zhang Y, Chen HS, Khanna VK, De Leon S, Phillips MS, Schappert K, Britt BA, Browell AK, MacLennan DH: A mutation in the human ryanodine receptor gene associated with central core disease. *Nat Genet* 1993; 5:46-50

10. Tong J, Oyama H, Demarex N, Grinstein S, McCarthy TV, MacLennan DH: Caffeine and halothane sensitivity of intracellular  $Ca^{2+}$  release is altered by 15 calcium release channel (ryanodine receptor) mutations associated with malignant hyperthermia and/or central core disease. *J Biol Chem* 1997; 272:26332-9

11. Wehner M, Rueffert H, Koenig F, Meinecke CD, Olthoff D: The Ile2453Thr mutation in the ryanodine receptor 1 is associated with facilitated calcium release from sarcoplasmic reticulum by 4-chloro-m-cresol in human myotubes. *Cell Calcium* 2003; 34:163-8

*Anesthesiology* 2004; 100:733-6

© 2004 American Society of Anesthesiologists, Inc. Lippincott Williams & Wilkins, Inc.

## A Bifurcated Tracheal Tube for a Neonate with Tracheoesophageal Fistula

Yoshikazu Miyamoto, M.D., Ph.D.,\* Keiko Kinouchi, M.D., Ph.D.,† Akihiro Taniguchi, M.D.,\* Seiji Kitamura, M.D., Ph.D.‡

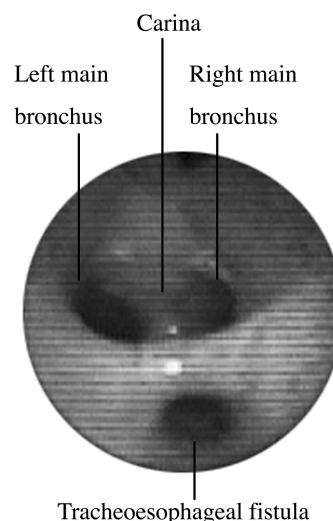
THE goal of airway management in a patient with esophageal atresia (EA) and tracheoesophageal fistula (TEF) is to maintain adequate ventilation without ventilating the fistula, which can lead to ineffective ventilation, gastric distention or rupture, hypotension, or reflux of gastric contents.<sup>1</sup> There have been two major strategies for achieving this goal: proper positioning of a endotracheal tube<sup>2</sup> or catheter occlusion of the TEF,<sup>3-6</sup> both of which have potential difficulties.

Here we present a novel bifurcated endotracheal tube used to deliver air/oxygen directly to the distal airway without ventilating the fistula, and its application in one patient with a large TEF just above the carina.

### Case Report

The patient was male, weighed 2,908 g at 41 weeks gestational age, had difficulty feeding, and was transferred to our hospital at 2 days of

age. A diagnosis of EA/TEF was made, and cardiac ultrasonography revealed that he had a large patent ductus arteriosus (PDA), atrial septal defect, and mitral and tricuspid valve regurgitation. Because of the severity of his congenital heart disease, radical operation of the EA/TEF was postponed and an emergent gastrostomy was performed using general anesthesia. Intraoperative bronchoscopy revealed a large TEF (> 4 mm in diameter, as large as the patient's bilateral main bronchi) just proximal to the carina on the dorsal side of the trachea (fig. 1). Proper positioning of the endotracheal tube to avoid ventilation of the fistula<sup>2</sup> was impossible because of the short distance from the TEF to



**Fig. 1.** Fiberoptic view of the patient's trachea.

\* Staff Physician, † Director, Department of Anesthesiology, ‡ Hospital Deputy Director.

Received from the Osaka Medical Center and Research Institute for Maternal and Child Health, Osaka, Japan. Received for publication May 1, 2003. Accepted for publication September 9, 2003. Support was provided solely from institutional and/or departmental sources.

Address reprint requests to Dr. Miyamoto: Osaka Medical Center and Research Institute for Maternal and Child Health, Department of Anesthesiology, 840 Murodo-cho, Izumi, Osaka 594-1101, Japan. Address electronic mail to: miyamoto@anes.med.osaka-u.ac.jp. Individual article reprints may be purchased through the Journal Web site, [www.anesthesiology.org](http://www.anesthesiology.org).



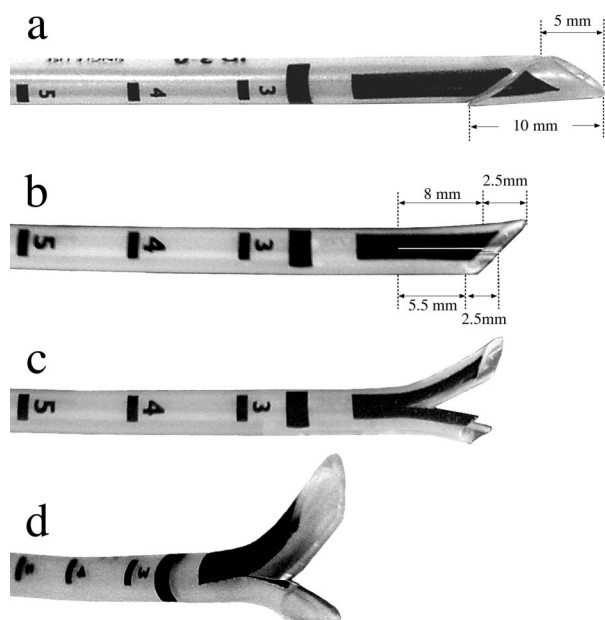


Fig. 2. Processing the bifurcated endotracheal tube.

the carina. The tube was therefore placed in an ordinary position (above the fistula), and the patient was carefully ventilated with low peak inspiratory pressure in the semi-Fowler position. On completion of surgery, he resumed spontaneous breathing and his trachea was extubated. The next day, the patient exhibited tachypnea, oliguria, and severe metabolic acidosis (pH 7.239,  $P_{aCO_2}$  12.4 mmHg, base excess  $-21.3$  mEq/L). Ultrasonography revealed cardiac insufficiency (right ventricular end diastolic diameter, 17.3 mm; left ventricular end diastolic/systolic diameter, 14.2/11.7 mm; ejection fraction, 40%), deterioration of mitral regurgitation, and increased left-to-right shunting through the large PDA, for which an emergent PDA clipping was indicated. After induction of anesthesia, ventilation was difficult because of a massive air leak through the gastrostomy tube.<sup>3-5,7</sup> Intra-gastric pressure, monitored by an aneroid manometer, exhibited inflation of the stomach on each ventilation. We managed to ventilate the lungs by limiting the intragastric pressure to 10–15 cmH<sub>2</sub>O, which was achieved by intermittent clamping and declamping of the gastrostomy tube.

In preparation for the patient's EA/TEF repair, we developed a bifurcated tube to deliver air/oxygen directly to the distal airway without ventilating the fistula. The tip of a Portex® endotracheal tube,

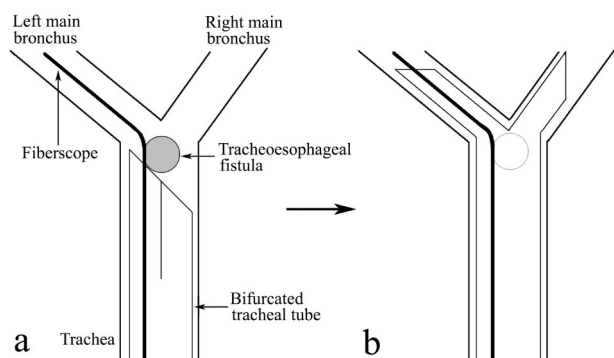


Fig. 3. Placement of the bifurcated tube under fiberoptic guidance. A fibroscope is inserted into the bifurcated tube and advanced into the left main bronchus (a). The tube is then advanced over the fibroscope until the tip splays to sit astride the carina (b).

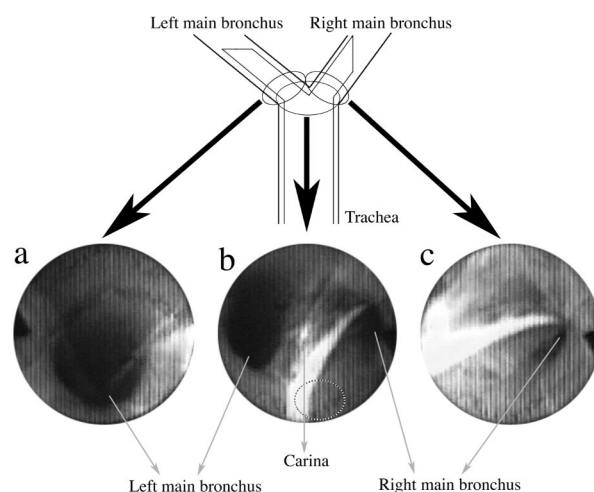


Fig. 4. Fiberoptic views of the bifurcated tube in place. The lumina of bilateral bronchi are patent (a and c). The tip of the tube splays to sit astride the carina. The opening of the tracheo-esophageal fistula is depicted by the dotted circle, which exists behind the dorsal aspect of the endotracheal tube (b).

3.0 mm ID (SIMS Portex Inc., Keene, NH), was cut to create a bevel facing the right side (fig. 2a). Then the distal end of the tube, approximately 8 mm in length, was incised longitudinally (fig. 2b). When splayed open, it became a bifurcated tip with two half-lumens (fig. 2c and d). The cut surface of the tube was smoothed with fine sandpaper and tetrahydrofuran,<sup>8</sup> and the bifurcated segments were left almost closed (fig. 2b). We then simulated introducing the tube to sit astride the carina using a neonatal tracheal model, which we constructed by suturing two 4.5-mm-ID tracheal tubes together.

The operation was scheduled for day 8. With the approval of our institute's ethical committee and the informed consent of the patient's parents, placement of the bifurcated endotracheal tube was attempted after induction of anesthesia. Because the bifurcated tip made it difficult for the tube to pass through the glottis, we held the midpoint of the bifurcated segments of the tube in mosquito forceps so that the bifurcated tip was closed during passage through the glottis. Once the closed tip passed through the glottis, the forceps were removed and the tube was advanced into the trachea. While maintaining ventilation *via* a swivel connector, a fibroscope (model LF-P; Olympus Optical Co. Ltd., Tokyo, Japan) was inserted into the tube and advanced into the left main bronchus, just proximal to the opening of the left upper lobe bronchus (fig. 3a). The tube was then advanced over the fibroscope until the left half of the bifurcated tip was introduced into the left main bronchus. Because the right main bronchus had a smaller branching angle from the trachea than the left main bronchus, the right half of the divided tip tended to enter the right main bronchus, and the bifurcated segments of the tube were forced to splay to sit astride the carina (fig. 3b).

The fibroscope was then withdrawn to the carinal level and proper placement of the tube was confirmed (fig. 4). Ventilation was ascertained by chest movement, auscultation, intragastric pressure monitoring, and arterial blood gas analysis. The increase in intragastric pressure diminished, and the arterial blood gas proved adequate oxygenation without carbon dioxide retention. A chest radiograph also confirmed proper positioning of the tube (fig. 5). On completion of surgery, the bifurcated tube was exchanged for an ordinary 3.0-mm-ID tube. Post-operative bronchoscopy demonstrated no bleeding except for the slight flush of tracheal mucosa around the carina. The patient was transferred to the ICU and was weaned from the ventilator on the second postoperative day. There were no sequelae related to the use of the bifurcated tube.

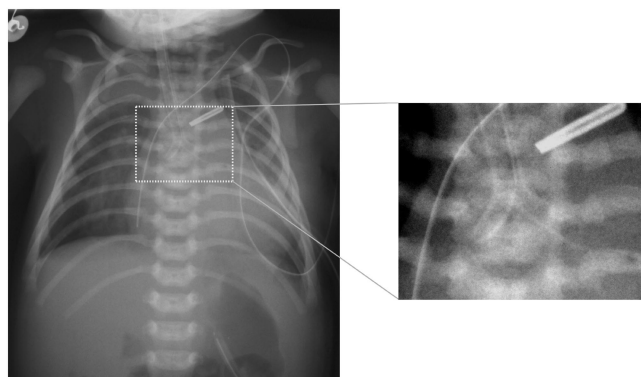


Fig. 5. Radiographic view of the tip of the tube splayed astride the carina.

## Discussion

The most common way to avoid entry of gas into a TEF is to position the endotracheal tube so that the tip is located just proximal to the carina but distal to the fistula.<sup>2</sup> This works well if the fistula is located far enough above the carina. However, because the fistula may be located just above the carina,<sup>3</sup> it may be difficult to strictly maintain this position.<sup>7</sup> A subtle change in the tube position, often caused by surgical manipulation or patient's movement, could be critical. Therefore, this technique would not be suitable for several days of intensive care for the EA/TEF patient with severe respiratory distress syndrome, pneumonia, or prematurity requiring mechanical ventilation before surgery.<sup>1,4,5,7</sup>

Occlusion of the fistula with a Fogarty embolectomy catheter, either through the trachea (anterograde occlusion<sup>3,4,6</sup>) or the gastrostomy site (retrograde occlusion<sup>5</sup>), is another strategy that has been reported by several authors. This method can be effective but may not be feasible in every case.<sup>7</sup> Disadvantages of the method are as follows:

1. There are potential technical difficulties in placing the catheter into the fistula. In anterograde occlusion, manipulation of a Fogarty catheter into the fistula through the trachea under a thin rigid bronchoscope is technically difficult and requires interruption of ventilation during the procedure.<sup>7</sup> Limitation of the size of the rigid bronchoscope could also be a problem. The smallest size available is 4.2 mm OD (DOESEL-HUZLY Pediatric Bronchoscope K10339F; Karl Storz GmbH & Co., Tuttlingen, Germany; size 2.5, 3.5 mm ID, 4.2 mm OD, 20 cm in length), which is equal to the OD of a 3.0-mm-ID Portex® endotracheal tube (4.2 mm). Thus, the method is not applicable to patients too small to accept a 3.0-mm-ID endotracheal tube,<sup>3</sup> which is often the case.<sup>1,7</sup> Retrograde occlusion is technically complicated and necessitates the placement of a gastrostomy, which is no longer routinely performed in patients with no other complicating factors.<sup>1,3,6,7</sup>
2. The catheter could be dislocated to occlude the tra-

chea,<sup>4,5</sup> either by surgical manipulation or the patient's movement, making it totally impossible to ventilate.

3. The catheter might damage the esophageal mucosa in contact with the balloon by compromising its circulation.<sup>5,7</sup>

Compared with the two strategies mentioned, our bifurcated tube has several advantages:

1. It is easy to prepare and easy to place under fiberoptic guidance.
2. It does not require rigid bronchoscopy and is not limited by the size of the patient's trachea. By using smaller tracheal tubes, our method can be applied to premature neonates.
3. There may be less risk of accidental displacement with the bifurcated tip sitting astride the carina; thus, it may be useful not only for intraoperative management but also for management of those patients requiring mechanical ventilation before surgery.<sup>1,4,5,7</sup>
4. It does not require interruption of ventilation during the procedure.
5. It may help in the event of tracheomalacia, a common complication in EA/TEF patients.<sup>9</sup>
6. It may also be applicable to a laryngotracheoesophageal cleft, in which a much more complicated use of a bifurcated endotracheal tube with each lumen entering two main bronchi has been reported.<sup>10</sup>

On the other hand, our tube does have its disadvantages. First, the half-round tips may flatten or turn over and occlude the bronchi, especially when the tube is inserted too far. If the tube is too small, the two tips might fold backward as the tube passes down the trachea. However, using an adequately sized tube and maintaining the correct position of the tube can avoid these complications.

Second, the bifurcated tube might compromise the ventilation of the right upper lobe, especially when the right upper lobe bronchus is very close to the carina or a tracheal bronchus exists. As the length of the right main bronchus (the length of the right main bronchus to the origin of the right upper lobe bronchus) in neonates is reported to be  $9.92 \pm 1.67$  mm (mean  $\pm$  SD),<sup>11</sup> we consider that the right side of the bifurcation should be shorter than 6.48 mm (mean  $- 2$  SD value) at the lateral aspect of the tube to avoid occlusion of the right upper lobe bronchus. However, when the bifurcation becomes shorter, placing the bifurcated tip to sit astride the carina and avoiding dislocation of the tube would be more difficult. In the trials using the neonatal tracheal model, we found that the bifurcated tip could not easily be placed to sit astride the carina when the longitudinal incision was shorter than 8 mm. Thus, we decided the incision should be 8 mm long, which resulted in a 5.5-mm distance from the carina to the distal end of the right bifurcated segment of the tube at the lateral aspect of the tube (fig. 2b). Assuming that an abnormal origin of

the right upper lobe bronchus did not exist, there was little risk of occluding the right upper lobe bronchus because the distance was shorter than 6.48 mm.

Finally, in rare cases, the bifurcated tube is ineffective when a TEF exists at the bronchial level.

Another controversial point of managing this case was the associated major congenital heart disease. EA/TEF patients often have complicated congenital heart disease, which can alter the outcome and management of TEF. However, heart disease is not necessarily an impediment to primary repair of the EA/TEF.<sup>3,12</sup> In our case, the patient's PDA was so large that circulatory deterioration was anticipated to occur during primary repair, which is performed in the left decubitus position. Therefore, we decided to perform a gastrostomy and to delay the surgical repair of the EA/TEF. As we had anticipated, the patient deteriorated soon and subjected to emergent PDA ligation.

## References

1. Chahine AA, Ricketts RR: Esophageal atresia in infants with very low birth weight. *Semin Pediatr Surg* 2000; 9:73-8
2. Salem MR, Wong AY, Lin YH, Firor HV, Bennett EJ: Prevention of gastric distension during anesthesia for newborns with tracheoesophageal fistulas. *ANESTHESIOLOGY* 1973; 38:82-3
3. Andropoulos DB, Rowe RW, Betts JM: Anaesthetic and surgical airway management during tracheo-oesophageal fistula repair. *Paediatr Anaesth* 1998; 8:313-9
4. Filston HC, Chitwood RC Jr, Schkolne B, Blackmon LR: The Fogarty balloon catheter as an aid to management of the infant with esophageal atresia and tracheoesophageal fistula complicated by severe RDS or pneumonia. *J Pediatr Surg* 1982; 17:149-51
5. Karl HW: Control of life-threatening air leak after gastrostomy in an infant with respiratory distress syndrome and tracheoesophageal fistula. *ANESTHESIOLOGY* 1985; 62:670-2
6. Reeves ST, Burt N, Smith CD: Is it time to reevaluate the airway management of tracheoesophageal fistula? *Anesth Analg* 1995; 81:866-9
7. Templeton JM Jr, Templeton JJ, Schnauffer L, Bishop HC, Ziegler MM, O'Neil JA Jr: Management of esophageal atresia and tracheoesophageal fistula in the neonate with severe respiratory distress syndrome. *J Pediatr Surg* 1985; 20:394-7
8. Nishimura M, Nakano S, Ueyama H, Tashiro C: Airway management with a special tube in an infant with bronchial obstruction (letter). *ANESTHESIOLOGY* 1992; 76:322
9. Wailoo MP, Emery JL: The trachea in children with tracheo-oesophageal fistula. *Histopathology* 1979; 3:329-38
10. Donahoe PK, Gee PE: Complete laryngotracheoesophageal cleft: Management and repair. *J Pediatr Surg* 1984; 19:143-8
11. Jit H, Jit I: Dimensions and shape of the trachea in the neonates, children and adults in northwest India. *Indian J Med Res* 2000; 112:27-33
12. Spitz L: Esophageal atresia: Past, present, and future. *J Pediatr Surg* 1996; 31:19-25

Anesthesiology 2004; 100:736-7

© 2004 American Society of Anesthesiologists, Inc. Lippincott Williams & Wilkins, Inc.

## Anesthetizing the Phantom: Peripheral Nerve Stimulation of a Nonexistent Extremity

Stephen M. Klein, M.D.,\* John Eck, M.D.,\* Karen Nielsen, M.D.,\* Susan M. Steele, M.D.†

SPINAL,<sup>1</sup> epidural,<sup>2</sup> and brachial plexus blocks<sup>3,4</sup> have been shown to reversibly block phantom limb sensations and pain when performed on amputees. These techniques may also offer a regional anesthetic alternative in amputees with complex coexisting disease. Despite these advantages, performing a peripheral nerve block on a previously amputated limb may be difficult because detection of a motor response to electrical nerve stimulation may not be possible. We present a case of anesthesia using a sciatic nerve block performed with phantom nerve stimulation of a nonexistent extremity. The block produced a numb phantom limb and excellent operative anesthesia.

## Case Reports

A 57-yr-old woman (American Society of Anesthesiologists physical status III) was scheduled for drainage of an abscess on the stump of her

right below-the-knee amputation. Her medical history was significant for insulin-dependent diabetes, coronary artery disease, peripheral vascular disease, gastroesophageal reflux, and renal insufficiency. She had undergone her initial right below-the-knee amputation 6 yr earlier. Two months after her right below-the-knee amputation, she underwent a left below-the-knee amputation. She had constant bilateral phantom sensations that her feet were still present. The sensations were vivid and consisted of an entire foot on each side. They were not associated with perceived altered length, size, or location. She also had constant phantom pain that she described as sharp, stabbing, and throbbing. On a verbal pain scale (0 = no pain and 10 = the worst pain imaginable) she rated the phantom pain as 6. Physical examination was remarkable for a right amputation 4 inches below the knee with a 5-cm ulcer on the lateral aspect of the stump. Her daily oral medications included 20 mg omeprazole, 100 mg metoprolol, 80 mg furosemide, 325 mg aspirin, 300 mg gabapentin twice daily, and 10 mg cyclobenzaprine three times daily, as well as 4 U each morning and 6 U each evening of subcutaneous neutral protamine Hagedorn insulin.

A femoral and sciatic nerve block was planned. The procedure was explained to the patient, and she was encouraged to report any change in sensation or movement in her phantom extremity during the block placement. Standard monitoring was placed, and the patient was sedated using 100 µg fentanyl and 2 mg midazolam IV. A classic sciatic nerve block as described by Labat<sup>5</sup> was performed using a nerve stimulator connected to a 21-gauge, 100-mm, short-bevel insulated needle (B. Braun Medical, Bethlehem, PA). The nerve stimulator was set at 1.5 mA. The initial insertion of the needle produced a hamstring motor response. The needle was redirected medially and the patient reported movement in her phantom foot. When asked to be more specific about the movement, she first said "It's just moving;" after a few seconds she said "Its moving like this," at which point she began

\* Assistant Professor, † Associate Professor, Department of Anesthesiology.

Received from the Department of Anesthesiology, Duke University Medical Center, Durham, North Carolina. Received for publication June 4, 2003. Accepted for publication September 22, 2003. Support was provided solely from institutional and/or departmental sources.

Address reprint requests to Dr. Klein: Department of Anesthesiology, Box 3094, Duke University Medical Center, Durham, NC 27710. Address electronic mail to: klein006@mc.duke.edu. Individual article reprints may be purchased through the Journal Web site, www.anesthesiology.org.



tapping her index finger in a flexing motion in coordination with the 2-Hz signal of the nerve stimulator. The current was reduced to 0.5 mA, and 20 ml ropivacaine, 0.5%, with 1:400,000 epinephrine was injected. The patient was placed in the supine position and, using a nerve stimulator, a femoral nerve block using mepivacaine 1% with 1:400,000 epinephrine was performed to cover the saphenous nerve distribution. Three minutes after the sciatic block, the patient reported a decrement in her phantom pain to 3 (out of 10). When asked about her extremity 3 min later she said, "It's just gone. There's no pain." When asked the same question 3 min after that she said, "No, I take that back. There's no pain and my foot is numb." She reported no changes in her contralateral phantom or pain. The patient subsequently underwent abscess drainage with no postoperative complications. The sensation returned in her phantom foot approximately 24 h after block placement. There was also return of her usual phantom pain at about the same time.

## Discussion

This case demonstrates the successful use of a nerve stimulator technique to elicit the sensation of movement in a phantom extremity. It further illustrates that the perception of movement can be replicated by a proximal stimulus without the presence of an extremity or peripheral cues 6 yr after an amputation. Although spinal, epidural, and axillary blocks have been previously reported as effective at blocking phantom limbs, to our knowledge this is the first report using a sciatic block to produce these results. Given the prevalence of lower limb amputations and the inherent difficulties in providing lower extremity blocks in this population, this technique, if reproducible, may help facilitate their performance.

Peripheral nerve stimulation has been a useful adjunct when performing regional anesthesia. Conceptually, by preferentially stimulating A- $\delta$  nerves with a low current and a 0.1-ms pulse width-square waveform, the needle can be located in close proximity to a peripheral nerve, facilitating success. In an amputee, not having a distal extremity may make this technique less desirable or impossible because of the lack of a definitive endpoint. Having an alternative method for placing a peripheral block such as the one described in this case could be helpful for anesthesia or perioperative pain management.

Our ability to evoke the sensation of movement in a phantom extremity using a stimulus for motor response illustrates a complex process of neural integration beyond simple sensory fiber or motor fiber nerve stimulation. Recent investigations have demonstrated that phantom limb sensations and phantom pain are complex

phenomena that may be attributed to neural reorganization at multiple levels, including the spinal cord, brainstem, thalamus, and cortex, as well as factors in the periphery.<sup>6</sup> The role of the spinal nerves and peripheral nerves have been demonstrated by several investigators who have shown that performing a spinal anesthetic,<sup>1</sup> an epidural,<sup>2</sup> or a brachial plexus block<sup>3,4</sup> can eliminate the sensation of a phantom extremity and temporarily eliminate phantom limb pain, as well as induce phantom sensation and pain.<sup>7</sup> Therefore, it is not unexpected that a sciatic nerve block could produce similar results in the lower extremity.

The exact mechanisms of this complex neural interaction are still unclear. However, this observation suggests that our knowledge about peripheral nerve stimulators for regional anesthesia, although practical, still has many areas that need further investigation. Urmeý and Stanton<sup>8</sup> highlighted part of this void and controversy when they demonstrated that it was possible to consistently elicit a paresthesia without simultaneously evoking a motor response while performing interscalene blocks.

Several factors encouraged us to attempt a nerve stimulator technique in this patient. The patient had severe coexisting disease and preexisting limb pain that we believed would benefit from the anesthetic and postoperative analgesic benefits of peripheral nerve blocks. The patient was also especially cooperative, articulate concerning her perceptions, and enthusiastic about the technique. This enabled us to describe the technique and prompt her for information about her phantom. We believe this aspect of patient education in this circumstance was essential for success.

## References

1. Gentili ME, Bonnet F: Temporary relief from pain in the phantom limb after spinal anesthesia using a combination of bupivacaine and clonidine (in French). *Ann Fr Anesth Reanim* 1993; 12:323-5
2. Uncles DR, Glynn CJ, Carrie LE: Regional anaesthesia for repeat Caesarean section in a patient with phantom limb pain. *Anaesthesia* 1996; 51:69-70
3. Birbaumer N, Lutzenberger W, Montoya P, Larbig W, Unertl K, Topfner S, Grodd W, Taub E, Flor H: Effects of regional anesthesia on phantom limb pain are mirrored in changes in cortical reorganization. *J Neurosci* 1997; 17:5503-8
4. Lierz P, Schroegendorfer K, Choi S, Felleiter P, Kress HG: Continuous blockade of both brachial plexus with ropivacaine in phantom pain: A case report. *Pain* 1998; 78:135-7
5. Labat G: *Regional Anesthesia: Its Technic and Clinical Application*. Philadelphia, Saunders, 1922
6. Chen R, Cohen LG, Hallett M: Nervous system reorganization following injury. *Neuroscience* 2002; 111:761-73
7. Mackenzie N: Phantom limb pain during spinal anaesthesia: Recurrence in amputees. *Anaesthesia* 1983; 38:886-7
8. Urmeý WF, Stanton J: Inability to consistently elicit a motor response following sensory paresthesia during interscalene block administration. *ANESTHESIOLOGY* 2002; 96:552-4

## Dexmedetomidine and Cardiac Arrest

Esperanza Ingersoll-Weng, M.D.,\* Gerard R. Manecke, Jr., M.D.,† Patricia A. Thistlethwaite, M.D., Ph.D.‡

DEXMEDETOMIDINE is an  $\alpha$ -2 receptor agonist often administered to surgical patients because of its sedative, analgesic, and anxiolytic properties. Although severe bradycardia is a known adverse effect, bradycardia leading to asystole in the clinical setting has yet to be reported. We report a case of cardiac arrest in a patient receiving a dexmedetomidine infusion as a supplement to general anesthesia.

### Case Report

A 52-yr-old 60-kg woman with myasthenia gravis presented for thymectomy and excisional biopsy of a right lung mass *via* median sternotomy. A preoperative chest computed tomography revealed an anterior mediastinal mass suggestive of thymoma and two small right lower lobe densities. She was otherwise healthy and exercised vigorously 3 to 4 times per week. Her myasthenia, diagnosed 2 months previously, caused mild symptoms, including occasional diplopia and mild upper extremity weakness. These symptoms resolved only partially with the use of pyridostigmine, 120 mg orally three times daily. The patient's preoperative pulmonary function tests were normal, and her preoperative electrocardiogram exhibited normal sinus rhythm at 60 beats per minute.

On the day of surgery, the patient took her morning pyridostigmine dose. After placement of an IV catheter, she was taken to the operating room, where routine monitors were applied. Initial vital signs were: blood pressure, 130/65; heart rate, 78 beats per minute; and oxygen saturation, 100%. She received midazolam intravenously in 2-mg increments while a thoracic epidural (T6-7) was placed. The epidural, placed solely for postoperative pain relief, was tested with 3 ml lidocaine, 2%, with 150  $\mu$ g epinephrine. This test dose resulted in a small thoracic band of anesthesia with no change in heart rate, blood pressure, or motor function. No further medications were administered *via* the epidural catheter during operative period. At the conclusion of epidural placement, the patient had received a total of 10 mg midazolam and was still fully alert and anxious. Her vital signs at that time were blood pressure, 133/72; heart rate, 75 beats per minute; and oxygen saturation, 100%. After placement of a radial arterial catheter, a loading dose of 1  $\mu$ g/kg dexmedetomidine was given over 10 min, followed by an infusion at 0.2  $\mu$ g/kg/h. The patient initially exhibited a transient increase in blood pressure (145/78), and her heart rate decreased to 48 beats per minute.

General anesthesia was induced with 250  $\mu$ g fentanyl, and 200 mg propofol intravenously. No neuromuscular blockade was used. The patient's vital signs remained stable through induction and laryngoscopy, with heart rate 46-50 beats per minute. Anesthesia was main-

tained with isoflurane, 0.7-0.9%, in 100% oxygen and the dexmedetomidine infusion. The patient remained stable through the start of surgery with blood pressure 100-105/50-55. On sternal retraction, the patient's heart rate dropped into the 30s and 0.5 mg atropine was given. Asystole soon followed, at which time she received open cardiac massage and 300  $\mu$ g IV epinephrine. There was prompt return of the blood pressure and the asystole episode lasted less than 2 min. The dexmedetomidine infusion was discontinued and the remainder of the surgery proceeded uneventfully, with the patient's blood pressure ranging from 100-110 to 50-60, and her heart rate 50-60 beats per minute. She was awakened at the conclusion of surgery and the trachea was extubated. There was no evidence of neurologic compromise. The patient was discharged to home on the fourth postoperative day.

### Discussion

Dexmedetomidine is an  $\alpha$ -2 adrenergic receptor agonist with sedative, analgesic, and anxiolytic properties. It has a selectivity for  $\alpha$ -2 receptors eightfold greater than clonidine, and it is considered a full agonist at the  $\alpha$ -2 adrenergic receptor.<sup>1</sup> Dexmedetomidine has been shown to decrease opioid and inhaled anesthetic requirements, making it an attractive adjunct to general anesthesia.<sup>2,3</sup> When administered to healthy volunteers, dexmedetomidine causes a dose-dependent decrease in blood pressure and heart rate but does not demonstrate clinically relevant respiratory depression, despite its profound sedative effects.<sup>4,5</sup> Its sympatholytic properties, in conjunction with its anesthetic actions, make it an attractive choice for coronary artery surgery<sup>6,7</sup> as well as other major operations.<sup>7-10</sup> Dexmedetomidine has been observed to display a biphasic arterial blood pressure response, causing transient increase in pressure followed by a sustained decrease. The observed heart rate response seems to be a combination of a baroreflex-mediated reduction in heart rate, coinciding with the transient increase in blood pressure, centrally mediated reduced sympathetic tone, and increased vagal tone.<sup>1,4</sup>

Severe bradycardia following administration of  $\alpha$ -2 agonists is well documented.<sup>1,11,12</sup> To our knowledge, however, this is the first reported clinical case of asystole related to the use of dexmedetomidine. A number of factors may have contributed to the development of asystole in this patient. We believe a centrally mediated decrease in sympathetic outflow and increase in parasympathetic outflow resulting from dexmedetomidine, as well as the patient's autonomic response to abrupt surgical stimulation, were the primary contributors. The bradycardic response observed with dexmedetomidine can be augmented by the concurrent use of other medications with negative chronotropic and/or vagal effects. For example, significant bradycardia was observed in a

\* Resident, † Clinical Professor, Department of Anesthesiology, ‡ Assistant Professor, Department of Surgery, Division of Cardiothoracic Surgery.

Received from the University of California-San Diego Medical Center, San Diego, California. Received for publication July 8, 2003. Accepted for publication September 22, 2003. Support was provided solely from institutional and/or departmental sources.

Address reprint requests to Dr. Manecke: Thornton Hospital, Department of Anesthesiology, 9300 Campus Point Drive, La Jolla, CA 92037-7770. Address electronic mail to: gmanecke@ucsd.edu. Individual article reprints may be purchased through the Journal Web site, [www.anesthesiology.org](http://www.anesthesiology.org).



5-week-old infant treated with digoxin during sedation with dexmedetomidine.<sup>13</sup> In our case, the patient was being treated with pyridostigmine, which increases vagal tone. Pyridostigmine, an anticholinesterase used for the symptomatic treatment of myasthenia gravis, increases the concentration of acetylcholine at muscarinic and nicotinic receptors. The activation of cardiac muscarinic receptors accounts for the drug's negative chronotropic effect, which is exacerbated by the concomitant administration of other negative chronotropes such as digitalis, calcium channel blockers, and beta blockers.<sup>14</sup> Pyridostigmine is known to antagonize and may also potentiate neuromuscular blockers; however, it has no reported interactions with other often used anesthetic agents.<sup>15</sup> Although it is unclear whether the pyridostigmine had any significant cardiovascular effects on this patient, it may have interacted with dexmedetomidine in an additive or synergistic fashion.

This patient likely had increased vagal tone at baseline, given her level of physical activity and low resting heart rate. Bloor *et al.*<sup>1</sup> also noted bradydysrhythmia in three patients within minutes of dexmedetomidine infusion, when the plasma concentration of dexmedetomidine is presumably high. Their study involved healthy young men with low resting heart rates. These events were associated with increased blood pressure, and Bloor *et al.* attributed them to reflex-mediated slowing secondary to peripheral hypertensive response. In our patient, the severe bradycardia progressing to asystole coincided temporally with the sternotomy and sternal retraction. This surgical stimulus may have produced a vaso-vagal response, which led to cardiac standstill. Another possibility is that, on sternal retraction, mechanosensory receptors in the heart were stimulated, resulting in the Bezold-Jarisch reflex. This reflex, mediated by vagal efferents and decreased sympathetic vasomotor tone, may cause severe bradycardia and hypotension.<sup>16</sup>

The patient was given a modest dose of fentanyl prior to induction of anesthesia. Dexmedetomidine has been shown to reduce opioid requirements as well as augment the bradycardia that may be observed with their use.<sup>2,17</sup> Another possible, but unlikely, factor in this case is the epidural. As mentioned previously, the epidural was placed to provide only postoperative pain relief, and except for the test dose, no other medications were administered epidurally during surgery. Bradycardia and cardiac arrest are well-documented complications of spinal and epidural anesthesia.<sup>18–22</sup> However, although the small epidural test dose could have caused a modest amount of sympatholysis, an hour had elapsed between the placement and testing of the epidural and the episode of asystole. This argues against sympatholysis from the epidural playing a significant role in this event.

In summary, we report a case of severe bradycardia progressing to asystole in a patient receiving a dexmedetomidine infusion to supplement general anesthesia. The prompt and effective treatment of this event resulted in complete recovery with no evidence of cardiovascular or neurologic compromise. Several factors combined to cause asystole in this patient, and caution must be exercised when administering dexmedetomidine in the presence of other negative chronotropic influences.

## References

1. Bloor BC, Ward DS, Belleville JP, Maze M: Effects of intravenous dexmedetomidine in humans: II. Hemodynamic changes. *ANESTHESIOLOGY* 1992; 77:1134–42
2. Salmenpera MT, Szlam F, Hug CC: Anesthetic and hemodynamic interactions of dexmedetomidine and fentanyl in dogs. *ANESTHESIOLOGY* 1994; 80:837–46
3. Khan ZP, Munday IT, Jones RM, Thornton C, Mant TG, Amin D: Effects of dexmedetomidine on isoflurane requirements in healthy volunteers: Pharmacodynamic and pharmacokinetic interactions. *Br J Anaesth* 1999; 83:372–80
4. Ebert TJ, Hall JE, Barney JA, Uhrich TD, Colino MD: The effects of increasing plasma concentrations of dexmedetomidine in humans. *ANESTHESIOLOGY* 2000; 93:382–94
5. Belleville JP, Ward DS, Bloor BC, Maze M: Effects of intravenous dexmedetomidine in humans: I. Sedation, ventilation, and metabolic rate. *ANESTHESIOLOGY* 1992; 77:1125–33
6. Jaonen J, Hynynen M, Kuitunen A, Heikkilä H, Perttinen J, Salmenpera M, Valtonen M, Aantaa R, Kallio A: Dexmedetomidine as an anesthetic adjunct in coronary artery bypass grafting. *ANESTHESIOLOGY* 1997; 86:331–45
7. Wijesundera DN, Naik JS, Beattie WS: Alpha-2 adrenergic agonists to prevent perioperative cardiovascular complications: A meta-analysis. *Am J Med* 2003; 114:742–52
8. Talke P, Li J, Jain U, Leung J, Drasner K, Hollenberg M, Mangano DT: Effects of perioperative dexmedetomidine infusion in patients undergoing vascular surgery. *ANESTHESIOLOGY* 1995; 82:620–33
9. Aho M, Lehtinen AM, Erkkola O, Kallio A, Korttila K: The effect of intravenously administered dexmedetomidine on perioperative hemodynamics and isoflurane requirements in patients undergoing abdominal hysterectomy. *ANESTHESIOLOGY* 1991; 74:997–1002
10. Aho M, Erkkola O, Kallio A, Scheinin H, Korttila K: Dexmedetomidine infusion for maintenance of anesthesia in patients undergoing abdominal hysterectomy. *Anesth Analg* 1992; 75:940–6
11. Erkkola O, Korttila K, Aho M, Haasio J, Aantaa R, Kallio A: Comparison of intramuscular dexmedetomidine and midazolam premedication for elective abdominal hysterectomy. *Anesth Analg* 1994; 79:646–53
12. Talke P, Chen R, Thomas B, Aggarwall A, Gottlieb A, Thorborg P, Heard S, Cheung A, Son SL, Kallio A: The hemodynamic and adrenergic effects of perioperative dexmedetomidine infusion after vascular surgery. *Anesth Analg* 2000; 90:834–9
13. Berkenbosch JW, Tobias JD: Development of bradycardia during sedation with dexmedetomidine in an infant concurrently receiving digoxin. *Pediatr Crit Care Med* 2003; 4:203–5
14. Arsur EL, Brunner NG, Namba T, Grob D: Adverse Cardiovascular effects of anticholinesterase medications. *Am J Med Sci* 1987; 293:18–23
15. Keeler JR: Interactions between nerve agent pretreatment and drugs commonly used in combat anesthesia. *Mil Med* 1990; 155:527–33
16. Campagna JA, Carter C: Clinical relevance of the Bezold-Jarisch reflex. *ANESTHESIOLOGY* 2003; 98:1250–60
17. Aho MS, Erkkola OA, Scheinin H, Lehtinen AM, Korttila KT: Effect of intravenously administered dexmedetomidine on pain after laparoscopic tubal ligation. *Anesth Analg* 1991; 73:112–8
18. Caplan RA, Ward RJ, Posner K, Cheney FW: Unexpected cardiac arrest during spinal anesthesia: A closed claims analysis of predisposing factors. *ANESTHESIOLOGY* 1988; 68:5–11
19. Gild W, Crilley P: Sudden cardiac arrest during epidural anesthesia (letter). *ANESTHESIOLOGY* 1990; 73:1296
20. Chan KK, Welch KJ: Cardiac arrest during segmental thoracic epidural anesthesia. *ANESTHESIOLOGY* 1997; 86:503–5
21. Palmer SK: What is the incidence of arrest and near arrest during spinal and epidural analgesia? Report of nine years experience in an academic group practice (abstract). *Anesth Analg* 2001; 92:S339
22. Pollard JB: Common mechanisms and strategies for prevention and treatment of cardiac arrest during epidural anesthesia. *J Clin Anesth* 2002; 14:52–6