

Wrist Hyperextension Leads to Median Nerve Conduction Block

Implications for Intra-arterial Catheter Placement

Anne L. Chowet, M.D.,* Jaime R. Lopez, M.D.,† John G. Brock-Utne, M.D., Ph.D.,‡ Richard A. Jaffe, M.D., Ph.D.‡

Background: It is common practice to hyperextend the wrist to facilitate insertion of a radial intra-arterial catheter. This position may be maintained for prolonged periods. Although there has been much discussion about optimal patient management to protect the ulnar nerve and brachial plexus, little attention has been paid to the median nerve during wrist hyperextension. The authors report the effects of wrist hyperextension on conduction in the median nerve.

Methods: Median nerve conduction was studied in 12 awake, healthy volunteers using standard nerve conduction tests consisting of the measurement of compound sensory and motor action potentials, as well as their amplitudes and latencies. With the contralateral hand as a control, the right wrist was placed in hyperextension (angled between 65 and 80 degrees), and compound action potentials were recorded to determine the onset and magnitude of effects. Subsequently, the hand was released from hyperextension and recovery was recorded.

Results: In 83% of subjects, hyperextension resulted in a significant decrease in compound sensory action potential amplitudes, sufficient to qualify as conduction block (16.6% of baseline). The average time to conduction block was 43 ± 13.2 min. All subjects who manifested conduction block showed marked improvement 5 min after release from hyperextension.

Conclusions: Wrist hyperextension for arterial line placement and stabilization is likely to result in profound impairment of median nerve function. Although the effects were transient in this study, the results suggest that prolonged hyperextension may be associated with significant changes in median nerve conduction. To minimize the chance for nerve injury, the authors recommend that wrists be returned promptly to the neutral position following arterial line placement.

It is common practice to hyperextend the wrist during insertion of a radial intra-arterial catheter to facilitate arterial puncture and cannulation.^{1,2} In some cases the wrist is left in this position for the duration of the surgical procedure, or as long as the catheter is in place. Anesthesiologists have a longstanding interest in protecting patients from nerve injury, as evidenced by the extensive literature regarding proper patient positioning and padding.

Known complications associated with radial arterial blood pressure monitoring include bleeding and hematoma formation, vascular insufficiency, thrombosis, arte-

rial dissection, embolization, infection, pseudoaneurysm formation, and arteriovenous fistula formation.^{3,4} These complications are all related to the intra-arterial catheter used to establish access to the arterial system. There have been no investigations into the safety of wrist hyperextension on median nerve function, yet this position is used to stabilize intra-arterial catheters.

The mechanism of position-related median nerve injury remains undefined and may be multifactorial. In cases in which wrist hyperextension is prolonged, it is likely that a stretch-induced focal neuropathy may be involved. Several positions that elongate the nerve bedding of the median nerve have been associated with perioperative neuropathies, such as forearm supination and full elbow extension.⁵⁻⁸

Although attempts have been made to reach a consensus regarding positioning of the upper extremity, no comments have been made on proper positioning at the wrist.⁹ The practice of wrist hyperextension during radial intra-arterial catheter placement and stabilization has never been critically evaluated. Postoperative median nerve injury has, in some cases, been ascribed to direct needle trauma associated with intravenous catheters inserted at the wrist.¹⁰ In this study we evaluate the effect of wrist hyperextension, as used for insertion and stabilization of intra-arterial catheters, on median nerve function.

Materials and Methods

After review and approval by the Human Subjects Committee of Stanford University School of Medicine, Stanford, California, written informed consent was obtained from 12 volunteer research subjects. Subjects were placed supine, with arms at their sides. A thermistor was applied to the center of each palm; after appropriate skin preparation, electrodes were placed bilaterally as shown in figure 1. Standard bipolar surface electrodes were used to stimulate the median nerve. These electrodes were placed on the dorsum of the wrist, over the median nerve, and 6 cm proximal to the belly of the abductor pollicis brevis muscle. The active recording electrode was placed over the belly of the abductor pollicis brevis, whereas the reference electrode was placed over the first metacarpophalangeal joint (fingers are numbered 1-5 starting with the thumb). Recordings were performed using standard surface bar and ring electrodes. The active ring electrode

* Postdoctoral Fellow, ‡ Professor, Department of Anesthesia; ‡ Associate Professor, Department of Neurology and Neurological Sciences; Stanford University School of Medicine.

Received from the Department of Anesthesia, Stanford University School of Medicine, Stanford, California. Submitted for publication May 29, 2003. Accepted for publication August 26, 2003. Support was provided solely from institutional and/or departmental sources.

Address reprint requests to Dr. Jaffe: 300 Pasteur Drive, Stanford, California 94305. Address electronic mail to: rajaffe@stanford.edu. Individual article reprints may be purchased through the Journal Web site, www.anesthesiology.org.

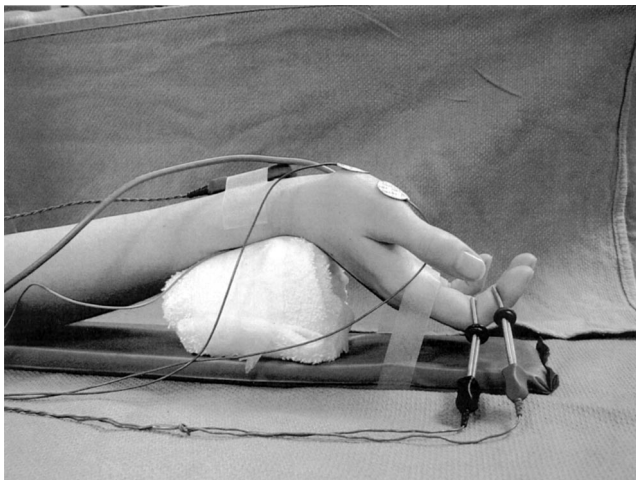


Fig. 1. Profile of right wrist hyperextended to 65 degrees. Sensory electrodes were on the second digit, whereas motor electrodes were on the first digit. The stimulating electrode was on the dorsum of the wrist. This position was maintained until compound sensory action potential amplitudes reached a steady state or until 120 min of testing.

was placed on the second digit in the middle interphalangeal joint crease (11–12 cm from the active stimulating electrode), whereas the reference ring electrode was placed on the second digit in the distal interphalangeal joint crease. A ground electrode was placed on the dorsum of each hand, between the stimulating and recording electrodes. Compound motor action potentials (CMAP) were recorded from the abductor pollicis brevis, and compound sensory action potentials (CSAP) were recorded from the index finger.

Once the subject was prepared, baseline recordings of temperature, CMAP and CSAP were obtained bilaterally. After stable baseline temperatures and compound action potential amplitudes were established, the right wrist was hyperextended by the subject over a cushioned support, to an angle between 65 and 80 degrees, as measured using a joint angle protractor. The hand was secured with tape to an armboard, and wrist hyperextension was maintained until release. Motor and sensory compound action potentials, as well as temperatures, were recorded every 10 min. Recordings continued until CSAP from the hyperextended hand reached a steady state, or until 120 min of testing had been reached. At that point, the wrist was released from the hyperextended position. Compound action potentials and temperatures were recorded at 2, 5, 10, and 20 min after release, or until compound AP amplitudes returned to baseline.

Bilateral CMAP and CSAP waveforms were recorded using a Nicolet Viking Four Electrodiagnostic System (Nicolet Instrument Corporation, Madison, WI). Supramaximal stimuli were delivered at a frequency of 1.1 Hz with a duration of 0.2 ms. Stimulus intensity, determined individually based on achievement of a supramaximal motor response, ranged from 8.8 to 19.2 mA. Once set,

the intensity was not changed for the duration of each subject's study. Each data point was signal-averaged over 10 responses to stimulation.

The following parameters were recorded for both CMAP and CSAP: latency of the first positive deflection (P0), latency of the first negative deflection (N1), latency of the second positive deflection (P1), the peak-to-peak amplitude of P0-N1 and the peak-to-peak amplitude of N1-P1. We used N1-P1 as our measure of amplitude, because it was less likely to be affected by shock artifact, compared to the P0-N1 amplitude.

All results are presented as mean \pm SD. Data were considered significant using repeated measures ANOVA with the Dunnett Multiple Comparisons Test ($P < 0.0001$).

Results

Twelve subjects, mean age 36 yr, volunteered to participate in this study. Eleven subjects were right-hand dominant. In all subjects, hand temperature, an indirect indication of hand perfusion, varied by less than 7% from baseline throughout the study. The mean angle of wrist hyperextension was 72 ± 6 degrees, as measured by a joint angle protractor.

In 10 subjects, CSAP from the hyperextended wrist decreased in amplitude until they were less than 20% of baseline values. This was defined as conduction block for our purposes. This criterion is more stringent than that used in clinical neurology, in which a decrease in amplitude of 50% is considered conduction block. We chose this criterion to exclude the possibility of transient artifactual causes of reduced amplitudes. For all subjects who manifested conduction block, the onset was between 30 and 60 min after positioning, with 83% of subjects manifesting conduction block by 60 min (fig. 2).

CSAP from the hyperextended side decreased dramatically in 10 of the 12 subjects. It is of note that in nine subjects, the changes to sensory action potentials were so profound that conduction block was complete, with no compound action potential reliably discerned from background noise. Two subjects did not exhibit conduction block as a result of hyperextension. In subject 2, CSAP decreased to 68% of baseline, whereas subject 10 had no significant change from baseline. In 11 subjects, CSAP of the nonhyperextended (left) wrist remained constant over the course of the experiment, decreasing by less than 25% from baseline amplitudes. Subject 4 had a decrease in amplitude to 46% of baseline in the control (left) hand. We hypothesize that this was a result of the left arm position. This subject spontaneously kept the left hand supinated and the arm maximally extended at the elbow, positions that are known to stretch the bedding of the median nerve.^{5–8} Furthermore, this subject noted paresthesias in the control hand as well as in the hyperextended side.

Fig. 2. Percentage of subjects who exhibited conduction block during each 10-min interval. By 60 min of testing, 83% of subjects manifested conduction block, defined as compound sensory action potential amplitude less than 20% of baseline values.

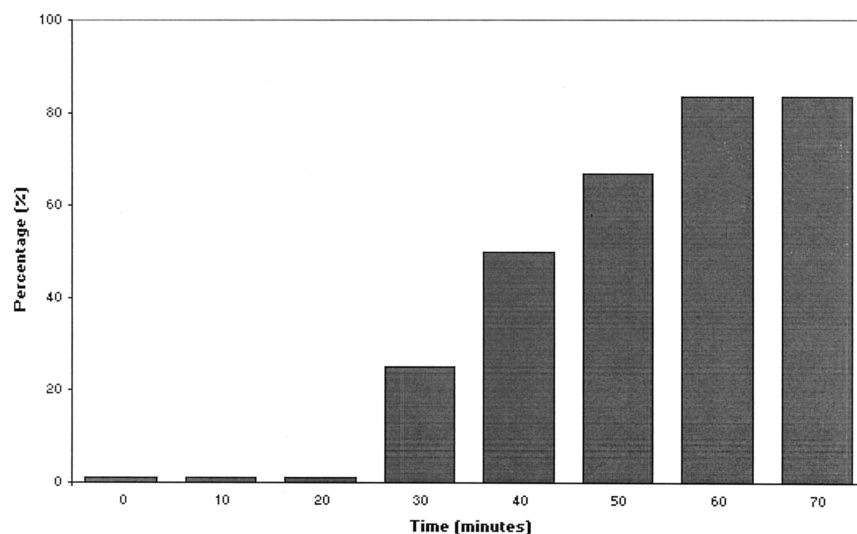


Figure 3 depicts the mean decrement in CSAP amplitude in the hyperextended hand over time. The decrement begins gradually over the first 30 min of study. By 60 min the mean amplitude of all subjects, including those who did not exhibit conduction block, was $17 \pm 10\%$ of baseline. These marked electrical changes were accompanied by severe paresthesias in all subjects. The mean time to reported onset of paresthesias was 26 ± 10 min.

All subjects reported marked relief from paresthesias within 1 min of release from hyperextension. Following release, there was rapid recovery of CSAP amplitudes such that 60% of subjects had recovered to at least 80% of baseline by 5 min after release. By 30 min after release all subjects had recovered.

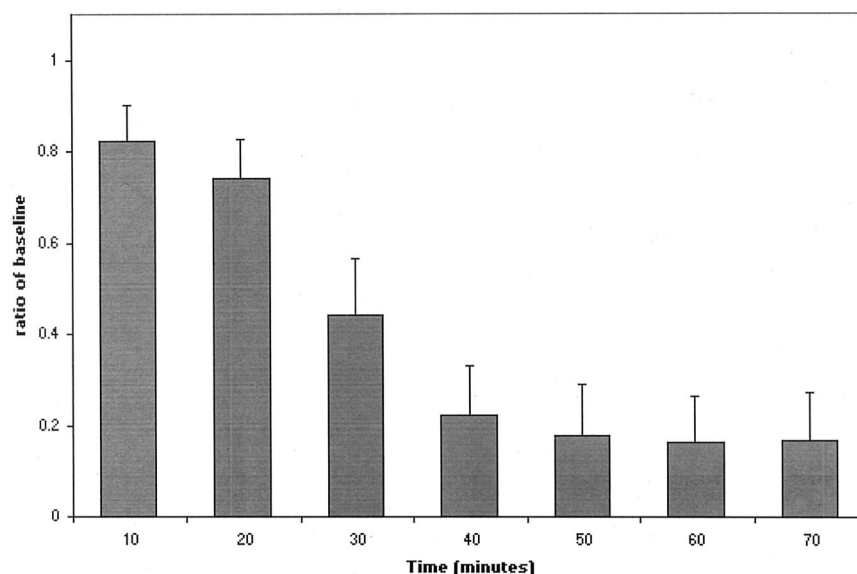
Although changes in CMAP were less dramatic, they are nonetheless noteworthy, with a trend toward decreased motor amplitudes with hyperextension. Two of the 12 subjects had profound changes in the hyperextended hand. Subject 9 exhibited complete motor block,

and no motor response could be elicited during stimulation. Subject 11 had CMAP decrease to 23% of baseline, with signals from the control hand remaining unchanged. In all subjects, motor responses recovered quickly on release of hyperextension.

Discussion

In this study, compound sensory and motor action potentials were analyzed to quantify the impact on the median nerve of wrist hyperextension to angles between 65 and 80 degrees. Our results revealed that 83% of subjects developed sensory conduction block. The mean time to conduction block was 43 min. All subjects displaying conduction block developed clinical symptoms of median nerve dysfunction characterized by severe paresthesias after 26 ± 10 min of hyperextension. These symptoms resolved by 30 min after release from hyperextension in all subjects.

Fig. 3. Mean decrement in compound sensory action potential amplitude in the hyperextended hand with increasing duration of hyperextension.



The causes of peripheral neuropathies may include nerve stretch, ischemia, compression, or laceration of a nerve. Although we cannot be certain as to the mechanism of the changes we observed in our study, it is reasonable to conclude that hyperextension may be responsible for some cases of postoperative median nerve neuropathy. We propose that wrist hyperextension results in median nerve compression through the carpal tunnel, where the median nerve is located just beneath the volar carpal ligament. This anatomically tight space is further narrowed by hyperextension, which draws the volar carpal ligament more tightly over the carpal tunnel and median nerve.^{11,12} It is likely that this compression interferes with the local blood supply to the median nerve. Because signal conduction is dependent on local energy supply, inhibition of the microcirculation may block transmission of impulses in this otherwise intact nerve. Both sensory and motor conduction across compressed nerve segments may be blocked by focal ischemia.¹³⁻¹⁵ In our study, the effects on sensory nerve fibers were far more pronounced than those on motor fibers. We hypothesize that this may be size-related, with the smaller sensory fibers being more susceptible to ischemia, compared to the larger motor fibers. The fact that the hyperextended hand did not become cold, as would be expected if perfusion were reduced, suggests that macroscopic ischemia did not play a significant role in causing conduction block. Given the immediate reversibility and relatively short duration of the conduction block, axonal or myelin damage are less likely as the underlying mechanism, because these injuries would take days or weeks to resolve.¹⁵

Lundborg *et al.* demonstrated that with a longer duration of nerve ischemia, the time required for functional recovery was extended. Importantly, 6 to 8 h was defined as the critical ischemic time limit before nerve fibers were irreversibly damaged.^{13,14} Translating to clinical practice, this critical threshold is important because patients may be left with their wrist hyperextended for many hours, or even days. Our findings suggest that this practice may expose patients to the unnecessary risk of nerve damage.

The absence of conduction block in two subjects highlights the variability among individuals with respect to susceptibility to nerve dysfunction. This variability likely results from minor variations in the anatomy of the carpal tunnel. Because it is not possible to predict which individuals are more likely to sustain nerve dysfunction with wrist hyperextension, it is safest to avoid prolonged wrist hyperextension in all patients whenever possible.

Several limitations are evident in our investigation. The technician who recorded all action potential data was not blinded to the subjects' wrist positions. However, she was the single observer who consistently recorded all data. Moreover, the angle to which the subjects' wrists were hyperextended may be more than the angles

used in clinical practice, which might have affected the interpretation of our results. However, it is of note that we found no relationship between the extent of nerve dysfunction and the angle of extension. The subject whose wrist was positioned at 80 degrees is one of the two who did not exhibit nerve dysfunction. Our conclusion that prolonged wrist hyperextension may potentially lead to permanent nerve dysfunction is an extrapolation of our data, based on median nerve compression of short duration combined with the findings of Lundborg in 1975.¹⁴ Obviously, it would not be reasonable or ethical to repeat this study with prolonged hyperextension, given the possibility of inducing permanent nerve injury in volunteers. Although the closed claims analysis reveals that postoperative median neuropathy occurs, no clinical data are available with regard to the relationship between such neuropathies and wrist hyperextension associated with intra-articular catheters. Finally, because postoperative median neuropathy is not frequently reported and may be uncommon, designing a prospective, randomized, controlled trial may be impractical.

Postoperative neuropathies are responsible for 16% of all lawsuits evaluated in the closed claims analysis.¹⁰ Median nerve injury accounts for 4% of these neuropathies, but it is possible that this is an underestimate of the actual incidence of postoperative injuries. The true incidence may be obscured by the many cases in which median nerve dysfunction is transient. Also, while sedated or recovering from surgery, patients might not notice the symptoms of median nerve dysfunction. Finally, postoperative median nerve damage may be masked by a delayed diagnosis of carpal tunnel syndrome, which patients do not relate to their surgery. In this study, our subjects were healthy young adults with no known risk factors for neuropathy, and they displayed nerve dysfunction in response to brief hyperextension. In clinical practice, patients often have multiple factors that place them at increased risk for nerve injury, including diabetes mellitus, metabolic derangements, preexisting neuropathy (including carpal tunnel syndrome), obesity, neurologic illness, rheumatologic disease, and previous wrist fracture.¹⁶ These diagnoses may place patients at even greater risk for developing perioperative nerve dysfunction. Furthermore, anesthetized or sedated patients are at greater risk of nerve damage because they are unable to perceive or complain of paresthesias that would normally disturb the awake patient. Our findings suggest that the wrists should be promptly returned to the neutral position following arterial catheter placement, to minimize the possibility of nerve injury.

The authors thank Sherry Padgett, R. EEG T., Department of Neurology, Stanford University School of Medicine, Stanford, California, for her assistance in this study.

References

1. Fowler GC: Arterial puncture, *Procedures for Primary Care Physicians*, 1st edition. Edited by Pfenninger JL, Fowler GC, St. Louis, Mosby, 1994, pp 340-7
2. Fowler GC: Percutaneous arterial line placement, *Procedures for Primary Care Physicians*, 1st edition. Edited by Pfenninger JL, Fowler GC, St. Louis, Mosby, 1994, pp 293-9
3. Bowdle TA: Complications of invasive monitoring. *Anesthesiol Clin North America* 2002; 20:571-88
4. Coulter TD, Wiedemann HP: Complications of hemodynamic monitoring. *Clin Chest Med* 1999; 20:249-67, vii
5. Bain AC, Raghupathi R, Meaney DF: Dynamic stretch correlates to both morphological abnormalities and electrophysiological impairment in a model of traumatic axonal injury. *J Neurotrauma* 2001; 18:499-511
6. Coppieters MW, Van de Velde M, Stappaerts KH: Positioning in anesthesiology: Toward a better understanding of stretch-induced perioperative neuropathies. *ANESTHESIOLOGY* 2002; 97:75-81
7. Fowler SS, Leonetti JP, Banich JC, Lee JM, Wurster R, Young MR: Duration of neuronal stretch correlates with functional loss. *Otolaryngol Head Neck Surg* 2001; 124:641-4
8. Jou IM, Lai KA, Shen CL, Yamano Y: Changes in conduction, blood flow, histology, and neurological status following acute nerve-stretch injury induced by femoral lengthening. *J Orthop Res* 2000; 18:149-55
9. American Society of Anesthesiologists Task Force on Prevention of Perioperative Peripheral Neuropathies: Practice advisory for the prevention of perioperative peripheral neuropathies. *ANESTHESIOLOGY* 2000; 92:1168-82
10. Cheney FW, Domino KB, Caplan RA, Posner KL: Nerve injury associated with anesthesia: A closed claims analysis. *ANESTHESIOLOGY* 1999; 90:1062-9
11. Rotman MB, Donovan JP: Practical anatomy of the carpal tunnel. *Hand Clin* 2002; 18:219-30
12. Werner RA, Andary M: Carpal tunnel syndrome: Pathophysiology and clinical neurophysiology. *Clin Neurophysiol* 2002; 113:1373-81
13. Lundborg G: Ischemic nerve injury: Experimental studies on intraneural microvascular pathophysiology and nerve function in a limb subjected to temporary circulatory arrest. *Scand J Plast Reconstr Surg Suppl* 1970; 6:3-113
14. Lundborg G: Structure and function of the intraneural microvessels as related to trauma, edema formation, and nerve function. *J Bone Joint Surg [Am]* 1975; 57:938-48
15. Lundborg G, Dahlin LB: The pathophysiology of nerve compression. *Hand Clin* 1992; 8:215-27
16. Prielipp RC, Morell RC, Walker FO, Santos CC, Bennett J, Butterworth J: Ulnar nerve pressure: Influence of arm position and relationship to somatosensory evoked potentials. *ANESTHESIOLOGY* 1999; 91:345-54